

Case Report

Leiomyomatosis Peritonei Disseminata Following Total Abdominal Hysterectomy: A Case Report and Literature Review

Natalia A^{1*}, Usman AU¹, Zainab DA¹ and Ali BU²

¹Obstetrics and Gynaecology Department, Bayero University/Aminu Kano Teaching Hospital, Kano, Nigeria

²Pathology Department, Bayero University/Aminu Kano Teaching Hospital, Kano, Nigeria

*Corresponding author: Natalia A, Obstetrics and Gynaecology Department Bayero University/Aminu Kano Teaching Hospital, Kano, Zaria road P.M.B.3452, Nigeria

Received: March 01, 2016; Accepted: May 09, 2016;

Published: May 11, 2016

Abstract

Uterine leiomyoma is a benign neoplasm that arises from uterine smooth muscles and the most common tumour of the reproductive tract. Very rare leiomyomas present with unusual behavior. Disseminated peritoneal leiomyomatosis presents as multiple small nodules on the peritoneum. We present a case of Mrs. K who was a 60 years old grand multipara, ten years postmenopausal. She had total abdominal hysterectomy for multiple uterine fibroids a year earlier. Abdomino-pelvic scan and CT scan revealed a large multi lobulated heterogeneous lesion in the pelvis. The lesion measured approximately 13.5x11.5cm in size. The tumour was resected. On immunohistochemistry tumour cells were positive for alpha-smooth muscle actin, which is characteristic for smooth muscle tumour. A nuclear staining for progesterone receptor was positive, but negative for oestrogen receptors. Due to rarity of condition different modalities in the management are proposed. In view of possible recurrence and malignant transformation patients need clinical and radiological follow up? Leiomyomatosis peritonei disseminate is a rare condition. Hormonal treatment may be effective in recurrent cases especially in hormone receptor positive tumor or when temporary relief of symptoms is necessary.

Keywords: Leiomyoma; Leiomyomatosis Peritonei Disseminate; Total Abdominal Hysterectomy; Nigeria

Introduction

Uterine leiomyoma is a benign neoplasm that arises from uterine smooth muscle. It is the most common tumour of the reproductive tract in the women of reproductive age, occurring in 20-25% of women over 30 years of age, especially the nulliparous ones. The lifetime risk of fibroids in nulliparous women over the age of 45 years is more than 60% [1]. The incidence of these tumours is several times higher in black women than in white women [2]. Studies indicate that leiomyomas are monoclonal, originated from somatic mutations in myometrial cells, resulting in progressive loss of growth regulation. The key regulators of fibroid growth are ovarian steroids (oestrogen, progesterone) and growth factors [3]. The environment within the leiomyomas is hyperestrogenic. Estrogen may induce the proliferation of leiomyoma cells in part by activating Adenosine Triphosphate (ATP) channel. Progesterone upregulate the level of antiapoptotic protein Bcl-2, which influences cell proliferation [2,3]. The effects of oestrogens and progestins on leiomyomas are mediated by growth factors. Epidermal growth factor, Insuline like growth factor I and II are over expressed in myomas [2,3]. Fibroblast growth factor and vascular endothelial growth factor are also over expressed in myomas, leading to an abnormal vasculature, characterized by a dilated venous plexuses [2]. Oncogene and tumour suppressor genes may also have a role in fibroid development (p-53, p-16) [2,3]. The most frequent cytogenetic changes are translocation and deletion of chromosome 7, which are found in up to 58% of fibroid specimen [2]. Heredity, nulliparity, obesity, polycystic ovary syndrome, diabetes and hypertension are associated with increased risk of fibroid [3].

Reported recurrence rates after myomectomy was up to 50% at five years [3]. Very rare leiomyomas present with unusual behavior. These include parasitic leiomyomas, retroperitoneal leiomyomas, and benign metastasizing leiomyoma and disseminated peritoneal leiomyomatosis [2,4,5]. Disseminated peritoneal leiomyomatosis presents as multiple small nodules on the peritoneum that composed of whorled bundles of smooth muscle cells [4]. It is considered as benign condition and occurs in women predominantly of reproductive age [5]. A few cases were reported in postmenopausal women and even in men [6]. The aetiology and pathogenesis of disseminated peritoneal leiomyomatosis is still controversial. Progesterone receptors, oestrogen receptor and luteinizing hormone receptor expression were detected in cells of disseminated peritoneal leiomyomatosis [6,7]. We present a case of disseminated peritoneal leiomyomatosis in a postmenopausal woman following total abdominal hysterectomy for multiple uterine fibroids a year earlier.

Case Report

Mrs. K was a 60 year old P₁₂₊₀A₁₁, ten years postmenopausal Nigerian lady (Hausa) who's last child birth was 16 years prior to presentation. She presented to the gynaecological clinic on 22/04/2015 with complaints of heaviness and progressive swelling in her lower abdomen about six months duration following total abdominal hysterectomy for multiple uterine fibroids a year earlier. There was no associated weight loss, pressure symptoms, pains, dysuria, bleeding per vaginam, nausea and vomiting or diarrhea. She had total abdominal hysterectomy and bilateral salpingo-oophorectomy in March 2014 on account of multiple uterine fibroids. The size

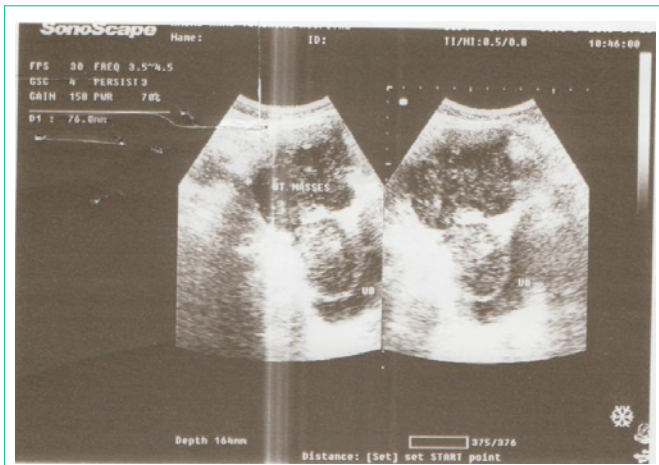


Figure 1: Pelvic ultrasound scan showing pelvic multi nodular mass.

of the tumour was up to 22 week of gestation with histopathology conformation of leiomyoma. She had never practiced contraception. There was no history of hormone replacement therapy. She had cervical cancer screening prior to the hysterectomy and it was negative. She is a known diabetic and hypertensive patient for the past five years and was on Metformin/ Glibenclomide; Amlodipine and Lisinopril respectively.

Clinical examination revealed an elderly woman, who was not pale and had no peripheral lymphadenopathy. There was no pedal oedema. She had no thyroid gland enlargement. Her BMI was 35.4kg/m². Her pulse rate was 84 beats per minutes and blood pressure was 130/80 mm Hg.

On abdominal examination a firm, multi nodular, non tender and fixed suprapubic mass about 20 weeks gestation size was felt. The liver, spleen and kidneys were not enlarged. There was no ascites. Pelvic examination revealed atrophic vulva and vagina. No cervix was palpable. The mass approximately of 20 weeks of gestation was felt. It was fixed and multi nodular.

A diagnosis of recurrent pelvic mass was made; she was evaluated and had basic investigations which were within normal limits. Her Fasting blood sugar was 5.2mmol/l. Ca 125 was 7u/ml, oestrogen level was 0.598pg/ml and progesterone level was 23.5ng/l. Preoperative electrocardiogram and chest radiograph revealed no abnormality.

Abdomino-pelvic scan revealed a mass containing mixed echoes of varying sizes with largest measuring 3.6x5.1 cm and no ascites (Figure 1).

Abdomino-pelvic CT scan revealed a large multi lobulated heterogeneous mass in the pelvis. The lesion measured approximately 13.5x11.5cm in size. No areas of degeneration are seen within the mass. The bladder and liver were within normal limits (Figure 2).

Mrs. K was counseled on exploratory laparotomy and tumour debulking. She was operated on 29/05/2015. The findings were: no ascites, moderate abdomino-pelvic adhesions involving omentum, intestine, bladder and pelvic mass (Figure 3). The mass was arising from posterior abdominal wall and vaginal cuff. It was multinodular and approximately 13x9 cm. No infiltration of surrounding tissue or deposits on the organs, or lymphadenopathy was found. The

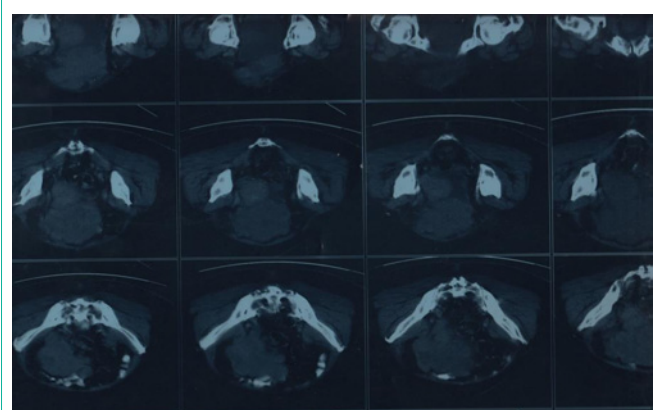


Figure 2: Abdominal CT scan showing a large multi lobulated heterogeneous mass lesion in the pelvis.

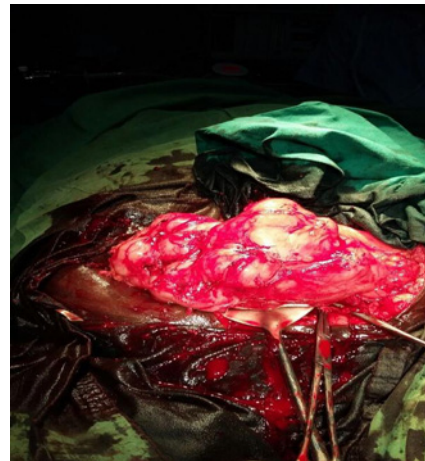


Figure 3: Showing intra operative view of the pelvic mass.

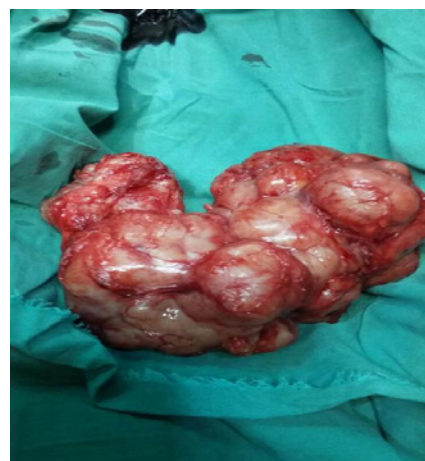

Figure 4: Showing a pelvic mass after enucleation.

mass was enucleated completely (Figure 4). The blood loss was approximately 1000ml. Haemostasis was ensured. She had one pint of blood transfused intraoperatively. The recovery was uncomplicated. Her postoperative Packed Cell Volume (PCV) was 32%. She was discharged on 7th postoperative day.

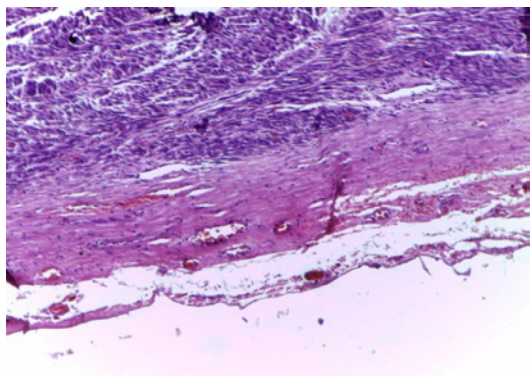


Figure 5: Encapsulated tumour composed of interlacing fascicles of smooth muscle cells. Note the cellularity of the tumour. No mitosis and no necrosis. (Magnification: X400).

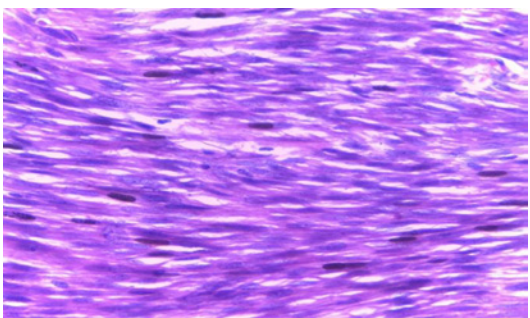


Figure 6: Smooth muscle cells with bland blunt ended nuclei. Note the cellularity. No mitosis. (X400).

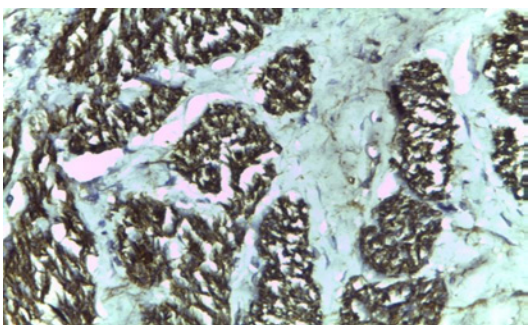


Figure 7: Immunohistochemical stain with Smooth Muscle Actin (SMA) shows strong positivity. (X100).

Histology report revealed a well circumscribed lobulated grayish white mass measuring 15x10x12 cm and weighing 500g. Transection showed grayish white whorled solid surfaces.

Microscopical section of nodular mass showed a tumour surrounded by a fibrous capsule. It was composed of fascicles of benign smooth muscle cells disposed in interlacing pattern (Figure 5). The tumour was cellular but no mitosis or necrosis observed (Figure 6). On Immunohistochemistry tumour cells were positive for alpha-smooth muscle actin, which is characteristic for smooth muscle tumour (Figure 7). A nuclear staining for progesterone receptor was positive (Figure 8), but negative for oestrogen receptors. Conclusion: leiomyoma (cellular variant).

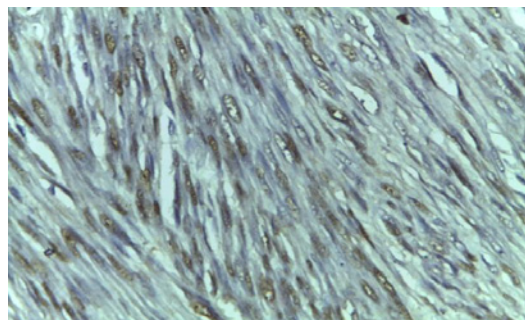


Figure 8: Immunohistochemistry for progesterone receptors shows positive nuclear stain but ER is negative. (X400).

She has been followed up and 3 months later found to have multiple varying sizes masses in the abdomen, which confirmed by abdomino-pelvic scan and CT scan with the largest measured 6.4x4.1 cm in its size. The diagnosis of Leiomyomatosis peritonei disseminate was made. She was counseled on her condition and was placed on aromatase inhibitor (Anastrozole 1mg daily) to control tumour growth. Within one month of treatment the tumour has reduced by 50% from its size and two months later was not palpable per abdomen. She was treated for six months, but due to the cost of treatment the drug was discontinued and within the next six months of follow up the tumor was progressively increasing in size leading to discomfort and abdominal pains. She had exploration on 6/5/2016 and findings of multiple intraabdominal nodular masses of varying sizes involving jejunum were noted (Figure 9). There was no ascites. The liver and spleen were not affected. She had tumor enucleation, intestinal resection (25cm of small intestine) and anastomosis. Total weight of the specimen was 2,490g and the largest nodule measured 18cm. Section from the nodules showed benign smooth muscle cells and that of the intestinal tissue was unremarkable. The immunohistochemical stain with CD117 was negative which ruled out gastrointestinal stromal tumors. The diagnosis of Leiomyomatosis peritonei disseminate was confirmed.

Discussion

Leiomyomatosis peritonei disseminata is a rare benign condition

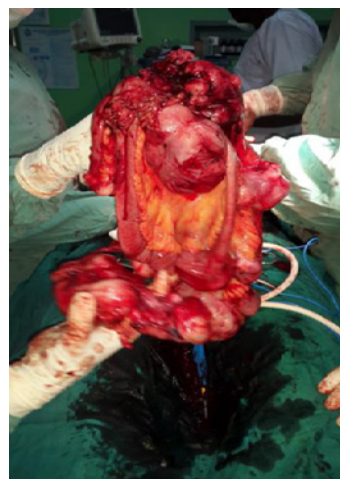

Figure 9: View of the recurrent tumor at 3rd laparotomy.

that clinically mimics carcinogenesis. It was first reported in 1952 by Wilson and Pale [5] and often found incidentally during laparoscopic examination, surgical explorations or at caesarean section [7]. Leiomyomatosis peritonei disseminata has been reported more frequently in Caucasians and blacks [7]. Though the incidence of Leiomyomatosis peritonei disseminate has not been reported due to rarity of the condition. Spontaneous regression has been reported. Presences of oestrogen or progesterone receptors within the cells of the lesion were reported and support hormonal background of this disorder [6]. Metaplasia of the coelomic epithelium has been proposed to explain development of the condition and demonstrated by experimental studies. Exogenous or endogenous hormonal stimulation of the pluripotent submesothelial mesenchymal cells lead to differentiation into myofibroblasts and myocytes [6,7]. The disease does regress after the removal of the hormonal stimulation. The diagnosis is difficult, as radiological findings may suggest the presence of malignant condition, and still confirmed by histopathological evaluation. Due to rarity of condition different modalities in the management are proposed. It includes surgical interventions such as total abdominal hysterectomy, myomectomy, debulking of the nodules or hormone therapy using gonadotropin-releasing analogs or aromatase inhibitors to control tumour growth. This condition occurs in women of reproductive age predominantly but our patient was a postmenopausal woman who had total abdominal hysterectomy and bilateral oophorectomy a year prior to her presentation. She was hypertensive, diabetic and obese, which can contribute to the pathogenesis of this condition as a result of possible hormonal stimulation through their nuclear receptors. In our case, a nuclear staining for progesterone receptor was positive. The cells expressed smooth muscle actin, which is characteristic for smooth muscle tumour. Histological section showed tumour surrounded by a fibrous capsule with increased cellularity but with no cytological atypia or necrosis, though malignant transformation is possible. It is a morphological variant of leiomyoma, and accounts for 5% of leiomyomas [8]. It may present with distant metastases in the lungs, ribs and vertebra, and should be differentiated from leiomyosarcoma and endometrial stromal neoplasms [8]. Cellular leiomyomas has been found to be accompanied by deletion of 1p chromosome which is also found in leiomyosarcomas. Radiological evaluation (abdomino-pelvic scan and CT scan) was not able to exclude the possibility of carcinogenesis, hence specimen was required for definitive diagnosis and treatment and especially in our symptomatic patient. However,

cytogenic evaluation was not done due to unavailability of this test in our centre. Our patient was placed on aromatase inhibitor for period of six months. The preference of this management was dictated by the research available on the similar condition, availability of drugs and relative affordability. In view of possible recurrence and malignant transformation patient need clinical and radiological monitoring, as was done in this case. Our experience in management of this case is that the treatment with Anastrozole has temporal effect on tumor growth with tumor recurrence following discontinuation of the six months treatment.

Conclusion

Leiomyomatosis peritonei disseminate is a rare condition with possible recurrence and malignant transformation. Hormonal treatment may be effective in recurrent cases especially in hormone receptor positive tumor or when temporary relief of symptoms is necessary.

References

1. Selo-Ojeme D, Lawal O, Shah J, Mandal R, Pathak S, Selo-Ojeme U, et al. The incidence of uterine leiomyomas and the pelvic ultrasonographic findings in 2034 consecutive women in the north London hospital. *J Obstet Gynaecol.* 2008; 28: 421-423.
2. David L, Vollenhoven HB, Gareth W. Uterine fibroids. In: Shaw R W editor. *Gynaecology.* 3rd edition. London (UK): Elsevier Science Limited. 2003; 477-491.
3. Reproductive physiology, leiomyomas. In: *Clinical gynaecologic Endocrinology and infertility.* 7th edition. Speroff L (editor). New York (NY): Lippincott Williams Wilkins. 2005; 136-140.
4. The female genital tract. In: Robbins and Cotran Pathologic basic of disease. 7th ed. Kumar V, Abdul K, Nelson F (editors). Philadelphia: Elsevier Inc. 2005; 1059-1117.
5. Marwah N, Duhan A, Aggarwal G, Sen R. An unusual presentation of pelvic leiomyomatosis misdiagnosed as disseminated malignancy. *Case Rep Pathol.* 2012; 394106.
6. Yuri T, Kinoshita Y, Yuki M, Yoshizawa K, Emoto Y, Tsubura A. Leiomyomatosis peritonealis disseminata positive for progesterone receptor. *Am J Case Rep.* 2015; 16: 300-304.
7. Atilio BG, Afzal M, Tarek ES, Aladin A, Obaid AH, Rashad H. Leiomyomatosis peritonealis disseminate. *Annals of Saudi Medicine.* 2000; 20: 440-442.
8. Dim CC, Akogu SP, Ezegwui HU, Olusina DB. Leiomyomatosis peritonealis disseminata in a Nigerian woman. *Niger Med J.* 2012; 53: 172-174.