

## Review Article

# A Brief Review of Endemic Fluorosis in Dromedary Camels (*Camelus Dromedarius*) and Focus on Their Fluoride Susceptibility

Choubisa SL\*

Department of Advanced Science and Technology, National Institute of Medical Science and Research, NIMS University Rajasthan, India

\*Corresponding author: Shanti Lal Choubisa

Department of Advanced Science and Technology, National Institute of Medical Science and Research, NIMS University Rajasthan, Jaipur, & Former Post Graduate Department of Zoology, Government Meera Girls College, Udaipur, Rajasthan 313002, India

Received: January 02, 2023; Accepted: February 10, 2023;

Published: February 17, 2023

## Abstract

Chronic fluoride poisoning in the form of fluorosis in diverse species of domestic animals, viz. cattle (*Bos taurus*), water buffaloes (*Bubalus bubalis*), sheep (*Ovis aries*), goats (*Capra hircus*), horses (*Equus caballus*), donkeys (*Equus asinus*), and dromedary camels (*Camelus dromedarius*) is the resultant of prolonged consumption or exposure of high fluoride through drinking water, food, and air. In general, fluorosis can be recognised by the presence of dental mottling (dental fluorosis) and bone deformities (skeletal fluorosis). In animals, skeletal fluorosis often results in reduced mobility as a result of bone damages or changes due to exostosis, osteosclerosis, osteoporosis, and osteophytosis. In addition, fluoride-induced non-skeletal disorders like gastro-intestinal disturbances, neurological disorders, reproductive dysfunctions, apoptosis, excitotoxicity, genotoxicosis, and teratogenic effects have also been observed in fluorosed domestic and experimental animals. The maximum prevalence, 19.4% and 17.9% of dental and skeletal fluorosis at >3.0 ppm fluoride concentration in drinking water has been observed in domesticated dromedary camels in India, respectively. The prevalence and severity of fluorosis varies from one fluoride endemic region to another and depends on a number of determinants or factors. However, the major determinants are fluoride concentration and its frequency and duration of exposure, rate and density of bio-accumulation of fluoride, and food nutrients. Among different species of domestic animals, camels are found to be less susceptible to fluoride or have a relatively higher fluoride tolerance. In present communication, fluorosis in camels, determinants of fluoride toxicity, and fluoride susceptibility in camels are briefly and critically reviewed. Simultaneously, research gaps have also been highlighted for further research work on chronic fluoride intoxication in diverse species of animals. This review is significant for researchers in understanding of chronic fluoride toxicity in grazers (cattle and buffalo) and browsers (equines, flocks, and camels).

**Keywords:** Chronic fluoride toxicosis; Determinants; Dromedary camels (*Camelus dromedarius*); Fluoride; Fluorosis; Susceptibility

## Introduction

It is well established, chronic exposure to high concentration of fluoride through drinking water, food, and air results in mild to severe fluoride poisoning in the form of dreaded fluorosis disease not only in humans [1-11] but also in diverse species

of domestic animals included cattle (*Bos taurus*), water buffaloes (*Bubalus bubalis*), sheep (*Ovis aries*), goats (*Capra hircus*), horses (*Equus caballus*), donkeys (*Equus asinus*), and dromedary camels (*Camelus dromedarius*) [12-32]. Fluoride poisoning (fluorosis) in animals due to drinking of water having fluoride >

1.0 or 1.5 ppm is, generally, known to as hydrofluorosis, which is more prevalent and endemic in several countries [1]. Both hydrofluorosis and industrial fluorosis (caused by chronic exposure to industrial fluoride pollution) have been extensively studied in bovine (cattle and water buffaloes), equine (horses and donkeys) and flock (sheep and goats) animals throughout the world where there is endemic of fluoridated drinking water. However, studies on chronic fluoride toxicity (fluorosis) in dromedary camels are still very limited and reported only from a few countries [33-39].

Among different species of domestic animals, desert dromedary camels are unique animals and have different morphology, anatomy, and physiology. These dromedaries are well adapted to survive in extreme desert environment or ecosystem with extremely low and high temperatures and low annual rainfall. In fact, it is a wonderful animal of the desert, which has all the qualities that keep it alive in the desert, even without drinking water; it can survive for many days. Their estimated population size in the world is around 20 million which is lower than other domestic ruminants. Therefore, this may also be a reason why studies on fluorosis in dromedaries have not been done extensively. However, few scientific studies on chronic industrial fluoride poisoning (industrial fluorosis) have been well conducted in dromedary camels of Egypt [33,34]. Industrial fluorosis has also been studied in 86 dromedaries living in the industrial areas of Sahara of Morocco but not single dromedary camel was found to be afflicted with chronic industrial fluoride intoxication [35]. Later on hydrofluorosis in camels was first identified and reported from India by Choubisa in 2010 due to drinking of fluoridated water [36]. Subsequently, this form of fluorosis has also been reported in camels living in different geographical provinces of state of Rajasthan (India) where drinking groundwater sources have high level of fluoride [37-39].

### Fluorosis in Dromedary Camels

Successive and prolonged exposure of high fluoride in dromedary camels leads to the development of mild to severe fluorosis disease. In fact, more than 50% absorbed fluoride is excreted in the form of stool, urine, and perspiration, while rest is retained in the body where it accumulates gradually in diverse organs of humans and animals. However, its highest accumulation in the body occurs in those organs, where the amount of calcium is found to be relatively high, such as in teeth and bones [40,41]. That is why the symptoms of fluorosis start emerging in these organs at the earliest. Nevertheless, the bio-accumulation of fluoride is also found in various soft tissues or organs of the body and develops various ill effects. Based on occurring of fluoride-induced changes in hard and soft organs, fluorosis has been categorised into three forms, namely dental fluorosis, skeletal fluorosis, and non-skeletal fluorosis. All three forms may occur in the same individual or animal suffering from chronic fluoride intoxication.

Dental fluorosis is a pathologic condition characterised by hypomineralization of the enamel due to excessive exposure to fluoride during enamel mineralization. In fact, dental fluorosis is first visible, irreversible, and diagnostic or clinical sign of chronic fluoride poisoning in man and animals [40,41]. Fluoride poisoning may occur regardless of the source of fluoride, but the appearance of dental fluorosis is nearly identical in humans and animals. In dental fluorosis teeth become mottled characterised with light to deep brownish or yellowish staining on the enamel surface of the teeth. In severe dental fluorosis, irregular wearing of teeth is also found. This staining is gener-

ally appeared bilaterally, homogenously, and horizontally striated form and rarely in the form of fine spots/dots in the almost all kind of domestic animals [40,41]. But in desert camels, this staining is appeared vertically and non-striated form (Figures 1 and 2). Due to limited studies in these animals, it is difficult to say that vertical and non-striated staining is found only in these animals. For its confirmation, more survey studied on chronic fluoride intoxication in camels is highly suggestive. Due to industrial fluoride exposure, 55 (48.24%) camels out of 114 were found to be afflicted with dental fluorosis in Egypt [35]. At 1.4-3.3 ppm fluoride concentration in drinking waters, the highest incidence, 44.4% of dental fluorosis has also been reported in camels from India [36].

Skeletal fluorosis has been reported in most of the mature or old age camels due to excessive ingestion of high amount of fluoride for long-time (Figures 3 and 4). In the skeletal fluorosis, the mobility of individual is greatly affected and reduced as a result of bone damage due to exostosis, osteosclerosis, osteoporosis, and osteophytosis [42-44]. Symptoms of skeletal fluorosis in camels are similar to those found in other domestic animals, bovines and flocks. No special or different types of skeletal fluorosis symptoms have been found or reported in these camels. However, the periosteal exostoses, intermittent lameness, and hardening of tendons in the legs are as main pathognomonic signs of skeletal fluorosis [41]. Among the mature camels, the maximum prevalence of skeletal fluorosis, 48.24% and 20.0% has been reported due to chronic fluoride exposure through industrial fluoride emissions and fluoridated drinking water, respectively [33,36]. These fluorosed camels are generally found to be weak bodied, lazy, and reluctant to stand.

In the fluorosed camels, other signs of chronic fluoride intoxication as colic, intermittent diarrhoea, excessive urination, irregular reproductive cycles, repeated abortions, sterility, and still birth have also been reported [33-39]. These fluoride-induced health complaints are collectively known as non-skeletal fluorosis and these are reversible and also found in other ruminants living together with these camels [36-39].

### Determinants

The magnitude of fluorosis in man and animals living in different geographical provinces having almost similar F concentration in their drinking water sources is greatly varied. Even in the different species of animals living in the same areas, the prevalence and severity of osteo-dental fluorosis are also varied in them. Among the animals of herd living in same area or location, the severity of fluoride toxicosis is also variable in them. This indicates that some determinants or factors have potential role in acceleration of the fluoride toxicity. The most important determinants are fluoride concentration and its frequency and duration of exposure, density or rate of fluoride bio-accumulation, age, sex, habits, nutrition and food constituents, chemical constituents of drinking water, environmental factors as well as individual health, susceptibility, biological response, tolerance, and genetics [45-52].

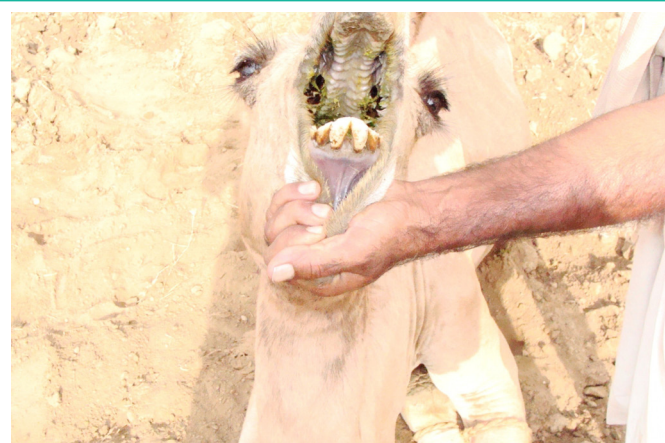
### Fluoride Susceptibility in Camels

Camels are morpho-anatomically and physiologically adapted to arid environment characterized by high temperature and water scarcity. These are known to survive in hostile environmental conditions without having the need to drink water for more than 30 days [53]. They are also adapted physiologically to obtain and retain water from their food resources, which re-

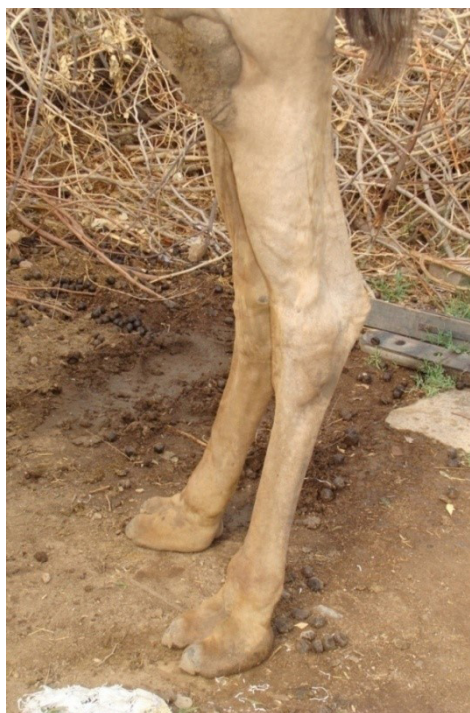

duces the intake of fluoride-rich drinking water. This is one of the ways by which camels have low level of severity of fluoride poisoning. In general, immature animals are more susceptible to chronic fluoride toxicosis as compared to mature animals [37]. However, bovine calves have maximum susceptibility to fluoride poisoning [54]. Hence these are ideal bio- indicators for endemic of fluoride and fluorosis [55].

In India, few studies were conducted on fluorosis in different species of domestic animals (bovines, flocks, equines, and camels) residing in fluoride endemic areas of Rajasthan state [56-59]. These animals were studied in three different areas having fluoride concentration <1.5 ppp (Table 1), 3.1-6.1 ppm (Table 2), and 2.0-5.7 ppm (Table 3) in drinking groundwater sources. The highest prevalence and severity of osteo-dental fluorosis was found in grass-eater (grazer) bovines and lowest in plant-eater (browser) camels and flocks. This indicates that bovines are relatively more susceptible to F toxicosis compared to camels and flocks. However, immature animals are more susceptible to fluoride compared to adult animals [37]. These findings suggest that some available chemical substances in foods are responsible for making the difference and influence the chronic fluoride toxicity in these animals. In fact, camel and flock animals generally feed on small delicate fresh leaves, pods, and small fruits of trees and shrubs which contain ample amount of calcium (Ca) and ascorbic acid (vitamin C) nutrients [49,50]. Both nutrients may neutralize the effect of excess fluoride content or interfere with the fluoride metabolism and ultimately reduce the fluoride toxicity in these animals [1,49,60,61]. It is evidently cleared that either these nutrients are protective against to fluoride toxicity in humans but whether these are protective or not in camels, more experimental scientific studies are needed.



**Figures a & b:** Moderate to severe dental fluorosis in juvenile (Figure a) and adult camels (Figure b) characterised with light to deep brownish staining on anterior teeth, diffused to well marked spots (central incisors), and irregular wearing. Recession of teeth supporting bone with recession and bulging of gingival tissue is also present [36,39].



**Figure c:** Hind legs of 11-year-old male camel (Figure 4) showing diffused to well mark bony lesions (periosteal exostoses) on the femoral, fibular, tarsal, and metatarsal regions. This camel also had dental fluorosis [36].



**Figure d:** Emaciated 11-year-old male camel afflicted with skeletal fluorosis. Note wasted thigh and shoulder muscles and bulging lesions on posterior region of the mandible and lacrimal bones [36].

### Conclusion

Successive exposure to high fluoride for prolonged period through drinking water and industrial fluoride pollution in dromedary camels causes chronic fluoride intoxication in the form of fluorosis. In the world, chronic fluorosis has not been studied extensively in domesticated dromedaries as compared to other domestic animals, bovines, equines, and flocks, though these animals are economically as well as biologically very important. In fact, camels are desert animals and are perfectly adapted to dry environments and they can survive without water for >30 days. In these desert animals, both forms of fluorosis, industrial fluorosis and hydrofluorosis have been reported.

**Table 1:** Prevalence of dental and skeletal fluorosis in immature animals of different species living in areas with low fluoride (<1.5ppm) in drinking water [37].

Animals (spp)	No. of animals (age) investigated	No. of animals showed		Total
		DF	SF	
Buffaloes ( <i>B. bubalis</i> )	78 (<3 years)	41 (52.56)	8 (10.25)	49 (62.82)
Cattle ( <i>B. taurus</i> )	89 (<3 years)	44 (49.43)	8 (8.98)	52 (58.42)
Donkey ( <i>E. asinus</i> )	30 (<3 years)	5 (16.66)	-(0.00)	5 (16.66)
Horses ( <i>E. caballus</i> )	21 (<3 years)	3 (14.28)	-(0.00)	3 (14.28)
Camels ( <i>C. dromedarius</i> )	23 (<6 years)	-(0.00)	-(0.00)	-(0.00)
Goats ( <i>C. hircus</i> )	96 (<1 year)	-(0.00)	-(0.00)	-(0.00)
Sheep ( <i>O. aries</i> )	92 (<1 year)	-(0.00)	-(0.00)	-(0.00)
Total	435	93(21.37)	16 (3.67)	109 (25.05)

Figures in parentheses indicate percentage. DF: Dental Fluorosis; SF: Skeletal Fluorosis

**Table 2:** Prevalence of dental and skeletal fluorosis in domestic animals living in areas with high fluoride content (>3.0 ppm) in drinking water [38].

Animal (species)	Immature animals		Mature animals		Lameness
	DF	SF	DF	SF	
Cattle ( <i>B. taurus</i> )	63/78 (80.7)	21/78 (26.9)	328/518 (63.3)	267/518 (51.5)	+++
Buffaloes ( <i>B. bubalis</i> )	62/64 (96.8)	22/64 (34.3)	209/312 (66.9)	188/312 (60.2)	+++
Donkeys ( <i>E. asinus</i> )	16/33 (48.4)	6/33 (18.1)	39/106 (36.7)	28/106 (26.4)	++
Horses ( <i>E. caballus</i> )	7/16 (43.7)	3/16 (18.7)	23/70 (32.8)	17/70 (24.2)	++
Camels ( <i>C. dromedarius</i> )	4/18 (22.2)	2/18 (11.1)	13/67 (19.4)	12/67 (17.9)	+
Sheep ( <i>O. aries</i> )	12/126 (9.5)	-/126 (0.0)	112/544 (20.5)	54/544 (9.9)	+
Goats ( <i>C. hircus</i> )	8/108 (7.4)	-/108 (0.0)	102/538 (18.9)	47/538 (8.7)	+
Total	172/443 (38.8)	54/443 (12.1)	826/2155(38.3)	613/2155 (28.4)	

Figures in parentheses indicate percentage. DF dental fluorosis, SF skeletal fluorosis +, mild; ++, moderate; +++, severe

**Table 3:** Relative prevalence of dental and skeletal fluorosis in camels, bovines and humans living in desert environment with fluoride in drinking water in the 2.0–5.7 ppm range [39].

	Number examined	Adults exhibiting		Young/juveniles exhibiting	
		DF (%)	SF (%)	DF (%)	SF (%)
Camels	238	27/195 (13.8)	20/195 (10.2)	4/43 (9.3)	1/43 (2.3)
Bovines*	210	77/168 (45.8)	69/168 (41.0)	26/42 (61.9)	12/42 (28.5)
Humans	218	78/160 (48.7)	78/160 (48.7)	34/58 (58.6)	30/58 (31.0)
Total	666	182/523 (34.7)	167/523 (31.9)	64/143 (44.7)	43/143 (29.4)

\*Indicates both cattle and buffaloes. DF, Dental fluorosis; SF, Skeletal fluorosis.

Fluoride-induced dental mottling and diverse bony changes (exostosis, osteosclerosis, osteoporosis, and osteophytosis) are the main characteristic of chronic fluoride poisoning in camels. Among different species of domestic bovine and equine animals, dromedary camels are found to be less susceptible to chronic fluoride poisoning due to nutrients such as calcium and vitamin C present in their food. However, for its further confirmation more research survey studies in large number of camels are highly suggestive.

#### Conflict of Interest

The author declares no conflict of interest.

#### Acknowledgements

The author thanks to Dr. Darshana Choubisa, Associate Professor, Department of Prosthodontics and Crown and Bridge, Geetanjali Dental and Research Institute, Udaipur, Rajasthan 313002, India for cooperation.

#### References

- Adler P, Armstrong WD, Bell ME, Bhussry BR, Büttner W, Cremer H-D, et al. Fluorides and human health. World Health Organization Monograph Series No. 59. Geneva: World Health Organization, 1970.
- Choubisa SL, Sompura K, Bhatt SK, Choubisa DK, Pandya H, Joshi SC, et al. Prevalence of fluorosis in some villages of Dungarpur district of Rajasthan. Indian Journal of Environmental and Health. 1996; 38: 119-126.
- Choubisa SL, Choubisa DK, Joshi SC, Choubisa L. Fluorosis in some tribal villages of Dungarpur district of Rajasthan, India. Fluoride. 1997; 30: 223-228.
- Choubisa SL. Endemic fluorosis in southern Rajasthan (India). Fluoride. 2001; 34: 61-70.
- Choubisa SL, Choubisa L, Choubisa DK. Endemic fluorosis in Rajasthan. Indian Journal of Environmental and Health. 2001; 43: 177-189.



6. Choubisa SL. Fluoride in drinking water and its toxocosis in tribals, Rajasthan, India. . Proceedings of the National Academy of Sciences, India Section B: Biological Sciences. 2012; 82: 325-330.
7. Choubisa SL, Choubisa D. Neighbourhood fluorosis in people residing in the vicinity of superphosphate fertilizer plants near Udaipur city of Rajasthan (India). Environmental Monitoring and Assessment. 2015; 187: 497.
8. Choubisa SL. A brief and critical review of hydrofluorosis in Rajasthan, India. Fluoride. 2018; 51: 13-33.
9. Choubisa SL, Choubisa D. Status of industrial fluoride pollution and its diverse adverse health effects in man and domestic animals in India. Environmental Science and Pollution Research. 2016; 23: 7244-7254.
10. Choubisa SL. Status of chronic fluoride exposure and its adverse health consequences in the tribal people of the scheduled area of Rajasthan, India. Fluoride. 2022; 55: 8-30.
11. Choubisa SL, Choubisa D, Choubisa A. Fluoride contamination of groundwater and its threat to health of villagers and their domestic animals and agriculture crops in rural Rajasthan, India. Environmental Geochemistry and Health. 2022. doi: [10.1007/s10653-022-01267-z](https://doi.org/10.1007/s10653-022-01267-z).
12. Araya O, Wittwer F, Villa A, Duc C. Bovine fluorosis following volcanic activity in the southern Andes. Veterinary Record. 1990; 126: 641-642.
13. Mohiuddin SM, Reddy MV. Haematological and biochemical studies on fluoride toxicity in sheep. Indian Veterinary Journal. 1989; 66: 1089-1091.
14. Singh JL, Swarup D. Fluorosis in buffaloes. Veterinary Research. 1994; 135: 260-261.
15. Suttie JW, Clay AR, Shearer TR. Dental fluorosis in bovine temporary teeth. American Journal of Veterinary Record. 1985; 46: 404-408.
16. Swarup D, Singh YP. Bovine fluorosis in a brick kiln congested zone. Indian Journal of Veterinary Medicine. 1989; 9: 12-14.
17. Choubisa SL, Pandya H, Choubisa DK, Sharma OP, Bhatt SK, Khan IA. Osteo-dental fluorosis in bovines of tribal region in Dungarpur (Rajasthan). Journal of Environmental Biology. 1996; 17: 85-92.
18. Choubisa SL. Chronic fluoride intoxication (fluorosis) in tribes and their domestic animals. International Journal of Environmental Studies. 1999; 56: 703-716.
19. Choubisa SL. Some observations on endemic fluorosis in domestic animals of southern Rajasthan (India). Veterinary Research Communications. 1999; 23: 457-465.
20. Choubisa SL. Fluoride toxicity in domestic animals in Southern Rajasthan. Pashudhan. 2000; 15: 5.
21. Choubisa SL. Fluoridated ground water and its toxic effects on domesticated animals residing in rural tribal areas of Rajasthan (India). International Journal of Environmental Studies. 2007; 64: 151-159.
22. Choubisa SL. Dental fluorosis in domestic animals. Current Science. 2008; 95: 1674-1675.
23. Choubisa SL. Osteo-dental fluorosis in horses and donkeys of Rajasthan, India. Fluoride. 2010; 43: 5-10.
24. Choubisa SL. Status of fluorosis in animals. Proceedings of the National Academy of Sciences, India Section B: Biological Sciences. 2012; 82: 331-339.
25. Choubisa SL, Modasiya V, Bahura CK, Sheikh Z. Toxicity of fluoride in cattle of the Indian Thar Desert, Rajasthan, India. Fluoride. 2012; 45: 371-376.
26. Choubisa SL. Industrial fluorosis in domestic goats (*Capra hircus*), Rajasthan, India. Fluoride. 2015; 48: 105-115.
27. Choubisa SL. A brief review of industrial fluorosis in domesticated bovines in India: focus on its socio-economic impacts on livestock farmers. Journal of Biomed Research. 2023; 4(1): 8-15.
28. Choubisa SL. A brief and critical review on hydrofluorosis in diverse species of domestic animals in India. Environmental Geochemistry and Health, 2018; 40(1): 99-114.
29. Choubisa SL, Mishra GV. Fluoride toxicosis in bovines and flocks of desert environment. International Journal of Pharmacology and Biological Sciences. 2013; 7: 35-40.
30. Choubisa SL. A brief and critical review of chronic fluoride poisoning (fluorosis) in domesticated water buffaloes (*Bubalus bubalis*) in India: focus on its impact on rural economy. Journal of Biomedical Research and Environmental Sciences. 2022; 3: 96-104.
31. Choubisa SL. Industrial fluoride emissions are dangerous to animal health, but most ranchers are unaware of it. Austin Environmental Sciences. 2023; 8(1): 1-4, 1089.
32. Choubisa SL. Endemic hydrofluorosis in cattle (*Bos taurus*) in India: an epitomised review. International Journal of Veterinary Science & Technology. 2023; 8(1): 001-007.
33. Karram MH, Motellib AA, Nafie TS, Sayed AS. Clinical and biochemical studies on chronic fluorosis and sulphurosis in camels. Assiut Veterinary Medical Journal. 1989; 21: 160-171.
34. Karram MH, Ibrahim TA. Effect of industrial fluorosis on haemogram of camels. Fluoride. 1992; 25: 23-36.
35. Diacono E, Faye B, Bengoumi M, Kessabi M. Hydrotelluric and industrial fluorosis survey in the dromedary camel in the South of Morocco. In: Faye B., Sinyavskiy, Y. (eds) Impact of Pollution on Animal Products. NATO Science for Peace and Security Series C: Environmental Security. 2008; Springer, Dordrecht.
36. Choubisa SL. Fluorosis in dromedary camels of Rajasthan, India. Fluoride. 2010; 43: 194-199.
37. Choubisa SL. Fluoride toxicosis in immature herbivorous domestic animals living in low fluoride water endemic areas of Rajasthan, India: an observational survey. Fluoride. 2013; 46: 19-24.
38. Choubisa SL. Fluorotoxicosis in diverse species of domestic animals inhabiting areas with high fluoride in drinking waters of Rajasthan, India. Proceedings of the National Academy of Sciences, India Section B: Biological Sciences. 2013; 83: 317-321.
39. Choubisa SL. Why desert camels are least afflicted with osteo-dental fluorosis? Current Science. 2013; 105: 1671-1672.
40. Choubisa SL. The diagnosis and prevention of fluorosis in humans. Journal of Biomedical Research and Environmental Sciences. 2022; 3: 264-267.
41. Choubisa SL. How can fluorosis in animals be diagnosed and prevented? Austin Journal of Veterinary Science and Animal Husbandry. 2022; 9: 1-5.
42. Choubisa SL. Toxic effects on bones. Advances in Pharmacology and Toxicology. 2012; 13: 9-13.
43. Choubisa SL. Radiological skeletal changes due to chronic fluoride intoxication in Udaipur district (Rajasthan). Pollution Research. 1996; 15: 227-229.

44. Choubisa SL. Radiological findings more important and reliable in the diagnosis of skeletal fluorosis. *Austin Medical Sciences*. 2022; 7: 1-4.
45. Choubisa SL, Choubisa L, Sompura K, Choubisa D. Fluorosis in subjects belonging to different ethnic groups of Rajasthan. *Journal of Communicable Diseases*. 2007; 39: 171-177.
46. Choubisa SL, Choubisa L, Choubisa D. Osteo-dental fluorosis in relation to nutritional status, living habits and occupation in rural areas of Rajasthan, India. *Fluoride*. 2009; 42: 210-215.
47. Choubisa SL, Choubisa L, Choubisa D. Osteo-dental fluorosis in relation to age and sex in tribal districts of Rajasthan, India. *Journal of Environmental Sciences and Engineering*. 2010; 52: 199-204.
48. Choubisa SL. Natural amelioration of fluoride toxicity (fluorosis) in goats and sheep. *Current Science*. 2010; 99: 1331-1332.
49. Choubisa SL, Choubisa L, Choubisa D. Reversibility of natural dental fluorosis. *International Journal of Pharmacology and Biological Sciences*. 2011; 5: 89-93.
50. Choubisa SL, Mishra GV, Sheikh Z, Bhardwaj B, Mali P, Jaroli VJ. Food, fluoride, and fluorosis in domestic ruminants in the Dungarpur district of Rajasthan, India. *Fluoride*. 2011; 44: 70-76.
51. Choubisa SL. Osteo-dental fluorosis in relation to chemical constituents of drinking waters. *Journal of Environmental Sciences and Engineering*. 2012; 54: 153-158.
52. Choubisa SL, Choubisa A. A brief review of ideal bio-indicators, bio-markers and determinants of endemic of fluoride and fluorosis. *Journal of Biomedical Research and Environmental Sciences*. 2021; 2: 920-925.
53. Bornstein S. The ship of the desert. The dromedary camel (*Camelus dromedarius*), a domesticated animal species well adapted to extreme conditions of aridness and heat. *Rangifer*. 1990; 3: 231-236.
54. Choubisa SL. Chronic fluoride exposure and its diverse adverse health effects in bovine calves in India: an epitomised review. *Global Journal of Biology, Agriculture and Health in Sciences*. 2021; 10: 1-6.
55. Choubisa SL. Bovine calves as ideal bio-indicators for fluoridated drinking water and endemic osteo-dental fluorosis. *Environmental Monitoring and Assessment*. 2014; 186: 4493-4498.
56. Choubisa SL, Sompura K, Choubisa DK, Pandya H, Bhatt SK, Sharma OP, et al. Fluoride content in domestic water sources of Dungarpur district of Rajasthan. *Indian Journal of Environmental and Health*. 1995; 37: 154-160.
57. Choubisa SL, Sompura K, Choubisa DK, Sharma OP. Fluoride in drinking water sources of Udaipur district of Rajasthan. *Indian Journal of Environmental and Health*. 1996; 38: 286-291.
58. Choubisa SL. Fluoride distribution and fluorosis in some villages of Banswara district of Rajasthan. *Indian Journal of Environmental and Health*. 1997; 39: 281-288.
59. Choubisa SL. Fluoride distribution in drinking groundwater in Rajasthan, India. *Current Science*. 2018; 114: 1851-1857.
60. Chinoy NJ, Reddy VVVC, Michael M. Beneficial effects of ascorbic acid and calcium on reproductive functions of sodium fluoride treated prepubertal rats. *Fluoride*. 1994; 27(2): 67-75.
61. Choubisa SL. A brief review of chronic fluoride toxicosis in the small ruminants, sheep and goats in India: focus on its adverse economic consequences. *Fluoride*. 2022; 5(4), Epub 192, Feb 12 0559.