

Research Article

Antiviral Therapy Causing Polyarteritis Nodosa

Bansal R², Nisar U³, Islam M⁴, Basha A⁵, Javidulla Khan⁵, Arshi J⁶, Tarafdar Y⁷, Kaleem A⁹, Mithwani A⁸, Sakib-uz-zaman M⁴, Narayanaswamy M¹⁰ and Shahid S^{1*}

¹Department of Internal Medicine, Karachi Medical & Dental College, Pakistan

²Department of Medicine, Gian Sagar Medical College & Hospital, India

³Department of Medicine, Sri Venkateshwara Medical College, India

⁴Department of Medicine, Sir Salimullah Medical College, Bangladesh

⁵Department of Internal Medicine, Deccan College of Medical Sciences, India

⁶Department of Internal Medicine, Owaisi Hospital & Research Centre, India

⁷Department of Medicine, Agartala Government Medical College, India

⁸Department of Internal Medicine, Rocky view General Hospital & South Health Campus Calgary, Alberta Canada

⁹Department of Medicine, Nishtar Medical College, Pakistan

¹⁰Department of Internal Medicine, Sri Siddharta Medical College, Tumkur India

*Corresponding author: Sonia Shahid, Department of Internal Medicine, Karachi Medical & Dental College, Pakistan

Received: July 12, 2018; Accepted: August 22, 2018;

Published: August 29, 2018

Introduction

Vasculitic lesions usually involve medium size arteries and spares large vessels and venous system, these lesions mostly occurs at bifurcations of medium size muscular arteries. Inflammation may first arise in intima of the wall than involve internal and external elastic lamina resulting in fibrinoid necrosis of the wall [1,2]. This necrosis weakens the vessel wall and this weakness gives rise to aneurysms with thrombi formation and as this lesion progresses it may lead to obstruction, ischemia and infarction with future risk to rupture and hemorrhage [3].

Polyarteritis nodosa is not a very common disease which occurs with the incidence of less than one cases per 100,000 population per annum The major environmental risk factor is hepatitis B; other associated viruses are HIV and parvovirus B19 [4]. Prior studies show the prevalence as high as 7.7 cases per 100,000 populations [5].

Treatment of PAN depends upon the level of disease severity, presence of isolated cutaneous PAN or other isolated/single-organ disease and presence or absence of viral infections. Patients with concurrent PAN and hepatitis virus infection benefit from treatment with antivirals, but the timing of therapy relative to the use of immune suppressive agents depends upon the severity of the vasculitis. In moderate to severe PAN, treatment typically entails both high-dose glucocorticoids and a second immunosuppressive drug, such as

Abstract

Poly Arteritis Nodosa (PAN) is an inflammatory disease of medium size arteries that leads to vessel wall necrosis and obstruction of majority of vessels leading to symptoms like palpable purpura, arthralgia, hematuria, abdominal pain and gastrointestinal bleeding, cardiomyopathies, pericarditis, peripheral vascular diseases, new onset hypertension, mononeuritis multiplex.

cyclophosphamide followed by azathioprine or MTX for remission maintenance [6], Evidence from case reports and case series and a few randomized controlled trials support plasma exchange as a major rescue-treatment modality for various systemic vasculitis diseases particularly in advanced renal dysfunction and disease refractory to normal therapy [7]. In patients with moderate to severe disease, but without organ or life-threatening involvement or progressive mononeuritis multiplex, oral glucocorticoids (prednisone 1mg/kg) should be initiated with a gradual taper over 6-8 months. In severe disease with organ or life-threatening disease, glucocorticoid therapy such as intravenous methyl prednisolone 500-1000mg once daily for 3 days, followed by oral glucocorticoid therapy provides more rapid control of disease, although there are no randomized trials comparing these regimens in this patient population.

Methodology

This is a cross-sectional study based on an idea of collecting data from low-income countries like; Pakistan, India and Bangladesh, collectively known as South East Asia; where almost 65% of the population is unvaccinated. Sample size is 1085. Patients of age 10 to 65 years were selected in this study. History and examination form designed particularly for the study by using application "FORMS", was filled by concerned doctors.

Patients, regardless of gender, presenting with different infections

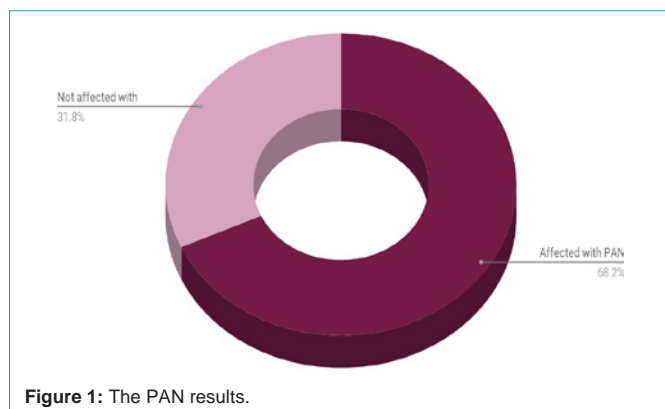


Figure 1: The PAN results.

coming to medicine and rheumatology departments were included in the study. At first a complete medical history was taken and a complete physical examination carried out. Serologic tests for viruses were performed with the measure of ESR. Finally, after gathering and classifying initial data, we used SPSS software version 16 for statistical analysis. T-test, Chi-Square statistical tests were done. Continuous data was mentioned as mean \pm SD and categorical data as proportions. P-values less than 0.05 were considered statistically significant. According to the fact that all reviews and treatments were depended on patient's needs and avoided any unnecessary examinations and their personal information won't be obtained by any factual or legal authorities, this research does not have any ethical problems.

Inclusion criteria

Patients from age 10 years to 65 years were recruited in this study. All patients underwent minimum of 2 weeks of antiviral therapy in the last 4 years were included in this study.

Exclusion criteria

Patients with any metabolic disorder and the individuals who did not consent to give information and blood sample for the study were excluded.

Results

Sum of patients who had antiviral therapy within 4 years were 1085. Male female ratio was 2:1. Out of 1085 patients, 275 patients were affected with hepatitis B virus, 121 with hepatitis C virus, 97 with EBV, 226 with HIV, 189 with HPV, 22 with CMV while 155 with H-Influenza virus. 740 were suffered with Polyarteritis nodosa and 345 were not.

The results are summarized in following (Table 1) and (Figure 1).

Conclusion

Antiviral therapy is now one of routine practices and as common as antibiotics against bacterial infection. Therefore it is important for the clinicians to understand the differences between bacterial and viral infections in order to use antiviral drugs properly [8]. Antivirals along with steroids and plasma pheresis are thought to be beneficial in PAN while treating Hep B & C infections, rather than just immune suppressants [9].

Discussion

PAN is a multisystem disease that may present with fever, sweats,

Table 1: Sum of patients who had antiviral therapy within 4 years were 1085.

AGE	Hep B	Hep C	EBV	HIV	HPV	CMV	H.Influ
10-15 y	57	17	17	9	-	15	41
16-20 y	55	23	35	92	47	2	46
21-40 y	89	72	37	114	82	4	55
41-65 y	74	9	8	11	60	1	13

weight loss, and extreme muscle and joint pains. PAN may develop in a sub acute fashion, over several weeks or months. Patients may have nonspecific complaints such as fever, malaise, weight loss, anorexia, and abdominal pain. The disease can affect nearly any site in the body, but it has a predisposition for organs such as the skin, kidney, nerves, and gastrointestinal tract. Many patients with PAN has high blood pressure and elevated Erythrocyte Sedimentation Rates (ESR). The presentation of PAN may also include skin abnormalities (ulcers, purpura) and peripheral neuropathy (pain, the sensations of burning, tingling, or numbness, or weakness in a hand or foot). However, the disease has a predilection for certain organs and tissues; like, nerve, skin, kidney, gastrointestinal tract, heart, eye and genitals [10]. PAN is seen with hep B patients who are on antivirals but none vaccinated. This indirectly goes against several antivirals used for the treatment as they are not as effective against hep B virus which can ultimately cause PAN. Historically, PAN has been treated with corticosteroids alone or in combination with cyclophosphamide. Some evidence suggests that anti HBV treatment combined with therapeutic plasma exchange improves HBV-PAN. We believe the initial rapid improvement in the HBV-PAN patient is due to a combination of anti-HBV therapy, corticosteroids and plasma exchange.

Patients with cutaneous-only PAN or other single-organ presentations of PAN must be followed regularly for the possible development of disease in new organ systems. In addition to clinical examinations and appropriate follow-up of patient-reported symptoms, periodic measurement of serum creatinine and a urinalysis can help monitor for asymptomatic renal disease. Erythrocyte sedimentation rate and C-reactive protein may correlate with activity of disease.

References

- <https://reference.medscape.com/medline/abstract/28490787>.
- <https://reference.medscape.com/viewpublication/7154>.
- Current rheumatology reports. Medscape. 2018; 20.
- Sharma A, Sharma K, Hepatotropic Viral Infection Associated Systemic Vasculitides--Hepatitis B Virus Associated Polyarteritis Nodosa and Hepatitis C Virus Associated Cryoglobulinemic Vasculitis. J Clin Exp Hepatol. 2013; 3: 204-212.
- Hepatology (Baltimore, Md.). Medscape. 2018; 67.
- Shiraki K, Daikoku T, Takemoto M, Himaki T, Kuramoto T. Mechanism of action of antiviral drugs. Nihon Rinsho. 2012; 70: 545-551.
- Mahr A, Chaigne-Delalande S, De Menthon M. Therapeutic plasma exchange in systemic vasculitis: an update on indications and results. Curr Opin Rheumatol. 2012; 24: 261-266.
- Types of Vasculities. Polyarteritis Nodosa. The Johns Hopkins vasculities center.
- Schirmer JH, Holl-Ulrich K, Moosig F. [Polyarteritis nodosa: differential diagnostics and therapy], Z Rheumatol. 2014; 73: 917-926.
- Types of Vasculities. Polyarteritis Nodosa. The Johns Hopkins vasculities center.