

Clinical Image

Radical Nephroureterectomy: A Clinical Image

Mohammed M*, Dieudonné ZOJ*, Jaafar M, Soufiane E, Youness R, Mustapha A, Soufiane M, Fadl TM, El-Ammari JE, Jamal EM and Hassan FM

Urology Division, Teaching Hospital Hassan 2, Fez, Morocco

***Corresponding author:** Mzyiene Mohammed, Urology Division, CHU Hassan 2, Fez, Morocco

Ziba Ouima Justin Dieudonné, Urology Division, CHU Hassan 2, Fez, Morocco

Received: June 26, 2021; **Accepted:** July 15, 2021;

Published: July 22, 2021

Keywords

Upper urinary tract urothelial carcinoma; Nephroureterectomy; Urothelial carcinoma; Prognostic factors

Clinical Image

Upper Urinary Tract Urothelial Carcinoma (UTUC) remain rare. Radical Nephroureterectomy (RNU) is the Gold standard for management of these tumours. We are reporting a clinical image of a 45-year-old patient admitted in emergency for left lumbar pain (nephritic colic). The checkups requested computed tomography scanner showed a nephromegaly and left hydronephrosis upstream of a suspicious parietal thickening of the lumbar ureter with cortical and functional repercussion, neighborhood infiltration, and atypical lateral-aortic ganglia. Left lower calicial lithiasis of stasis, pancreatic nodular lesion and the left adrenal gland. The patient was a candidate for an open Radical Left Nephroureterectomy (RNU) (Figure 1).

There are prognostic factors of tumors of the upper urinary excretory tract, which are the patient's status, the preoperative, the operation and the anatomopathology [1]. According to current literature data, the oncology outcomes of radical nephroureterectomy by laparoscopic are lower than those of open RNU surgery [2].

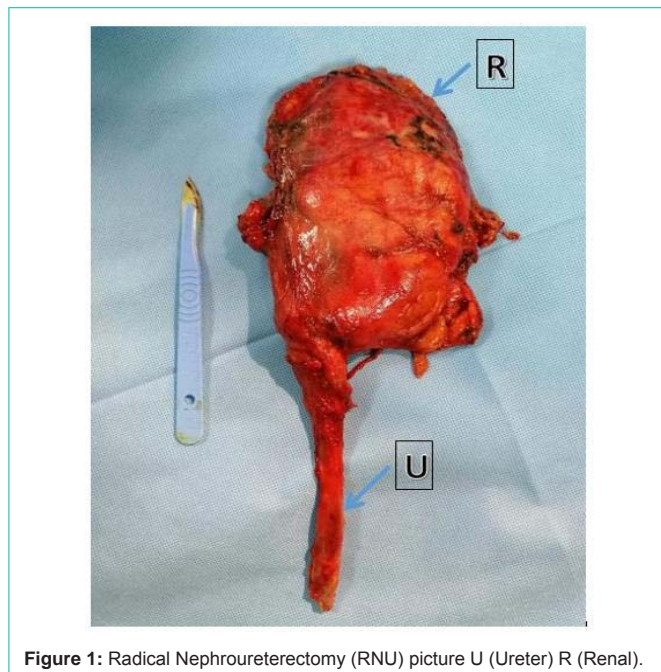


Figure 1: Radical Nephroureterectomy (RNU) picture U (Ureter) R (Renal).

References

1. Elalouf V, Klap J, Delongchamps N-B, Conquy S, Sibony M, Saighi D, et al. Facteurs pronostiques des tumeurs de la voie excrétrice urinaire supérieure. *Prog En Urol.* 2013; 23: 1382-1388.
2. Peyronnet B, Seisen T, Dominguez-Escrig J-L, Bruins HM, Yuan CY, Lam T, et al. Oncological Outcomes of Laparoscopic Nephroureterectomy versus Open Radical Nephroureterectomy for Upper Tract Urothelial Carcinoma: An European Association of Urology Guidelines Systematic Review. *Eur Urol Focus.* 2019; 5: 205-223.