

## Case Report

# Retrocaval Ureter: A Case Report

**Hegazi A\***

Chief Resident of Urology, Sudan Medical Specialization Board, Khartoum, Sudan

\***Corresponding author:** Albra Hegazi, Chief Resident of Urology, Sudan Medical Specialization Board, Khartoum, Sudan

**Received:** October 08, 2021; **Accepted:** November 03, 2021; **Published:** November 10, 2021

## Abstract

Retrocaval ureter is a rare congenital anomaly of the IVC, patient of this condition mainly presents with right flank pain in our case we report in Khartoum, Sudan a 37-year-old man, whose presented with features are suggestive of retrocaval ureter, which is diagnosed by a computed tomography and we treated with open surgical repair. In conclusion, this is one of the rare and demanding cases for urologists that is need further care and management.

**Keywords:** Retrocaval ureter; Hydronephrosis; Congenital venous

## Introduction

Retrocaval or circumcaval ureter is first described by Hochstetter in 1893, which is one of the rare congenital venous anomalies. In this condition, the right ureter goes posterior to the inferior vena cava and partially encompasses it [1].

Patients who suffer from RCU usually present at there forth or fifth decades with flank or a dull aching pain [2].

Most of patients present with right loin pain and obstructive uropathy symptoms as a result of dilated proximal ureter and hydronephrosis [2].

A computed tomography is investigation of choice in case of retrocaval ureter [1].

We report a 37-year-old male who presented with Pelvoureteric junction obstruction as a result of retrocaval ureter.

## Case Presentation

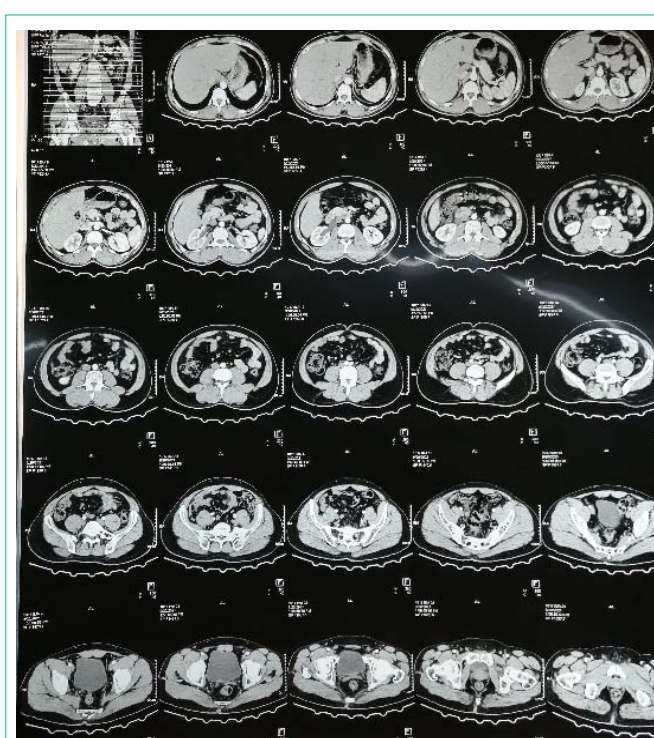
A 37-year-old male, come to our urology outpatient in with right loin pain for one month. The pain not associated with fever, rigor or hematuria along with no LUTS. On examination there, a mild tenderness on his right flank. His past medical history was unremarkable. There is no significant abnormality vale on his laboratory tests. A CTU showed a 'S'-shaped deformity in the proximal dilated right ureter with moderate hydronephrosis (Figure 1 and 2), therefore, retrocaval ureter was confirm and surgical repair was performed.

## Discussion

Retrocaval ureter is first described by Hochstetter in 1893 as congenital anomaly of the ureter. At 1997, further embryological study showed that it is a congenital anomaly of the IVC [3].

Its incidence is about 0.06-0.17% worldwide, with three times higher occurrence in males than females, there is more than 200 cases reported worldwide.

Retrocaval ureter has been classified into two clinical types, accordance to radiological appearance it has been classified into two types: The common one is type 1 ('low loop'), usually medial to the pedicle or across the midline at the L3 level. An "S" or "fish hook" deformity is found at the level of obstruction. The second type



**Figure 1:**

is in type 2 in which there is mild hydronephrosis and less medial deviation of the ureter. The ureter is noted to be sickle shaped at the level of obstruction [2].

Generally, patients present with symptoms that related to ureteral obstruction and hydronephrosis, such as right flank pain, repetitive urinary tract infections and renal stones; patients may complain of hematuria [1].

Diagnosis of retrocaval ureter is usually done by imaging studies such as Intravenous Urogram (IVU), Retrograde Pyelouretogram (RGP) or Computerized Tomography (CT) scan, abdominal ultrasound is useful, it demonstrate hydronephrosis and proximal hydroureter, which are major signs of RCU. Typical 'fish hook' or 'J'- or 'S'-shaped deformities in the proximal dilated ureter are appear in intravenous urogram. CT scan is the goldstandered investigation in diagnosis of RCU [4].

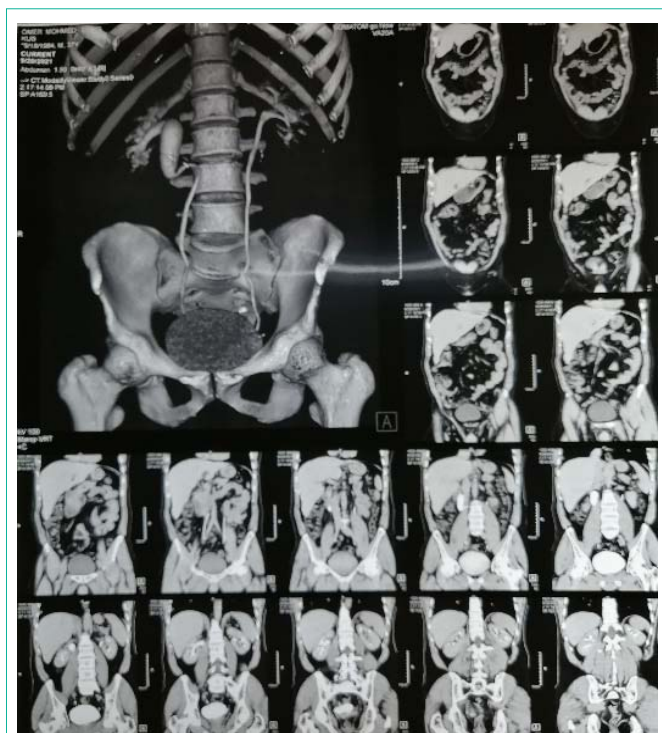


Figure 2:

Surgical rapier was important specially on patients whose renal functions start to deteriorate. There is a many type for surgical technique but open surgical pyelopylostomy is agoldstander technique [4]. N this case and under possible aseptic conditions by general antithesia we put the patient in flank position and by open surgical technique a pyelopylotomy wad preformed.

#### References

1. Zhang X, Hou S, Zhu J, Wang X, Meng G, Qu X. Diagnosis and Treatment of Retrocaval Ureter. *Eur Urol.* 1990; 18: 207-210.
2. Al-Hajjaj M, Tallaa M. Retrocaval ureter: a case report. *J Surg Case Reports.* 2021; 2021: 1-3.
3. Arruda GJF de, Neto JF de A, Eroles JC, Spessoto LCF, Arruda JGF de, Fácio FN, et al. Incidental finding of retrocaval ureter in a patient without hydronephrosis. *AME Case Reports.* 2018; 2: 42.
4. Qureshi MA, Mulvaney WP. Retrocaval Ureter: Report of Two Cases. *Am Surg.* 1965; 31: 50-52.