

Clinical Image

Giant Pyelic Stone: Clinical Image

Mohammed M*, Dieudonné ZOJ*, Jaafar M, Youness R, Mustapha A, Soufiane M, Fadl TM, Eddine EJ, Jamal EM and Hassan FM
Urology Division, Teaching Hospital Hassan 2, Fez, Morocco

***Corresponding author:** Mzyiene Mohammed,
Urology Division, CHU Hassan 2, Fez, Morocco

Ziba Ouima Justin Dieudonné, Urology Division, CHU Hassan 2, Fez, Morocco

Received: July 25, 2021; **Accepted:** August 17, 2021;

Published: August 24, 2021

Keywords

Urolithiasis; Pyelic stone; Staghorn calculi; Lumbar pain

Clinical Image

The management of giant stones of the upper urinary tract remains a challenge for the urologist because of the potential risk of treatment-related complications [1]. We report as a clinical picture the case of a 42-year-old patient received for chronic right lumbar pain in whom the CT scan performed revealed the presence of a giant pyelic stone (Figure 1a and 1b) whose dimensions on the sagittal plane are 43.1mmx41.5mm. The patient underwent an open pyelolithotomy in our department, which allowed the extraction of a giant pyelic calculus of 12cm (Figure 1c). The postoperative course was simple.

The treatment of staghorn calculi is difficult. They are stones that vary in size, position and chemical composition within the kidney [2]. These staghorn calculi can affect the anatomy of the collecting system as well as renal function, making their treatment a challenge for urologists.

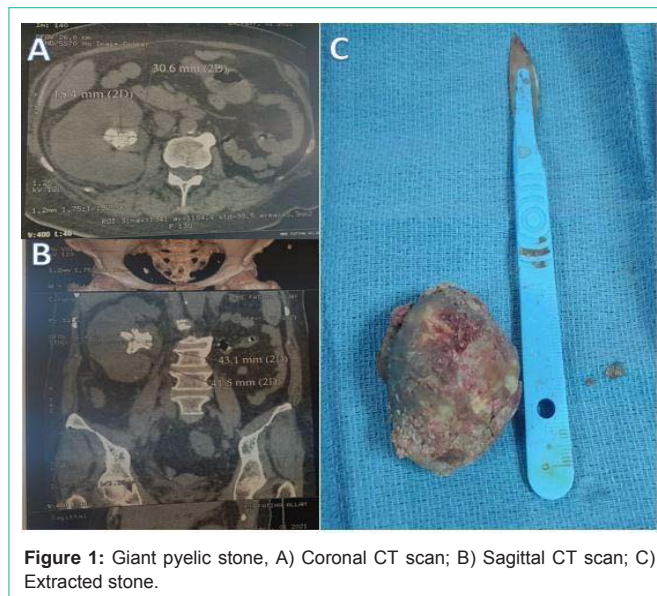


Figure 1: Giant pyelic stone, A) Coronal CT scan; B) Sagittal CT scan; C) Extracted stone.

References

1. Pradère B, Doizi S, Proietti S, Brachlow J, Traxer O. Evaluation of Guidelines for Surgical Management of Urolithiasis. *J Urol*. 2018; 199: 1267-1271.
2. Tzelves L, Türk C, Skolarikos A. European Association of Urology Urolithiasis Guidelines: Where Are We Going? *Eur Urol Focus*. 2021; 7: 34-38.