

Clinical Image

Urachal Sinus Surgery: Clinical Picture

Mohammed M*, Dieudonné ZOJ*, Jaafar M, Youness R, Mustapha A, Soufiane M, Fadl TM, Eddine EJ, Jamal EM and Hassan FM
Urology Division, Teaching Hospital Hassan 2, Fez, Morocco

***Corresponding author:** Mzyiene Mohammed, Urology Division, CHU Hassan 2, Fez, Morocco

Ziba Ouima Justin Dieudonné, Urology Division, CHU Hassan 2, Fez, Morocco

Received: July 09, 2021; **Accepted:** July 24, 2021;

Published: July 31, 2021

Keywords

Urachus, Sinus, Cyst, Allantois, Umbilicus

Clinical Image

The urachus is a fibrous cord, a remnant of the duct, which in the embryo, connects the bladder with the allantois duct [1]. The urachus can be the site of two types of lesions: on the one hand, congenital anomalies resulting from a defect in the obliteration of the allantois duct (diverticula, fistulas, cysts, sinus), and on the other hand, acquired lesions, essentially of a tumoral nature and most often malignant (urachus carcinoma) [2].

We report the clinical picture of a 28-year-old patient, with a history of uropathology since childhood (hypospadias), chronic renal failure since 2017 under dialysis, neobladder type Mitrofanoff since 2009, admitted for the management of an umbilical abscessed collection. Abdominal MRI revealed a superinfected urachus sinus. The treatment consisted of complete open excision of the sinus (Figure 1) from the umbilicus to the urinary bladder. The postoperative course was simple.

A purulent umbilical discharge is often indicative of the presence of a urachus sinus; ultrasound and fistulography are sufficient for the diagnosis [3]. Excision of the urachus sinus by surgery is the standard treatment in this clinical situation [4].

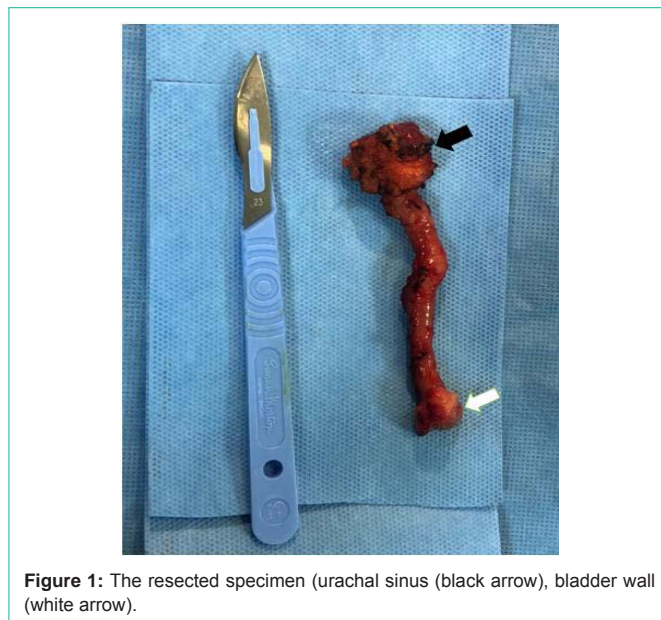


Figure 1: The resected specimen (urachal sinus (black arrow), bladder wall (white arrow)).

References

1. Parada Villavicencio C, Adam SZ, Nikolaidis P, Yaghmai V, Miller FH. Imaging of the Urachus: Anomalies, Complications, and Mimics. *Radiogr Rev Publ Radiol Soc N Am Inc.* 2016; 36: 2049-2063.
2. Das JP, Vargas HA, Lee A, Hutchinson B, O'Connor E, Kok HK, et al. The urachus revisited: multimodal imaging of benign & malignant urachal pathology. *Br J Radiol.* 2020; 93: 20190118.
3. Buddha S, Menias CO, Katabathina VS. Imaging of urachal anomalies. *Abdom Radiol N Y.* 2019; 44: 3978-3989.
4. Surgical strategy of urachal remnants in children. 2021.