

Case Report

Abdominal Trauma: Clinical Monitoring, an Overlooked yet Essential Ally

Malki Mohamed Amine*

Department of Urology, Centre Hospitalier Universitaire Hassan II (CHU Fes), Morocco

***Corresponding author: Malki Mohamed Amine**Department of Urology, Centre Hospitalier Universitaire Hassan II (CHU Fes), Morocco,
Email: aminemalki14@gmail.com**Received:** February 21, 2024**Accepted:** March 21, 2024**Published:** March 28, 2024

Introduction

Abdominal traumas, often resulting from road accidents, remain a critical concern in emergency surgery, demanding precise evaluation and immediate intervention [1]. The complexity and potential severity of these injuries necessitate a profound understanding of the mechanisms and appropriate therapeutic approaches. In this article, we present an exemplary case highlighting the gravity of abdominal traumas and the need for an effective multidisciplinary approach.

Case Presentation

Patient History

The patient, with no pre-existing medical conditions, was admitted to the emergency department after a road accident. Upon arrival, the patient was stable hemodynamically and respiratorily, with a blood pressure of 10/7 mmHg and a heart rate of 98 beats per minute.

Mechanism of the Accident

The accident involved a motorcyclist who received a handlebar impact to the abdominal region, resulting in a complex clinical presentation requiring thorough evaluation and immediate management.

Body Scanner Results (Figure 1,2)

The body scanner assessment revealed several severe injuries, including a dissection of the right renal artery leading to complete devascularization of the right kidney, a hepatic injury classified as stage 4 according to the ASAAT classification, thrombosis of a right segmental portal bronchus, a right adrenal hematoma, and a substantial intraperitoneal hemorrhage.

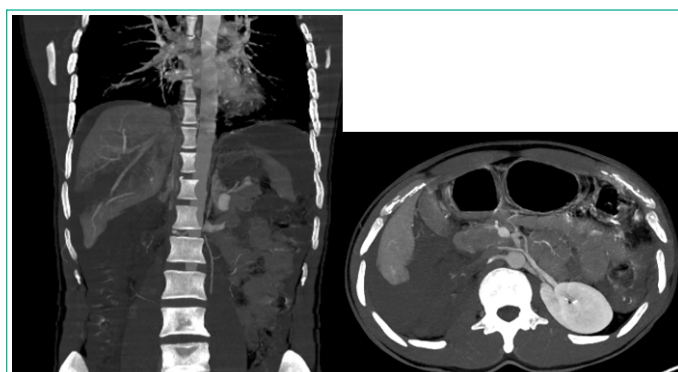

Figure 1: Coronal CT scan showing the right renal artery dissection (red arrow) with a renal devascularization (blue arrow) and the hepatic fracture (yellow arrow).

Biological Assessment

The patient's biological profile showed a hemoglobin level of 9 g/dL, elevated creatinine at 28 mg/dL indicating renal insufficiency, and a potassium level of 6 mmol/L. Faced with this complex clinical presentation, the decision was made to implement a comprehensive therapeutic strategy.

Discussion

The management of the presented case highlighted several key aspects in approaching severe abdominal traumas. Coordination between different specialties and prompt intervention proved crucial for the patient's recovery [2]. However, it is essential to emphasize that, in some cases, close monitoring can play a crucial role in therapeutic decision-making.

Close Monitoring: A Complementary Strategy

While our patient benefited from swift intervention, it is important to recognize that close monitoring, in the absence of immediate surgical intervention, can be an appropriate strat-

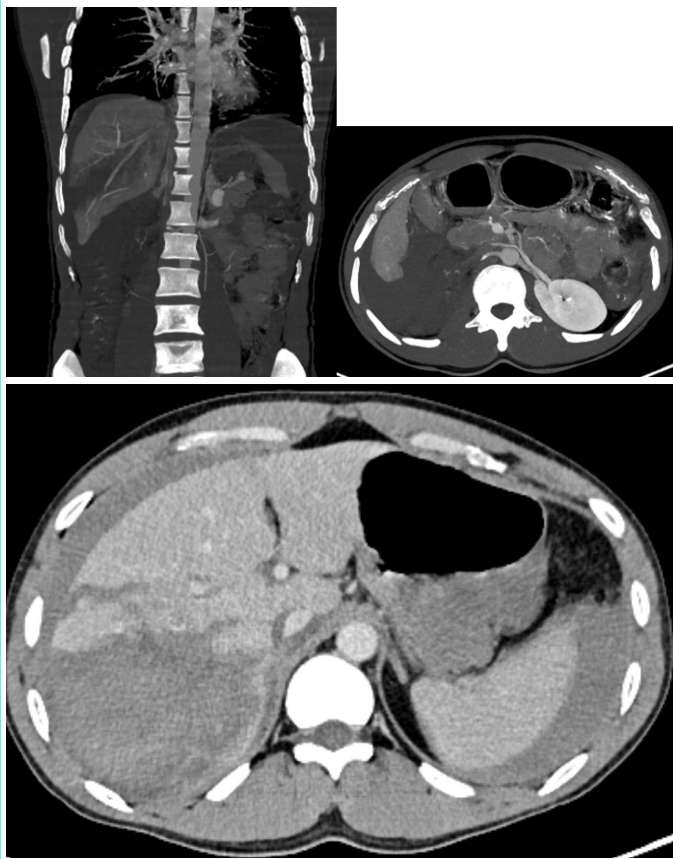


Figure 2: Coronal and axial CT scan showing the right renal devascularization (red arrow), a right adrenal hematoma (yellow arrow), the hepatic injury (green arrow), and anhemoperitoneum (blue arrow).

egy in certain situations [3]. Recent studies have suggested that vigilant monitoring can be a viable option for selected patients with abdominal traumas, especially when there is progressive clinical improvement and signs of controlled bleeding.

Factors for Selecting Close Monitoring

The decision to opt for close monitoring rather than immediate surgical intervention depends on several factors, such as the patient's hemodynamic stability, the evolution of biological parameters, and findings from medical imaging [4,5]. Specific criteria, including the resolution of hypotension, stability of hemoglobin, and the absence of worsening lesions, can guide the decision towards continuous monitoring.

Limitations of the Non-Operative Approach

However, it is crucial to recognize that the non-operative approach is not universally applicable, and each case must be individually evaluated. Some patients may require immediate surgical intervention due to the extensive nature of the injuries or rapid deterioration of their clinical condition [6].

Conclusion

In conclusion, the successful management of the presented case underscores the importance of rapid and multidisciplinary care for abdominal traumas. While surgical intervention remains a crucial strategy, close monitoring can be judicious in selected cases. Decision-making should be guided by ongoing evaluation, considering patient stability and lesion evolution. Future studies and interdisciplinary collaboration are necessary to further define selection criteria and refine strategies for managing abdominal traumas.

References

1. Scalea TM, Rodriguez A, Chiu WC, Brenneman FD, Fallon WF Jr, Kato K. Focused assessment with sonography for trauma (FAST): results from an international consensus conference. *J Trauma*. 1999; 46: 466-472.
2. Stassen NA, Bhullar I, Cheng JD, Crandall ML, Friese RS, Guilamondegui OD, et al. Selective nonoperative management of blunt splenic injury: an Eastern Association for the Surgery of Trauma practice management guideline. *J Trauma Acute Care Surg*. 2012; 73: S294-S300.
3. Peitzman AB, Richardson JD. Surgical treatment of injuries to the solid abdominal organs: a 50-year perspective from the *Journal of Trauma*. *J Trauma Acute Care Surg*. 2010; 69: 1011-1021.
4. Carrillo EH, Wohltmann CD, Richardson JD, Polk HC Jr. Evolution in the management of hepatic trauma: a 25-year perspective. *Ann Surg*. 1999; 229: 324-330.
5. van Ruler O, Mahler CW, Boer KR, Reuland EA, Gooszen HG, Opmeer BC, et al. Comparison of on-demand vs planned relaparotomy strategy in patients with severe peritonitis: a randomized trial. *JAMA*. 2007; 298: 865-872.
6. Pieracci FM, Stovall RT, Jaouen B, Rodil M, Cappa A, Burlew CC, et al. A multicenter, randomized clinical trial of IV iron supplementation for anemia of traumatic critical illness. *Crit Care Med*. 2014; 42: 2048-2057.