

Case Report

Tubercular Orchitis in Young Adult Presenting as Testicular Torsion: An Infrequent Finding

Pruthi SK, Nadesan A, Kamlesh*, Sarin N and Singh S

NDMC Medical College & Hindu Rao Hospital, New Delhi, India

*Corresponding author: Kamlesh, NDMC Medical College & Hindu Rao Hospital, New Delhi, India

Received: October 22, 2022; Accepted: November 15, 2022; Published: November 22, 2022

Abstract

A 56-year-old male patient with a sudden onset of severely progressive pain in the right-side testis associated with nausea and vomiting in the past one day was referred to the emergency room after he was found to have the pain that did not subside, even after a heavy dose of analgesics. His laboratory tests were within normal limit. USG revealed non-vascular unilateral testis. A clinical diagnosis of testis torsion was kept in mind which was confirmed by histopathological examination with an incidental finding of tubercular orchitis.

Testicular torsion is frequently seen in adolescents but association with tubercular orchitis is very rarely seen. The predisposing factors of testis torsion are environmental factors, preceding trauma, familial inheritance. Early diagnosis of testis lesions improves the end result. Testicular orchitis is the rare subtype of urogenital tuberculosis and mostly seen in middle age group males. Its can mimic testicular mass. Many studies reported testicular torsion cases but we haven't encountered any study reported tubercular orchitis without involvement of the epididymis in a patient with testis torsion. Hence, this is a very rare incidental histopathological finding, and our case report adds to the literature a rare incidental finding of tubercular orchitis coexisting with torsion testis.

Keywords: Tubercular Orchitis; Tuberculosis; Testis Torsion; Epididymis; Histopathology

Introduction

Testicular torsion is an emergency condition comprising 0.5% of all emergency department admissions. There occurs twisting of the spermatic cord with resultant ischemia [1]. It primarily affects adolescents, between 12-16 years of age [2]. Thus, early intervention and surgery are the only treatment options. However, rarely, testicular torsion has been reported in the elderly [3]. Torsion of the testis associated with tubercular orchitis is very uncommon and usually occurs in undescended testis. Tuberculosis (TB) affecting the testis without epididymal involvement is an even rarer phenomenon. To our knowledge, no other similar case report has been published in the literature previously.

Herein, we present a rare case of isolated tuberculous orchitis associated with testicular torsion in a 30-year-old male who presented to the emergency department with right-sided testicular pain.

Case Report

A 30-year-old male presented with a sudden onset of severely progressive pain in the right-side testis associated with nausea and vomiting in the past one day. The pain did not subside, even after a heavy dose of analgesics. On examination, he was an average-built man. His pulse rate and blood pressure were within normal limits. The respiratory rate was 14 cycles per minute and both lungs were clear. Lymphadenopathy was absent, with normal appearing scrotal skin. The transillumination test was negative.

A family history of tuberculosis or history of contact was absent.

There was no history of weight loss or fever. The complete blood count, including both total and differential white blood counts, were within normal limits. The chest X-ray and the abdominal X-ray were within normal limits. USG revealed a non-vascular right testis. Contralateral testis was normal. A clinical diagnosis of torsion testis was made, which was supported by imaging findings. An emergency right-side orchidectomy was performed, which was sent for histopathological examination.

On gross examination, testicular tissue measured 7x6x2.5 cm, and weighed 40 gm. Cut surface of the testes showed grey-white areas that were firm in consistency, with accompanying areas of haemorrhage and necrosis, along with adjacent viable testicular tissue (Figure 1a & b). Microscopically, multiple sections studied from the entire cut surface of the testis showed fibro-collagenous tissue, congested blood vessels, seminiferous tubules with normal sperm maturation, non-viable tubules, and caseating epithelioid histiocytic granulomas surrounded by multinucleated histiocytic giant cells and mononuclear inflammatory cell infiltrate (Figure 1c & d). The ZN stain for AFB was non-contributory. On the basis of these histopathological findings, a final diagnosis of testicular torsion with tubercular orchitis was made.

Discussion

Testicular torsion presents as an abrupt onset of unilateral scrotal pain associated with nausea, vomiting, lower abdominal pain, and inguinal pain. Patients frequently present with skin changes of the scrotum; however, scrotal lump and tenderness can also be seen. Clinical signs such as Prehn's sign, Brenzel sign, and Ger's sign help

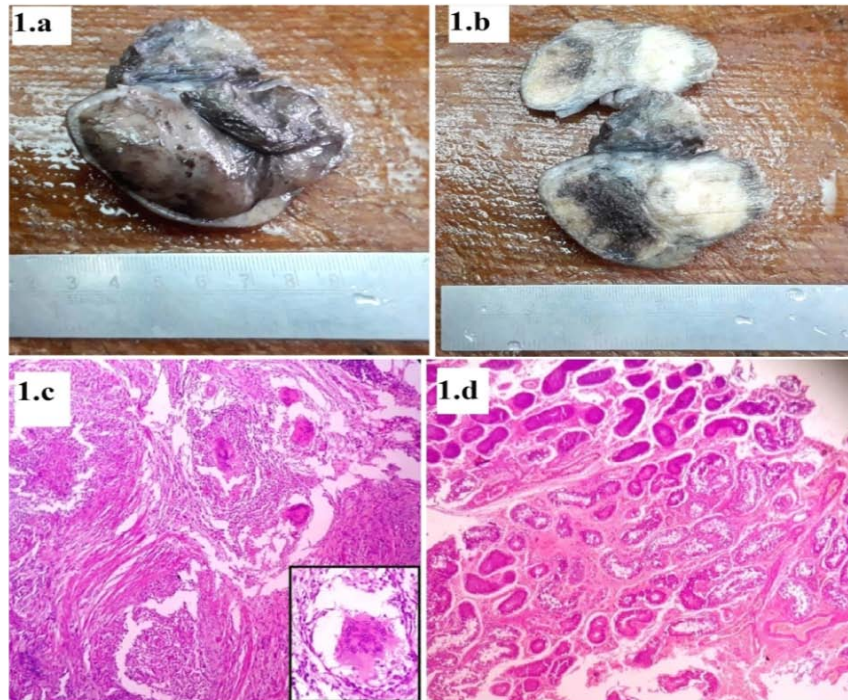


Figure 1.a: shows the gross appearance of the orchidectomy specimen. **Figure 1.b:** the cut surface shows grey-white areas of firm consistency, with adjacent areas of haemorrhage and necrosis, along with admixed viable testicular tissue. **Figure 1.c:** H & E stained histopathological examination shows caseating epithelioid histiocytic granulomas replacing the testicular parenchyma. Surrounding these granulomas, lymphocytes and Langhan's giant cells can be seen. The inset shows a multinucleated histiocytic giant cell at 400x. **Figure 1.d:** shows areas of viable and non-viable testicular tissue due to torsion.

in making a clinical diagnosis [4-6]. The torsion of the testis affects predominantly neonates and adolescent populations. In neonates, torsion is due to a congenital anomaly of the processus vaginalis, which leads to extra-vaginal torsion, while in adolescents, bell-clapper deformity leads to intravaginal torsion (twisting of the spermatic cord within the tunica vaginalis) [3,7].

Other predisposing factors include environmental factors, preceding trauma, and familial inheritance. Cold weather and an overactive cremasteric reflex are two well-known environmental factors. Many studies have established the association between testicular torsion and weather [8-9]. The time from the onset of symptoms to reduction of torsion and the degree of cord twisting are the two most significant factors that determine the outcome in patients with torsion testis [10].

Another study done by Peeraully et al. on emergency scrotal exploration showed the rate of orchidectomy was significantly lower in patients admitted directly to the emergency department compared with those referred from primary health care centers or transferred from other hospitals. These studies highlighted the importance of time duration, which decides the outcome of the affected testis and the impact on patient life afterwards [11]. A study by Mukendi et al. revealed that the left-sided torsion was most frequently noted in individuals, less than 16 years of age, while the right-sided torsion mainly affected individuals, 16 years or older. This study also revealed that the winter season saw the highest number of hospitalizations, as compared to summers [9].

In our case, histo-morphological analysis revealed tubercular

orchitis without epididymal involvement, with accompanying torsion of the right testis. Surprisingly, in the literature, there is no documented study about the association of torsion with tubercular orchitis. M. Cohen et al. found a link between an acute scrotum and concurrent involvement by a testicular tumour and contralateral torsion in a 27-year-old male [12]. In our patient, torsion of the testis with tubercular orchitis was affecting right side of testis, and the contralateral testis was normal.

Many studies reveal resemblance of testicular orchitis with that of a testicular mass. Differential diagnosis of malignancy is always kept in mind by clinicians. Only histopathology, can confirm the correct diagnosis. Hence, these studies signify the crucial role of a pathologist towards the correct diagnosis [13-14]. All age groups of both sexes are affected by tuberculosis, with a significant number occurring in males. The Indian population has a higher rate of tuberculosis than the Chinese population. The most frequent manifestation of extrapulmonary TB is urogenital TB, which is commonly seen in middle-aged males and accounts for 33.7%–45.5% of all extrapulmonary TB globally. The rare subtypes of urogenital tuberculosis include tuberculosis epididymitis, tubercular orchitis, and prostatic tuberculosis [15]. Generally, clinical symptoms of genitourinary tuberculosis manifest after 10-15 years of primary infection [13]. The epididymis is the most commonly affected part, involvement of which occur haematogenously from an infected prostate, and it can also affect the testis. However, isolated involvement of the testis is very uncommon. Edward et al. in their study, found involvement of the epididymis but could not find any primary testicular TB [16].

Early detection of testicular lesions improves the outcome

with less intensive management. The constellation of clinical history, physical examination, radiological examination, and histopathological examination can help in making an early and correct diagnosis. Ultrasound guided fine needle aspiration cytology is an important out-patient tool that provides rapid and accurate diagnosis [13]. Ultrasonography alone doesn't have much weight age as the pattern of torsion on sonography varies from case to case. However, a commonly described pattern of torsion is reduced testicular echogenicity. This pattern is not specific because patients with testicular trauma, tumors, and epididymo-orchitis may exhibit analogous findings [17].

Conclusion

There have been numerous reports of testicular torsion, but a case report of tubercular orchitis without involvement of the epididymis in a patient presenting clinically with torsion testis is exceedingly rare. To the best of our knowledge, a similar presentation of testicular torsion with tubercular orchitis has not been reported in the literature. Hence, this is a very rare incidental histopathological finding, and our case report adds to the literature a rare incidental finding of tubercular orchitis coexisting with torsion testis.

References

1. Naouar S, Braiek S, El Kamel R. Testicular torsion in undescended testis: A persistent challenge. *Asian J Urol.* 2017; 4: 111-15.
2. Hyun GS. Testicular Torsion. *Rev Urol.* 2018; 20: 104-106.
3. Favorito LA, Cavalcante AG, Costa WS. Anatomic aspects of epididymis and tunica vaginalis in patients with testicular torsion. *Int Braz J Urol.* 2004; 30: 420-24.
4. Sharp VJ, Kieran K, Arlen AM. Testicular torsion: diagnosis, evaluation, and management. *Am Fam Physician.* 2013; 88: 835-40.
5. Boettcher M, Bergholz R, Krebs TF, Wenke K, Aronson DC. Clinical predictors of testicular torsion in children. *Urology.* 2012; 79: 670-74.
6. Srinivasan A, Cinman N, Feber KM, Gitlin J, Palmer LS. History and physical examination findings predictive of testicular torsion: an attempt to promote clinical diagnosis by house staff. *J Pediatr Urol.* 2011; 7: 470-74.
7. Witherington R, Jarrell TS. Torsion of the spermatic cord in adults. *J Urol.* 1990; 143: 62-63.
8. Laher A, Ragavan S, Mehta P, Adam A. Testicular Torsion in the Emergency Room: A Review of Detection and Management Strategies. *Open Access Emerg Med.* 2020; 12: 237-246..
9. Mukendi AM, Kruger D, Haffejee M. Characteristics and management of testicular torsion in patients admitted to the Urology Department at Chris Hani Baragwanath Academic Hospital. *Afr J Urol.* 2020; 26.
10. Visser AJ, Heyns CF. Testicular function after torsion of the spermatic cord. *BJU Int.* 2003; 92: 200-3.
11. Peeraully R, Jancauskaite M, Dawes S, Does the source of referral affect outcomes for paediatric testicular torsion?. *Ann R Coll Surg Engl.* 2019; 101: 1-4.
12. Cohen M, Sova Y, Grunwald I, Resnick M, Stein A. A rare simultaneous presentation of testicular mixed germ cell tumor with a contralateral testis torsion. *Urology.* 2000; 55: 590.
13. Dayal S, Kumar A, Singh SP, Verma A. Tuberculous orchitis mimicking a testicular tumor: A diagnostic dilemma. *Asian Pacific Journal of Reproduction.* 2014; 3: 80-2.
14. Paul J, Krishnamoorthy S, Teresa M, Kumar S. Isolated tuberculous orchitis: A mimicker of testicular malignancy. *Indian J Urol.* 2010; 26: 284-6.
15. Huang Y, Chen B, Cao D. Surgical management of tuberculous epididymo-orchitis: a retrospective study of 81 cases with long-term follow-up. *BMC Infect Dis.* 2021; 21: 1068.
16. Keyes Jr EL. Tuberculosis of the testicle: observations upon 100 patients. *Ann Surg.* 1907; 45: 918.
17. Pryor JL, Watson LR, Day DL, Abbitt PL, Howards SS, Gonzalez R. Scrotal ultrasound for evaluation of subacute testicular torsion: sonographic findings and adverse clinical implications. *J Urol.* 1994; 151: 693-7.