

## Case Report

# Onset of Graves' Disease and Thyroid Cancer after Chemo and Radiotherapy for Medulloblastoma

Sapuppo G<sup>1\*</sup>, Tavarelli M<sup>2</sup>, Le Moli R<sup>1</sup>, Masucci R<sup>3</sup> and Pellegriti G<sup>2</sup>

<sup>1</sup>Endocrinology, Department of Clinical and Experimental Medicine, University of Catania, Garibaldi-Nesima Medical Center, Catania, Italy

<sup>2</sup>Department of Endocrinology, Garibaldi-Nesima Medical Center, Italy

<sup>3</sup>Department of Surgical Oncology, Garibaldi-Nesima Medical Center, Italy

\*Corresponding author: Sapuppo Giulia, Endocrinology, Department of Clinical and Experimental Medicine, Garibaldi-Nesima Medical Center, Via Palermo 636, 95122 Catania, Italy

Received: August 03, 2020; Accepted: August 24, 2020; Published: August 31, 2020

## Abstract

**Introduction:** External beam Radiotherapy (RTE) treatment for head and neck cancers is associated to the development of late thyroid sequelae whose risk is persistent for decades.

**Case Report:** We describe a rare case of a 21 yrs woman treated with RTE plus CHE for medulloblastoma diagnosed when she was fourteen. Five years later, for the onset of primitive hypothyroidism, with negative antibodies and a diffuse hypoechoic pattern at ultrasound, she started Levothyroxine (L-T4) therapy. At the annual control visit a small hypoechoic nodule (4mm) to the right thyroid lobe has been detected. Eight months later the patient complained a state of thyrotoxicosis, TRab positive, with thyroid-associated orbitopathy. The nodule was increased in size and suspicious as also a lateral neck Lymph Node (LN). Fine needle aspiration biopsy and Thyroglobulin (Tg) measurement on LN confirmed the diagnosis of thyroid carcinoma. After total thyroidectomy and LN dissection, with histological diagnosis of follicular-papillary microcarcinoma with LN metastasis in central and right latero-cervical compartment, the patient underwent <sup>131</sup>I treatment. Tg was 62pg/ml (after LT4 withdrawal) and whole-body scan showed neck and diffuse bilateral lung uptake.

**Conclusion:** We describe a rare case of a patient who developed autoimmune thyroid disease, hypothyroidism and subsequent Graves' disease with orbitopathy, followed by aggressive thyroid cancer some years later after treatment for medulloblastoma. Only few similar cases were previously described in literature [1]. Thyroid alterations are common during long-term follow-up of patients previously treated with RTE. Therefore a careful long-term follow-up with thyroid morpho-functional screening is indicated.

**Keywords:** Thyroid cancer; Thyroid cancer outcome; Thyroid cancer risk factors; Neck irradiation; Childhood cancer survivor; Graves' orbitopathy

## Case Report

A 19-year-old young woman accessed our clinic for the onset of primary hypothyroidism. Five years before, at the age of 14 years, she was diagnosed with medulloblastoma and treated with surgery, external Radiotherapy (RTE) and Chemotherapy (CHE). At first visit in our Thyroid Clinic, thyroid function revealed a condition of hypothyroidism for which therapy with Levothyroxine (L-T4) has been started; Anti-peroxidase (AbTPO) and Anti-Thyroglobulin (AbTg) antibodies were negative and thyroid ultrasound showed a finely inhomogeneous pattern. At the annual control neck ultrasound showed a small hypoechoic nodule of 4 mm in size in the right thyroid lobe. Eight months later the patient complained of nervousness, sweating, palpitations, fine tremors and moderate and active thyroid-associated orbitopathy (lacrimation, diplopia, Clinical Activity Score (CAS) = 3; NOSPECS: eyelid opening 13 mm bilaterally, Hertel 22 mm on the right and 22 mm on left, moderate decrease of ocular motility in upgaze).

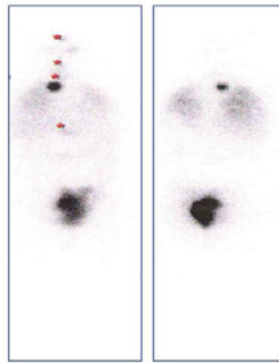
Thyroid function tests confirmed that the patient was in thyrotoxicosis state: TSH 0.08μIU/ml (ref.0.35-5.0), FT4 2.14ng/dl (ref. 0.6-1.8), FT3 6.21pg/mL (ref. 2.3-4.2), with positive anti-TSH Receptor antibodies (TRab) (17 U/ref. <0.5). L-T4 has been

withdrawn and corticosteroids therapy started for orbitopathy. At ultrasound, the right lobe nodule has been increased, from 4mm to 9mm, and presented micro calcifications and irregular margins and furthermore a 9mm Lymph Node (LN) with suspicious features was detected in the right lateral-cervical compartment.

Ultrasound guided fine needle aspiration biopsy of thyroid nodule was suspected for papillary Thyroid Cancer (TC) and Thyroglobulin (Tg) measurement in washout fluid from suspicious LN was positive (>475ng/ml).

The patient underwent total thyroidectomy and LN dissection (central and right latero-cervical compartments) with histological diagnosis of papillary carcinoma of follicular variant (8mm) in the right lobe without capsule or vascular invasion, thyroiditis in the remaining parenchyma, and central (8/10 with a max diameter of 0.4cm) and right latero-cervical (5/36 with a max diameter of 1cm) compartment LN metastases. pT1b pN1b; Stage: I (TNM VIII edition). Whole-body scan after treatment with 100 mCi of <sup>131</sup>I- Iodine, after LT4 withdrawal, showed diffuse bilateral neck and lung uptake (Figure 1); Tg was 62ng/ml with negative AbTg.

Neck ultrasound was negative and CT scan confirmed lung nodular lesions of 3 and 4 mm in size at the upper lobe of the right



**Figure 1:** Whole-body scan (anterior and posterior view) after treatment with 100 mCi of  $^{131}\text{I}$  showing diffuse bilateral neck and lung uptake.

lung.

At the last control visit thyroid, under LT4 treatment, Tg was 3ng/ml. Thyroid-associated orbitopathy was inactivated (lacrimation and diplopia disappeared, CAS 2; NOSPECS: eyelid opening 13 mm bilaterally, Hertel 21 mm bilaterally, ocular motility was unchanged).

## Discussion

Thyroid dysfunction is a relatively frequent late-effect of exposure of the thyroid gland to therapeutic doses of external ionizing irradiation for head and neck cancers [2-5]. Radiotherapy is an integral part of management of childhood and adolescence tumors, particularly head and neck malignancies, alone or in combination with CHE [6]. Although thyroid is considered relatively radio-resistant (but radiosensitive in young age) there is a dose-effect relationship. Direct irradiation of the thyroid gland may produce a broad spectrum of thyroid diseases: hypothyroidism, thyroiditis, Graves' Disease (GD), thyroid-related orbitopathy, thyroid adenoma, multinodular goiter and thyroid carcinoma [7]. The latency interval between radiation exposure and the development of thyroid dysfunction or TC varies greatly ranging from 6 months to 40 years.

Subclinical and overt hypothyroidism are the most common finding in irradiated patients undergone periodic biochemical screening up to 50%, mostly within 5 years from therapy [2-5,7-9]. Moreover CHE would sensitize the thyroid gland to radiation and will increase the incidence of hypothyroidism [6].

Thyrotoxicosis may also develop after external irradiation to the thyroid gland. In a large study of 1787 patients treated for Hodgkin's disease [7] Graves' disease affected 34 patients (1.9%) and half of them developed infiltrative orbitopathy. The risk of GD was significantly increased in this population compared to general populations (relative risk ranging from 7.2 to 20.4).

Furthermore, ionizing radiation is a well documented risk factor for cancer. The thyroid gland is very radiosensitive in young age as shown by the peak of TC observed after the Chernobyl accident. TC risk in children exposed to neck radiation is inversely related to the age of patient at the time of irradiation and to the administered cumulative dose [10]. The TCs observed after irradiation are usually well-differentiated, with a relatively indolent course and are rarely fatal [7,11,12].

The peculiarity of the present case is the short latency between medulloblastoma treatment and the onset of thyroid dysfunction with hypothyroidism switched in hyperthyroidism with orbitopathy followed by appearance of a nodule with rapid increasing and which subsequently revealed a TC.

Hypothyroidism has been reported to develop mostly within 5 years after neck RTE with a mean latency period of 15-21 months [13,14], a similar interval that observed in our patient.

We suppose that her hypothyroidism was a direct consequence of medulloblastoma treatment on thyroid gland due to negative AbTPO and AbTg antibodies.

The pathophysiology of radiation-induced thyroid injury is multifactorial: it alters follicular epithelial function and the endothelium, resulting in cell degeneration, necrosis, follicular destruction and vascular degeneration, acute and chronic inflammation, fibrosis and epithelial regeneration [15,16].

In our patient, one year after beginning L-T4 therapy, was observed a reversal thyroid function with the onset of hyperthyroidism and a thyroid-associated orbitopathy.

Two patterns of TRAb are described, Thyrotropin-Blocking Autoantibodies (TBAb) and Thyroid-Stimulating Autoantibodies (TSAb), able to activate or block TSH receptor functions and responsible for two distinct clinical syndromes. These two types of antibodies (activating and blocking) may be present simultaneously and the overall activity depends on the sum of the two levels activities, concentrations, affinities and potencies [17].

TBAb-induced hypothyroidism should be distinguished from Hashimoto's thyroiditis antibodies one in which thyroid dysfunction depends on chronic inflammation due to massive lymphocytic infiltration. In some cases, a distinction between hypothyroidism caused by Hashimoto's thyroiditis and TBAb-induced hypothyroidism may be difficult, because AbTPO and AbTg antibodies frequently coexist with TRAb.

The switching between TBAb and TSAb (or vice versa) rarely occurs. In a large series of TBAb-induced hypothyroid patients studied for 10 years, Takasu reported that only 5.9% of such patients developed TSAb and became hyperthyroid [18]. This switching occurs in TBAb-positive hypothyroidism patients after LT4 therapy or Graves' patients treated with anti-thyroid drug.

Regarding thyroid-associated orbitopathy, Ringel et al. [19] described the pathogenic role of neck radiation (in patients with Hodgkin's disease) due to damage to thyroid cells with the release of thyroid antigens and consequently an autoimmune thyroid disease and orbitopathy. Patients with Hodgkin's disease had serological evidence of altered immunity against orbital muscle cells antigens and anti-body-dependent cellular cytotoxicity more frequently than controls. This result was statistically significant between patients treated with neck irradiation ( $\pm$  CHE) and controls and not between patients treated with CHE alone.

Regards the pathogenesis of Grave's orbitopathy, the role of TSH Receptor (TSHR) and the TRAb is firmly established [20] in initiating and sustaining orbital tissue remodelling [21]. Some studies report a correlation between levels of TRAb and the severity and activity of

orbitopathy [22-24]. Higher levels of TSHR are found in orbital tissues of patients with active disease [25]. In addition to TSH, other factors have a relevant influence on thyroid tissue growth and function, particularly the Insulin-like Growth Factor (IGF) family [21,26]. Ingbar et al. [27] demonstrated the importance of IGF-1 on TSHR signalling suggesting that, in the rat thyroid epithelial cell line, IGF-1 could enhance cell proliferation and promote the impact of TSH on DNA synthesis; the same effects but less relevant were found for insulin and IGF-II [27,28]. This synergy between TSH and IGF-I has been confirmed in several reports [25,29]. Particularly, the activation of Erk by the signaling downstream from TSHR is dependent on IGF-I receptor activity [30].

Regarding TC, in our patient, a thyroid nodule was clinically evident one year after the onset of hypothyroidism but only 8 months later it showed a considerable increase in size with modified ultrasound features.

An increased frequency and a more aggressive cancer (presentation and outcome) were described in Graves' disease than in euthyroid patients [31-33].

TSAbs and the increased vascularity of the thyroid gland in Graves' patients could be a favouring factor in the initiation/progression of TC and on the onset of cancer metastases. The short latency period from Graves' diagnosis and TC or the simultaneous onset is possibly related to TSAb stimulation on thyroid tissue [17,34].

The clinical evolution of TC can be influenced by TSAbs serum levels, binding characteristics to the TSH receptor, biological effects on thyroid cells and the autoimmune process of GD due "per se" to the alteration of the host immune response to the tumor.

## Conclusion

The present case describes a particular and rare clinical condition characterized by the onset, in a patient subjected to previous RTE and CHE of: 1) primitive hypothyroidism, 2) subsequent hyperthyroidism with orbitopathy and 3) TC with aggressive characteristics. The onset of GD in patients undergoing RTE of the neck has a prevalence of about 5% vs hypothyroidism (prevalence up to 30%). The pathogenesis of hyperthyroidism in these patients is not clear but the auto-antigens released by the damaged thyroid tissue could trigger the autoimmune response and lead to the development of TSH anti-receptor antibodies that could be implicated in thyroid carcinogenesis. The role of CHE in the pathogenesis of thyroid alterations remains to be. This report indicates the need of periodic morpho-functional thyroid evaluation in patients treated with neck RTE and CHE, particularly during childhood or adolescence.

## References

- Jaber JJ, Thomas FJ, Carfrae MJ, Galati LT. Radiotherapy-associated euthyroid Graves ophthalmopathy following floor-of-mouth surgery: a case report. *Ear, Nose & Throat Journal*. 2008; 87: 533-536.
- Hancock SL, McDougall IR, Constine LS. Thyroid abnormalities after therapeutic external radiation. *International journal of radiation oncology, biology, physics*. 1995; 31: 1165-1170.
- Oberfield SE, Allen JC, Pollack J, New MI, Levine LS. Long-term endocrine sequelae after treatment of medulloblastoma: prospective study of growth and thyroid function. *The Journal of pediatrics*. 1986; 108: 219-223.
- Ogilvy-Stuart AL, Clark DJ, Wallace WH, Gibson BE, Stevens RF, Shalet SM, et al. Endocrine deficit after fractionated total body irradiation. *Archives of disease in childhood*. 1992; 67: 1107-1110.
- Tami TA, Gomez P, Parker GS, Gupta MB, Frassica DA. Thyroid dysfunction after radiation therapy in head and neck cancer patients. *American journal of otolaryngology*. 1992; 13: 357-362.
- Banipal R, Mahajan MK, Uppal B, John M. Thyroid diseases as a sequelae following treatment of head and neck cancer. *Indian journal of cancer*. 2011; 48: 194-198.
- Hancock SL, Cox RS, McDougall IR. Thyroid diseases after treatment of Hodgkin's disease. *The New England journal of medicine*. 1991; 325: 599-605.
- Grande C. Hypothyroidism following radiotherapy for head and neck cancer: multivariate analysis of risk factors. *Radiotherapy and oncology: journal of the European Society for Therapeutic Radiology and Oncology*. 1992; 25: 31-36.
- Thomas BC, Stanhope R, Plowman PN, Leiper AD. Endocrine function following single fraction and fractionated total body irradiation for bone marrow transplantation in childhood. *Acta endocrinologica*. 1993; 128: 508-512.
- Ron E, Lubin JH, Shore RE, Mabuchi K, Modan B, Pottern LM, et al. Thyroid cancer after exposure to external radiation: a pooled analysis of seven studies. *Radiation research*. 1995; 141: 259-277.
- Richardson DB. Exposure to ionizing radiation in adulthood and thyroid cancer incidence. *Epidemiology*. 2009; 20: 181-187.
- Black P, Straaten A, Gutjahr P. Secondary thyroid carcinoma after treatment for childhood cancer. *Medical and pediatric oncology*. 1998; 31: 91-95.
- Tell R, Sjodin H, Lundell G, Lewin F, Lewensohn R. Hypothyroidism after external radiotherapy for head and neck cancer. *International journal of radiation oncology, biology, physics*. 1997; 39: 303-308.
- Turner SL, Tiver KW, Boyages SC. Thyroid dysfunction following radiotherapy for head and neck cancer. *International journal of radiation oncology, biology, physics*. 1995; 31: 279-283.
- Goldberg RC, Chaikoff IL, et al. Histopathological changes induced in the normal thyroid and other tissues of the rat by internal radiation with various doses of radioactive iodine. *Endocrinology*. 1950; 46: 72-90.
- Nishiyama K, Tanaka E, Tarui Y, Miyauchi K, Okagawa K. A prospective analysis of subacute thyroid dysfunction after neck irradiation. *International journal of radiation oncology, biology, physics*. 1996; 34: 439-444.
- Orgiazzi J. Anti-TSH receptor antibodies in clinical practice. *Endocrinology and metabolism clinics of North America*. 2000; 29: 339-355.
- Takasu N, Matsushita M. Changes of TSH-Stimulation Blocking Antibody (TSBAb) and Thyroid Stimulating Antibody (TSAb) Over 10 Years in 34 TSBAb-Positive Patients with Hypothyroidism and in 98 TSBAb-Positive Graves' Patients with Hyperthyroidism: Reevaluation of TSBAb and TSAb in TSH-Receptor-Antibody (TRAb)-Positive Patients. *Journal of thyroid research*. 2012; 182176.
- Ringel MD, Taylor T, Barsouk A, Wall JR, Freter CE, Howard RS, et al. Hodgkin's disease treated with neck radiation is associated with increased antibody-dependent cellular cytotoxicity against human extraocular muscle cells. *Thyroid : official journal of the American Thyroid Association*. 1997; 7: 425-432.
- Rapoport B, McLachlan SM. The thyrotropin receptor in Graves' disease. *Thyroid: official journal of the American Thyroid Association*. 2007; 17: 911-922.
- Smith TJ, Hegedus L, Douglas RS. Role of insulin-like growth factor-1 (IGF-1) pathway in the pathogenesis of Graves' orbitopathy. *Best practice & research Clinical endocrinology & metabolism*. 2012; 26: 291-302.
- Gerding MN, van der Meer JW, Broenink M, Bakker O, Wiersinga WM, Prummel MF. Association of thyrotropin receptor antibodies with the clinical features of Graves' ophthalmopathy. *Clinical endocrinology*. 2000; 52: 267-271.
- Eckstein AK, Plicht M, Lax H, Neuhauser M, Mann K, Lederbogen S, et al.

- Thyrotropin receptor autoantibodies are independent risk factors for Graves' ophthalmopathy and help to predict severity and outcome of the disease. *The Journal of clinical endocrinology and metabolism*. 2006; 91: 3464-3470.
24. Lytton SD, Ponto KA, Kanitz M, Matheis N, Kohn LD, Kahaly GJ. A novel thyroid stimulating immunoglobulin bioassay is a functional indicator of activity and severity of Graves' orbitopathy. *The Journal of clinical endocrinology and metabolism*. 2010; 95: 2123-2131.
25. Tsui S, Naik V, Hoa N, Hwang CJ, Afifyan NF, Sinha Hikim A, et al. Evidence for an association between thyroid-stimulating hormone and insulin-like growth factor 1 receptors: a tale of two antigens implicated in Graves' disease. *Journal of immunology*. 2008; 181: 4397-4405.
26. Smith TJ. Insulin-like growth factor-I regulation of immune function: a potential therapeutic target in autoimmune diseases? *Pharmacological reviews*. 2010; 62: 199-236.
27. Tramontano D, Cushing GW, Moses AC, Ingbar SH. Insulin-like growth factor-I stimulates the growth of rat thyroid cells in culture and synergizes the stimulation of DNA synthesis induced by TSH and Graves'-IgG. *Endocrinology*. 1986; 119: 940-942.
28. Maciel RM, Moses AC, Villone G, Tramontano D, Ingbar SH. Demonstration of the production and physiological role of insulin-like growth factor II in rat thyroid follicular cells in culture. *The Journal of clinical investigation*. 1988; 82: 1546-1553.
29. Krieger CC, Perry JD, Morgan SJ, Kahaly GJ, Gershengorn MC. TSH/IGF-1 Receptor Cross-Talk Rapidly Activates Extracellular Signal-Regulated Kinases in Multiple Cell Types. *Endocrinology*. 2017; 158: 3676-3683.
30. Smith TJ. New advances in understanding thyroid-associated ophthalmopathy and the potential role for insulin-like growth factor-I receptor. *F1000Research*. 2018; 7: 134.
31. Mazzaferri EL. Thyroid cancer and Graves' disease. *The Journal of clinical endocrinology and metabolism*. 1990; 70: 826-829.
32. Belfiore A, Garofalo MR, Giuffrida D, Runello F, Filetti S, Fiumara A, et al. Increased aggressiveness of thyroid cancer in patients with Graves' disease. *The Journal of clinical endocrinology and metabolism*. 1990; 70: 830-835.
33. Pellegriti G, Mannarino C, Russo M, Terranova R, Marturano I, Vigneri R, et al. Increased mortality in patients with differentiated thyroid cancer associated with Graves' disease. *The Journal of clinical endocrinology and metabolism*. 2013; 98: 1014-1021.
34. Belfiore A, Pellegriti G, Milone G, Vigneri G, Gangemi P, Fiumara A, et al. Early occurrence of a thyroid carcinoma in a patient who developed Graves' disease after treatment for Hodgkin's disease. *Journal of Endocrinological Investigation*. 1995; 18: 869-871.