

Research Article

Prevalence of Sub - Clinical Hypothyroidism in Cases of Fissure-In-Ano at a Tertiary Care Centre

Pradeep Balineni*, Sarvana Sundaram SN, Ann Rhoda Abraham, Shifa Zareena, Sivaram Sridharan and Shruthi Kamal

Department of Surgery, Saveetha University, India

*Corresponding author: Pradeep Balineni, Department of Surgery, Saveetha Medical College, Saveetha University, Address: Plot no 112, Revenue Colony, MM Donka, Near SSN Degree College, Ongole, Prakasam District, Andhra Pradesh, 523002, India

Received: May 25, 2020; Accepted: June 24, 2020;

Published: July 01, 2020

Abstract

Background: Fissure in ano is common proctologic condition. Fissure in ano is common condition which affects young and middle aged people with an equal incidence in males and females [12,13,14] The effect of hypothyroidism on gastrointestinal system seems to be multifactorial with alterations of the hormone receptors, neuro-muscular disorders and myopathy by infiltrating the intestinal wall [7,8]. Aim of the study is to look for the prevalence of hypothyroidism in cases of fissure in ano.

Methods: This is a retrospective observational study done at Saveetha Medical Hospital from January 2016 to December 2018. All the medical records were pursued to retrieve the entire fissure in ano cases. We included all the cases of fissure in ano with a thyroid profile, excluding those patients who were on any medication or conditions which affect the values of thyroid profile.

Results: Study was conducted over 59 patients. Most of the patients are middle aged (61%) with slight male predominance (55.9%), and painful defecation was the main complaint (47.5%). 52.5% of the patients are hypothyroid with a significant two tailed P value of 0.0092.

Conclusion: Although the Aetiology of this disease remains unclear, many studies hypothesize that hypertonia and the spasm of the internal anal muscular fibres are the main pathologies. We conclude this study by stating that there is increased prevalence of hypothyroidism in fissure in ano cases, and hypothyroidism might be a risk factor for fissure in ano, in view of the effects of thyroxine which cause myopathy and vasodilation.

Keywords: Fissure in ano; Hypothyroidism; Prevalence; Etiology; Lateral anal spinctherotomy

Abbreviations

SNG: Solitary Nodular Goitre; MNG: Multi Nodular Goitre; LAS: Lateral Anal Sphincterotomy

Introduction

Fissure in ano is a common proctologic condition characterized by a linear tear starting just below the dentate line up to the anal verge [1]. This condition was first described by Lockhart-Mummery in 1934 [2,3]. Exact etiology of fissure in ano is not known, whereas persistent hypertonia and spasm of the internal sphincter fibers are believed to be the chief pathologies [3-5]. Patients mainly present with complaints of severe pain and bleeding. Fissure in ano is mostly noticed in the posterior mid-line, with about 10% in the anterior location [1,4-6].

Several studies showed an association between fissure in ano and increased internal anal sphincter pressure, where in hypothyroidism might also be a cause for increased internal sphincter pressure due to the delayed relaxation effect. The effect of hypothyroidism on gastrointestinal system seems to be multifactorial with alterations of the hormone receptors, neuro-muscular disorders and myopathy by infiltrating the intestinal wall [7,8]. Hypothyroidism is a condition where the circulatory levels of thyroid hormone are decreased (or)

there will be a generalized resistance to circulatory level of TH. Hypothyroidism is a common disorder; more prevalent among females with yearly 350/100,000 new cases are being diagnosed of hypothyroidism [9,10]. Hypothyroidism is marked by slowing down of all the metabolic process. The treatment for hypothyroidism would be supplementation of levothyroxine.

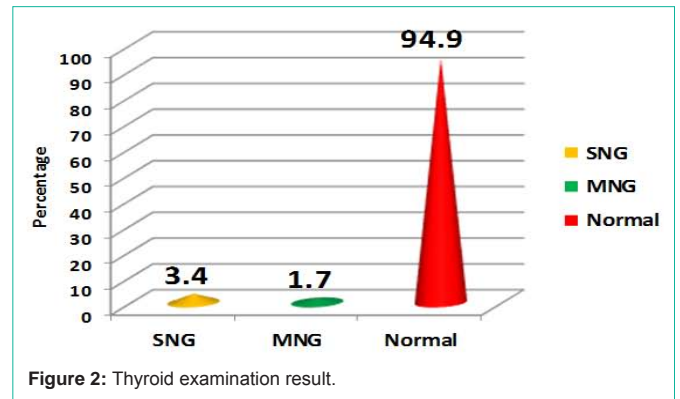
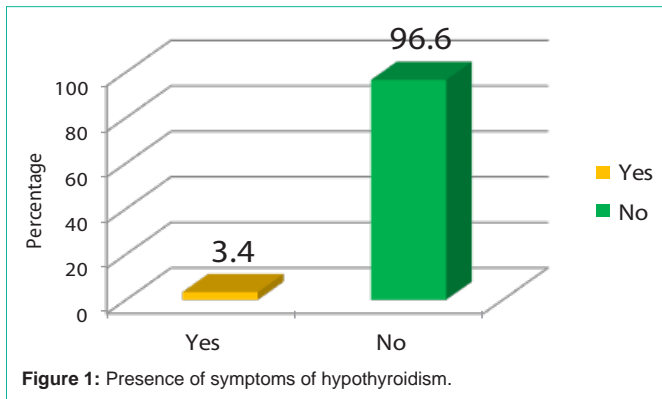
Aims and Objective

- 1) To look for prevalence of hypothyroidism in fissure in ano cases.
- 2) To check T3, T4, TSH values in fissure in ano patients.

Materials and Methods

This is an observational study done at Saveetha Medical Hospital from January 2016 to December 2018. We included all patients who are diagnosed of fissure in ano, excluding those patients who are on medication and conditions that affect T3, T4, TSH values like pregnancy, treated thyroid abnormalities, total thyroidectomy patients, cholangitis, sepsis, phenytoin, carbamazepine, lithium, amiodarone, and metoclopramide [11].

Consent was obtained from the Dean of the institute and institutional ethical committee for publication of the data. Data



were analyzed by one way analysis of variants (student T-test). Data collection sheets were filled in by the investigator himself.

Results

A retrospective observational study was performed to determine the prevalence of hypothyroidism in cases of fissure in ano. 59 patients were studied who fulfilled the inclusion criteria. All the patients were taken from Saveetha Medical College, Chennai from 2016 January to 2018 December.

In this study majority of patients were between the age of 30-50 years 61%, with 30.5% of patients were more than 50 years and 8.5% of patients were less than 30 years. There was a slight predominance of male patients 55.9% and 44.1% of patients were females in the study. There was Only 2 cases that is 3.4% of patients had symptoms related to hypothyroidism (Figure 1). 56 (94.9%) patients had normal thyroid examination result clinically, 2 cases (3.4%) had Solitary Nodular Goiter (SNG) and 1 case (1.7%) had multi nodular goiter on examination (Figure 2). All the patients were treated with L-Thyroxine supplementation. Out of the total 59 participants Majority of patients that is 54 has underwent Lateral Anal Sphincterotomy (LAS) procedure (91.53%), 5 patients (8.47%) has underwent non operative management that is diltiazem ointment (calcium channel blocker) local application due to the risk prone with anesthesia as all the cases are hypothyroid and co-morbid (Table 1&2).

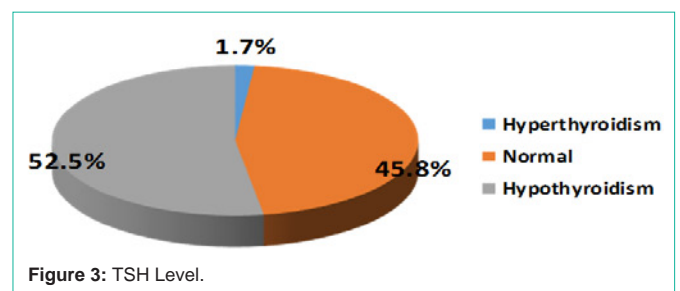


Table 1: Results.

		No. of cases	Percentage
Age	<30 years	5	8.5%
	30-50 years	36	61%
	> 50 years	18	30.5%
Sex	male	33	55.9%
	female	26	44.1%
Presence of hypothyroid symptoms	Yes	2	3.4%
	No	57	96.6%
Co-morbidities	DM	6	10.5%
	HTN	7	11.9%
	Nil	46	77.6%
Thyroid examination	SNG	2	3.4%
	MNG	1	1.7%
	Nil	56	94.9%
TSH Level (0.46-4.68)	Hyperthyroidism	1	1.7%
	Normal	27	45.8%
	Hypothyroidism	31	52.5%

The normal values of thyroid profile in our institution are T3 (2.77 – 5.27 pg/ml), T4 (0.78 – 2.19 ng/dl), TSH (0.46 – 4.68 mlu/ml).

Discussion

Fissure in ano is common condition affecting mostly middle aged

Table 2: Thyroid profile.

	Min	Q1	Median	Q3	Max
TSH	0.321	2.16	5.28	6.94	10.45
T3	2.04	2.87	3.42	3.98	5.22
T4	0.69	1.04	1.52	1.83	2.51

and young aged people [12-14]. In this study we also found a similar finding with 41 cases, age being less than 50 years. Studies show that there is an equal incidence in males and females [12,14] whereas we had a slight male preponderance (55.9%), which might be due to more attendance of the male patients in our hospital.

Fissure in ano can be classified as acute and chronic or primary and secondary [1,4,6]. Chronic fissure in ano is characterized by sentinel pile, hypertrophic anal papillae, anal spasms and/or fibrosis of the internal sphincter muscle [4,5] whereas; acute cases have fresh mucosal edges. Primary fissure in ano are essentially benign might be due to constipation, hard stools repeated trauma due to diarrhoea, poor anal hygiene, vaginal delivery [6]. Constipation is the most frequent gastrointestinal complaint in cases of hypothyroid [15,16] due reduction of peristalsis or higher threshold for rectal sensation and diminished maximal tolerable volume as demonstrate by Deen et al. [17], which might cause a primary fissure in ano in cases of hypothyroid individuals. On contrary diarrhoea might also be the cause of fissure in ano in cases of hypothyroid individuals, where there will be an increased bacterial growth secondary to hypo motility of the gut causing diarrhoea [8,10]. Secondary fissure may be due to Crohn's disease, tuberculosis, malignancy, infections like HIV or Syphilis or herpes [2,6].

The main pathophysiology of fissure in ano is hypertonia and spasm of the internal anal sphincter causing elevated pressure which will lead to decreased blood supply and ischemia causing poor healing of the fissure [1,3,4,18]. There is an increased chance of elevated internal sphincter pressure and decreased vascular supply in cases of hypothyroid individuals because of the delayed relaxation of the sphincter fibres and due to the decreased vaso-relaxation effect of thyroid hormones over the vascular smooth muscles [19,20]. This theory can be further strengthened by the reports of Kocher-Debre and Semelaigne who described association of delayed muscle relaxation in cases of two athyrotic cretins [21,22], and also by reports of Hoffman, in 1897 reported an adult who developed stiffness and difficulty in relaxation of muscles with typical myotonic response after thyroidectomy [23]. Our study also supports the increased incidence of fissure in ano in cases of hypothyroid individuals with a incidence of 52.5% in hypothyroid patients with a significant two tailed P value of 0.0092. Other possible theories for fissure in ano are elliptical arrangement of the external sphincter posteriorly; relative ischemia of the posterior commissure of the anal canal, there may also be contusion of the blood vessels passing vertically through the internal sphincter muscle in the posterior midline, leading to compromise the blood supply with increased anal tone [3].

The common presentation of fissure in ano is sharp anal pain during defecation, which is associated with the passage of bright red blood per rectum [2], in our study we had similar finding with pain being the major presenting complaint in 28 cases (47.5%), followed bleeding per rectum in 21 cases (35.6%).

They are most commonly treated by surgical lateral internal anal sphincterotomy [1,4,18], other modalities of treatment used to treat are non-surgically fibre diet, sitz bath, topical nitrates, calcium channel blockers, botulin toxin injections and surgical are anal dilatation, advancement flaps and fissurectomy [3,18]. In our study majority of the patients had underwent surgical treatment that is lateral internal spintcherotomy in 54 patients (91.53%) and 5 patients (8.47) had underwent spintcherotomy (calcium channel blocker) local application [24].

Conclusion

Before concluding we would like to emphasize that there is no published material available over this title in the English literature and this would be the first study to be conducted over this title. This study is concluded by stating the findings that there is an increased prevalence of hypothyroidism in cases of fissure in ano, and hypothyroidism might be a risk factor for fissure in ano, in view of the effects of thyroxine which cause myopathy and vasodilation. And patient with risk of developing fissure in ano might be benefited by getting treated for hypothyroidism. Clinicians, treating fissure in ano should be aware of the hypothyroid history of the patient, and should check for the thyroid profile as a routine workup. We would like to make the following recommendations based on the findings of this study

- Evaluation of thyroid profile in cases of fissure in ano should be a routine workup.
- Proper evaluation and pre-op work up of hypothyroidism should be done to avoid anesthetic complications.
- Patients with high TSH value should be treated with proper medications for hypothyroidism

Limitations of this study are that this study is carried out over for a limited time over a limited number of patients with financial and infrastructural constraints. All the findings and facts that are quoted in the study may vary from a large study covering wider range of aspects and variables. The follow up period for the patients are shorter hence recurrence and effect of thyroxine and recurrence in patients can't be studied. But, as the study is conducted in a tertiary hospital of our country with a reasonable number of patients this study may have some credential over the facts regarding prevalence of hypothyroidism in cases of fissure in ano.

References

1. Zaghayan KN, Fleshner P. Anal fissure. Clinics in colon and rectal surgery. 2011; 24: 22-30.
2. Beaty JS, Shashidharan M. Anal Fissure. Clinics in colon and rectal surgery. 2016; 29: 30-37.
3. McCallion K, Gardiner KR. Progress in the understanding and treatment of chronic anal fissure. Postgraduate Medical Journal. 2001; 77: 753-758.
4. Babu SM, Gupta R, Singh L. Effectiveness of conservative management of acute fissure in ano: a prospective clinical study of 165 patients. Int Surg J. 2017; 4: 3028-3033.
5. Poh A, Tan KY, Seow-Choen F. Innovations in chronic anal fissure treatment: A systematic review. World journal of gastrointestinal surgery. 2010; 2: 231-241.
6. Schlichtemeier S, Engel A. Anal fissure. Australian prescriber. 2016; 39: 14-17.

7. Ernesto Cristiano Lauritano, Anna Lisa Bilotta, Maurizio Gabrielli, Emidio Scarpellini, Andrea Lupascu, Antonio Laginestra, et al. Association between Hypothyroidism and Small Intestinal Bacterial Overgrowth. *The Journal of Clinical Endocrinology & Metabolism*. 2007; 92: 4180–4184.
8. Daher R, Yazbeck T, Jaoude JB, Abboud B. Consequences of dysthyroidism on the digestive tract and viscera. *World journal of gastroenterology*. 2009; 15: 2834–2838.
9. Unnikrishnan AG, Kalra S, Sahay RK, Bantwal G, John M, Tewari N. Prevalence of hypothyroidism in adults: An epidemiological study in eight cities of India. *Indian journal of endocrinology and metabolism*. 2013; 17: 647–652.
10. Sweet C, Sharma A, Lipscomb G. Recurrent nausea, vomiting and abdominal pain due to hypothyroidism. *BMJ case reports*. 2010.
11. Koulouri O, Moran C, Halsall D, Chatterjee K, Gurnell M. Pitfalls in the measurement and interpretation of thyroid function tests. *Best practice & research Clinical endocrinology & metabolism*. 2013; 27: 745–762.
12. Popat A, Pandey CP, Agarwal K, Srivastava VP, Sharma SM, Dixit A. A comparative study of role of topical diltiazem 2% organo gel and lateral internal sphincterotomy for the management of chronic fissure in ano. *Int J Contemporary Med Res*. 2016; 3: 1363-1365.
13. Killedar M, Kulkarni SH, Maharaul HH, Alka Gore. Efficacy of New Grading System (MK Grading) for Management of Fissure-in-Ano. *Indian J Surg*. 2018; 80: 586-591.
14. Varadarajan MS, Sony PS, Anandan H. Prevalence and Clinical Presentation of Fissure-in-ANO in A Tertiary Care Centre. *Int J Sci Stud*. 2018; 5: 70-72.
15. Meytes V, Schulberg SP, Morin N, Glinik G. Undiagnosed hypothyroidism presenting with sigmoid volvulus. *Journal of surgical case reports*. 2016.
16. Bennett WE, Heuckeroth RO. Hypothyroidism is a rare cause of isolated constipation. *Journal of pediatric gastroenterology and nutrition*. 2012; 54: 285–287.
17. Deen KI, Premaratna R, Fonseka MM, DeSilva HJ. The recto-anal inhibitory reflex: abnormal response in diabetics suggests an intrinsic neuropathy. *J Gastroenterol Hepatol*. 1998; 13: 1107–1110.
18. Madalinski MH. Identifying the best therapy for chronic anal fissure. *World journal of gastrointestinal pharmacology and therapeutics*. 2011; 2: 9–16.
19. Kaie Ojamaa, John D. Klemperer, Klein. Acute Effects of Thyroid Hormone on Vascular Smooth Muscle. *Thyroid*. 1996.
20. Mizuma H, Murakami M, Mori M. Thyroid hormone activation in human vascular smooth muscle cells: expression of type II iodothyronine deiodinase. *Circ Res*. 2001; 88: 313–318.
21. Panat SR, Jha PC, Chinnannavar SN, Chakarvarty A, Aggarwal A. Kocher debre semelaigne syndrome: a rare case report with orofacial manifestations. *Oman medical journal*. 2013; 28: 128–130.
22. Kung AW, Ma JT, Yu YL, Wang CC, Woo EK, Lam KS, et al. Myopathy in acute hypothyroidism. *Postgrad Med J*. 1987; 63: 661–663.
23. Mangaraj S, Sethy G. Hoffman's syndrome - A rare facet of hypothyroid myopathy. *Journal of neurosciences in rural practice*. 2014; 5: 447–448.
24. McAninch EA, Bianco AC. The History and Future of Treatment of Hypothyroidism. *Ann Intern Med*. 2016; 164: 50–56.