

Special Article - Adenoma

Combined Supra-Infrasellar Approach for Giant Pituitary Tumors; A 30-Year Experience

Loyo-Varela M¹, Revilla-Pacheco F², Herrada-Pineda T² and Salvador Manrique-Guzmán^{2,3,4,*}

¹Department of Neurosurgery, ABC Medical Center, Mexico, Calle Sur 136-116 Office 2-B, Mexico City, ZC 01120

²Department of Neurosurgery, ABC Neurological Center, ABC Medical Center, Mexico, Calle Sur 136-116 Office 2-B, Mexico City, ZC 01120

³Department of Neurosurgery, Hospital General "Dr. Fernando Quiroz", ISSSTE, Felipe Ángeles y Canario, Bellavista, ZC 01140 Álvaro Obregón, Mexico City, Mexico

⁴Department of Neurosurgery, Hospital San Ángel Inn Patriotismo, Avenida Patriotismo 67, Colonia San Juan ZC 03730, Mexico City, Mexico

*Corresponding author: Salvador Manrique-Guzman, Department of Neurosurgery, ABC Medical Center, Mexico, Calle Sur 136-116 Office 2-B, Mexico City, ZC 01120, Mexico

Received: September 09, 2019; Accepted: September 28, 2019; Published: October 05, 2019

Abstract

Background: Choosing a surgical treatment method for giant pituitary tumors has always been a challenge and a simultaneous approach was previously described by this team as an alternative for a quick mass effect resolution, visual pathway decompression, and hormonal stabilization.

Objective: This paper aims to describe the experience of the combined approach of 46 cases in a 30-year period.

Methods: We retrospectively reviewed 46 consecutive patients who had undergone surgery using a combined supra-infrasellar approach for adenoma in a 30-year period (1977-2007). Information was collected from electronic records, deidentified, and included age, sex, tumor dimension and extent of resection, comorbidities, complications, and follow-up data. A $p < 0.05$ will be considered statistically significant. Statistical analysis was performed in R.

Results: The population comprises 46 adults of whom 70% were men. The frequency of brain edema after surgery was higher in men ($p = 0.03$), and women had a higher frequency of cranial nerve palsy ($p = 0.02$). Most patients underwent a transcranial approach for tumor resection and frequencies of tumors in Knosp grades I, II, III, and IV were 30%, 41%, 24%, and 4%, respectively. There were no clinical aspects associated with CSF leakage and mortality.

Conclusion: The combined approach should be considered in tumors with suprasellar invasion to facilitate the supra/intra manipulation with visual confirmation of chiasma decompression. For residual tumor, radiotherapy and/or radiosurgery must be considered.

Keywords: MeSH; Pituitary neoplasms; Cranial surgery; Transsphenoidal surgery; Combined approach

Abbreviations

CN: Cranial Nerve; TSS: Transseptal Transsphenoidal; KPS: Karnofsky Performance Score; CFS: Cerebrospinal Fluid Leakage; T2DM: Type 2 Diabetes

Introduction

Surgical treatment for pituitary adenomas has always represented a surgical challenge, since the first attempts of Sir Victor Horsley, father of British neurosurgery, using transcranial corridor with antiseptic dressing before surgery to innovators like Scholoffer, Kocher and Harvey Cushing [1-3]. In 1910, Oskar Hirsch performed the first complete endonasal Trans Septal Trans Sphenoidal (TSS) approach that was abandoned mainly because of the inadequate illumination of the surgical field allowed by the surgical instruments of that time [4]. Norman Dott, Cushing's fellow, continued using the TSS approach, despite his master's disposition allowing the French neurosurgeon Gerard Guiot to add the intraoperative fluoroscopy [1]. Guiot also introduced the endoscope at the end of the surgery to explore the pituitary fossa [5].

Pituitary neoplasm represents between 10-15% of all central nervous system tumors, autopsy reports confirm that it occurs in approximately 1-35% of the general population [3,4]. Symptomatic

pituitary neoplasms have a prevalence of 80-90 per 100,000 [4]. Prolactinomas represent the most commonly diagnosed secreting adenoma (35%), gonadotrophic adenomas (35%), corticotrophic and somatotrophic adenomas (10-15% respectively) and thyrotrophic adenomas (2%) [6].

Currently, trans sphenoidal surgery is the approach of choice for over 90% of pituitary tumors, but still, transcranial operations are needed for large or asymmetrical tumors with an indistinctive intrasellar component. The goal of surgical treatment is a quick mass effect resolution, visual pathway decompression, and hormonal stabilization. Multiple factors influence the decision of the surgical approach, like tumor size, extension, configuration, and hormonal oversecretion. Simultaneous approach is logistically complex requiring two sets of surgical teams, surgical instruments (including a microscope, microdissector, etc) and staff. Large adenomas with hourglass constriction, complex lobulation, and asymmetric extension are the main indications for a simultaneous approach [7]. The senior author previously described this approach in 1984, since then, a total of 46 cases were meticulously reviewed and records were analyzed [8,9].

Materials and Methods

We retrospectively reviewed 46 consecutive patients from the

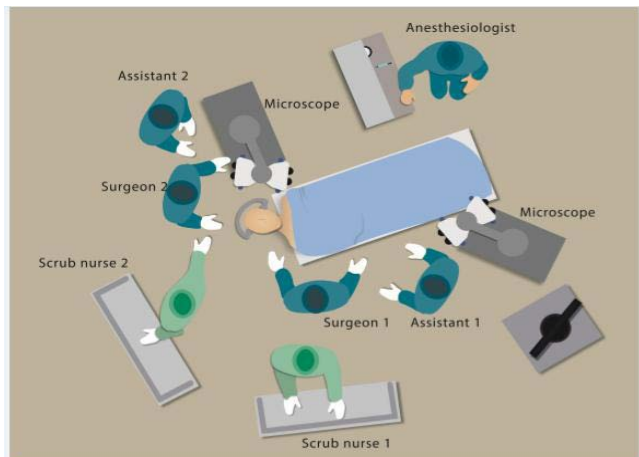


Figure 1: Two surgical teams are required for this combined approach, one for the trans sphenoidal route and the other for the transcranial approach. Each team is composed of a surgeon, assistant and scrub nurse. Two surgical microscopes are placed at the left side of the patient.

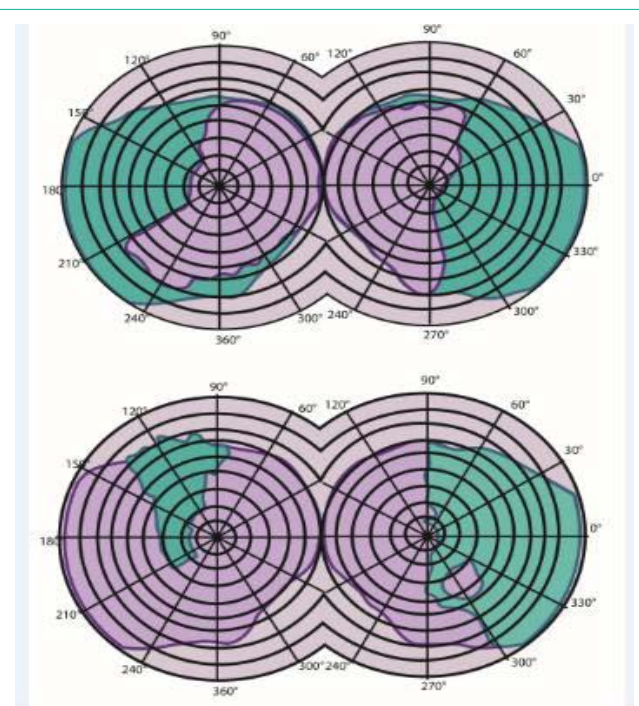


Figure 2: Visual field test before (top) and after (bottom) the surgery with the classic bitemporal hemianopsia due to optic chiasm compression.

same Institution who had undergone surgery using combined supra-infrasellar approach for adenoma in a 30-year period (1977-2007). All epidemiological, biochemical and surgical information was obtained from the personal notes from the senior authors. Since this was a retrospective review using personal medical notes, no patient consent or ethics committee approval was obtained. Individual patient consents were not sought, as this was a descriptive retrospective study with all data anonymized. Information was collected from electronic records, deidentified, and included age, sex, tumor dimension and extent of resection, comorbidities, complications, and follow-up data.

The surgical technique of the simultaneous combined supra-infrasellar approach has been described previously [8]. All patients have Hardy Vezina class IV-E [10]. Transcranial approaches were as follows: pterional (43 cases), orbito-zygomatic (2 cases), and subfrontal (1 case). On magnetic resonance imaging, all adenomas were macro adenomas with massive suprasellar extension with multilobulated configuration. This approach required 2 operative fields, 2 surgical microscopes, and 2 surgical teams. The trans sphenoidal team position is in the patient's right side. The two procedures usually meet each other at the suprasellar region under direct microscopic view Figure 1.

Clinical data

Clinical data was collected retrospectively from the electronic chart of patients treated within the study period (n= 46). Age, sex, Karnofsky Performance Score (KPS) at the time of diagnosis and after surgery, tumor location, preoperative and postoperative tumor size was measured and follow-up was up to 10 years. The extent of resection was determined based on a postoperative MRI performed <72 hours after surgery, except for the first 5 cases that MRI technology was still not available in Mexico and contrast-enhanced CT were obtained. Gross total resection was defined as no residual tumor enhancement on MRI, while subtotal resection was defined as residual nodular enhancement on MRI. The postoperative MRI scan was acquired in the first 72 hours following the surgery. All patients had non-functional and no other secreting tumors were biochemically identified. Campimetry impairment was present in all cases Figure 2.

Statistical analysis

The database was maintained in Microsoft Excel (Microsoft Corporation, Redmond, Washington). Categorical data are presented as frequencies and corresponding percentages, while continuous data are presented as median and range. The X² test will be used to assess differences between qualitative variables. Mann-Whitney U test was used for assessing differences between non-parametric variables for 2 independent samples. A p<0.05 will be considered statistically significant. Statistical analysis was performed in R statistical software (R version 3.5.1 (2018-07-02) -- "Feather Spray" Copyright (C) 2018 The R Foundation for Statistical Computing Platform: x86_64-apple-darwin15.6.0 (64-bit)).

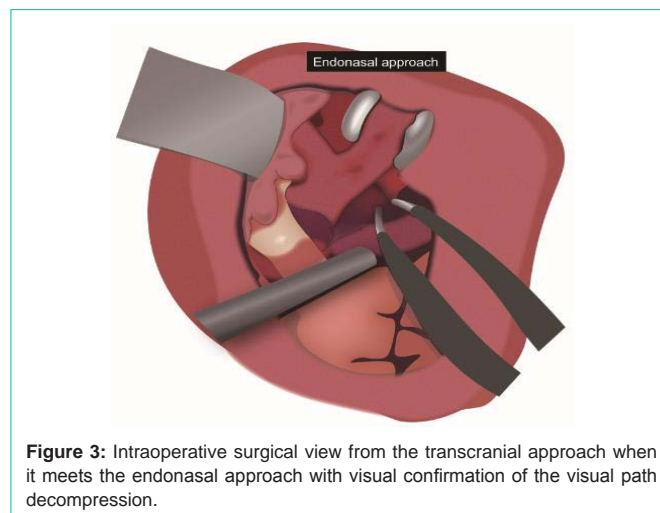


Figure 3: Intraoperative surgical view from the transcranial approach when it meets the endonasal approach with visual confirmation of the visual path decompression.

Table 1: Characteristics by sex.

	Men (n=32)	Women (n=14)	P
Age, years	45.1±10.7	42.2±7.2	0.18
Hypertension, %	63%	64%	0.45
Type 2 diabetes, %	25%	7%	0.08
Smoking, %	28%	0	0.01
Preoperative KPS score	92.2±7.5	94.3±5.1	0.17
Postoperative KPS score	90.9±8.2	93.6±6.3	0.15
P	0.02	0.17	
Tumor size, mm	43.3±13.9	41.6±14.2	0.36
CSF leak, %	6%	0	0.17
Brain edema, %	22%	0	0.03
Early DI, %	16%	7%	0.22
Permanent DI, %	3%	0	0.25
Mortality, %	13%	0	0.08
Complete tumor resection, %	78%	86%	0.28
Cranial nerve palsy, %	16%	43%	0.02

Abbreviations: KPS: Karnofsky Performance Scale; CSF: Cerebrospinal Fluid; DI: Diabetes Insipidus. p†: Between groups Student’s t-test or chi² as appropriate; p‡: Preoperative versus postoperative paired t-test.

Table 2: Factors associated with pre- and postoperative scores in the Karnofsky Performance Scale.

	R ²	Beta	p	CI 95%	
Preoperative KPS					
Age	0.13	-0.25	0.01	-0.45	-0.05
Hypertension	0.02	-2.05	0.34	-6.29	2.19
Type 2 diabetes	0.08	-4.89	0.06	-9.89	0.10
Smoking	0.001	0.63	0.81	-4.58	5.84
Tumor size	0.01	0.04	0.55	-0.11	0.20
Knosp grade	0.02	1.27	0.35	-1.29	3.55
CSF leak	0.16	-13.40	0.006	-22.70	-4.12
Brain edema	0.20	-8.39	0.002	-13.55	-3.22
Early diabetes insipidus	0.12	-7.08	0.02	-12.84	-1.33
Permanent diabetes insipidus	0.08	-13.11	0.06	-26.73	0.50
Cranial nerve palsy	0.05	3.45	0.15	-1.28	8.19
Postoperative KPS					
Age	0.15	-0.31	0.008	-0.53	-0.09
Hypertension	0.03	-2.84	0.23	-7.55	1.87
Type 2 diabetes	0.07	-4.92	0.09	-10.55	0.70
Smoking	0.002	-0.78	0.79	-6.60	5.04
Tumor size	0.002	-0.02	0.79	-0.19	0.15
Knosp grade	0.0001	-0.05	0.97	-2.78	2.67
CSF leak	0.11	-12.27	0.03	-22.87	-1.57
Brain edema	0.24	-10.48	0.0001	-16.07	-4.89
Early diabetes insipidus	0.12	-7.75	0.02	-14.19	-1.31
Permanent diabetes insipidus	0.05	-12	0.12	-27.42	3.42
Cranial nerve palsy	0.005	1.30	0.63	-4.10	6.70

Abbreviations: KPS: Karnofsky Performance Scale; CSF: Cerebrospinal Fluid

Results

The population comprises 46 adults with a median age of 45 years (Interquartile range 40-49 years), of whom 70% were men. Table 1 shows clinical characteristics according to sex. There were 28% of smokers in the male group, with no female smokers. The frequency of brain edema after surgery was higher in men (p=0.03), and women had a higher frequency of Cranial Nerve (CN) palsy (p=0.02). Interestingly, Karnofsky Performance Score (KPS) improved significantly only in men (p=0.02). Table 2 Most patients underwent a transcranial approach for tumor resection and frequencies of tumors in Knosp grades I, II, III, and IV were 30%, 41%, 24%, and 4%, respectively.

Factors negatively associated with pre- and postoperative KPS were age (p=0.01 and 0.008), Cerebrospinal Fluid (CSF) leakage (p=0.006 and 0.03), brain edema (p=0.002 and 0.0001), and early diabetes insipidus (p=0.02 and 0.02), respectively Table 3. Both CSF and early diabetes insipidus predicted pre- and post-surgical KPS score. When looking at the association of clinical variables with CSF leak, brain edema, CN palsy, and mortality, Type 2 Diabetes (T2DM) and smoking were associated with brain edema, and tumor size and Knosp grade were associated with CN palsy Table 4. There were no clinical aspects related to CSF leakage and mortality. Age and smoking predicted brain edema (R²=0.67), and Knosp grade predicted CN palsy (R²=0.63) Table 5.

Discussion

The combined approach may not be useful for most cases. The advantages include a one-time entry to the operating room, visual confirmation of decompression of the optic nerves and chiasm, the ability to manage complex fibrous tumors with parasellar involvement by compensating blind areas. Disadvantages include the need for two complete operating staff, increased CSF leak and potential infection from the sinuses, but there has been no documented evidence of increased infection rate for contamination of the craniotomy by bacteria from the sinuses or the oronasopharynx or an increased risk of postoperative spinal fluid leaks (CFS).

Lesions located in the middle fossa are ideal for a transsylvian approach. In the senior experience, the surgical endoscope was still not introduced to either technique, this allows a great area of opportunity

Table 3: Predictors of pre- and postoperative scores in the Karnofsky Performance Scale.

	R ²	Beta	p	CI 95%	
Preoperative KPS					
	0.45				
Age		-0.10	0.33	-0.30	0.10
CSF leak		-15.36	0.001	-23.18	-7.54
Brain edema		-6.43	0.02	-11.65	-1.21
Early diabetes insipidus		-4.03	0.14	-9.39	1.34
Postoperative KPS					
	0.44				
Age		-0.12	0.30	-0.35	0.11
CSF leak		-14.55	0.002	-23.43	-5.67
Brain edema		-8.34	0.007	-14.27	-2.42
Early diabetes insipidus		-3.63	0.24	-9.72	2.46

Table 4: Factors associated with CSF leak, brain edema, CN palsy, and mortality.

	R ²	OR	p	CI 95%	
CSF leak					
Hypertension	0.70	0.57	0.70	0.03	9.77
Type 2 diabetes	NS				
Smoking	NS				
Tumor size	0.45	0.95	0.49	0.84	1.09
Knosp grade	0.34	0.39	0.39	0.05	3.35
Brain edema					
Hypertension	NS				
Type 2 diabetes	0.15	9.07	0.01	1.55	53.1
Smoking	0.15	9.07	0.01	1.55	53.1
Tumor size	0.04	1.04	0.21	0.98	1.10
Knosp grade	0.004	1.22	0.68	0.48	3.10
CN palsy					
Hypertension	0.01	1.78	0.45	0.40	7.88
Type 2 diabetes	0.02	0.34	0.33	0.04	3.05
Smoking	0.0004	0.89	0.90	0.16	5.08
Tumor size	0.33	1.27	0.001	1.05	1.21
Knosp grade	0.59	51.23	0.001	4.97	529.01
Mortality					
Hypertension	0.01	1.85	0.61	0.18	19.3
Type 2 diabetes	0.08	5	0.14	0.60	41.71
Smoking	0.003	1.41	0.78	0.13	15.47
Tumor size	0.001	0.84	0.85	0.92	1.07
Knosp grade	0.02	0.64	0.51	0.17	2.4

Table 5: Predictors of brain edema and CN palsy.

	Pseudo R ²	OR	p	CI 95%	
Brain edema					
	0.67				
Age		1.46	0.02	1.05	2.02
Type 2 diabetes		5.02	0.38	0.14	182.25
Smoking		288.60	0.04	1.19	69751.62
CN palsy					
	0.63				
Age		0.95	0.51	0.81	1.11
Tumor size		0.93	0.36	0.78	1.09
Knosp grade		234.10	0.03	1.92	28542.29

to enhance surgical results, especially for parasellar extension. An advantage of the combined approach is direct visualization of the optic chiasma and for large tumors. The trans-lamina terminalis approach can be considered to reach the third ventricle. Figure 3. For residual tumor, radiotherapy and/or radiosurgery must be considered.

In our series, we observed that age, CSF leakage, brain edema, and early diabetes insipidus were negative factors. Knosp grade was directly associated with CN palsy. Brain edema can be more common in smokers due to its chronic effect on cardiovascular and

pulmonary disease, increased myocardial workload with consequent heart rate and blood pressure increase. Increased sympathetic tone and circulating catecholamines can also play an important role in brain edema [11]. Limitations included limited follow-up after 2007 when the senior author finished his presence in the Institution and no further data could be recorded.

Conclusion

The surgical approach for giant adenomas has individual challenges like a great mass effect in the pituitary fossa, cavernous sinus invasion and surgeon skills. The combined approach should be considered in tumors with suprasellar invasion to facilitate the supra/intra surgical manipulation with visual confirmation of chiasma decompression with less possibility of injuring the hypothalamus. We recommend to consider this approach in patients under 60 years old.

Acknowledgment

We want to thank and recognize the assistance of Marcela Rodríguez-Flores PhD in the statistical analysis.

We want to denote equal contribution for this manuscript in the hypothesis, literature review, statistical analysis, discussion and conclusion elaboration. All authors contributed equally to this work.

References

- Cappabianca P, de Divitiis E. Back to the Egyptians: neurosurgery via the nose. A five-thousand year history and the recent contribution of the endoscope. *Neurosurg Rev.* 2007; 30: 1-7.
- Pollock JR, Akinwunmi J, Scaravilli F, Powell MP. Transcranial surgery for pituitary tumors performed by Sir Victor Horsley. *Neurosurgery.* 2003; 52: 914-925.
- Loyo-Varela M, Herrada-Pineda T, Revilla-Pacheco F, Manrique-Guzman S. Pituitary tumor surgery: review of 3004 cases. *World Neurosurg.* 2013; 79: 331-336.
- Theodros D, Patel M, Ruzevick J, Lim M, Bettegowda C. Pituitary adenomas: historical perspective, surgical management and future directions. *CNS Oncol.* 2015; 4: 411-429.
- Guiot J, Rougerie J, Fourestier M, Fournier A, Comoy C, Vulmiere J, et al. [Intracranial endoscopic explorations]. *La Presse medicale.* 1963; 71: 1225-1228.
- Asa SL, Ezzat S. The pathogenesis of pituitary tumours. *Nat Rev Cancer.* 2002; 2: 836-849.
- Couldwell WT. Giant pituitary tumor combined approach. *World Neurosurg.* 2012; 77: 451-452.
- Loyo M, Kleriga E, Mateos H, de Leo R, Delgado A. Combined supra-infrasellar approach for large pituitary tumors. *Neurosurgery.* 1984; 14: 485-488.
- Kleriga E, Loyo M, Humberto Mateos J, de Leo R, del Valle R, Delgado A. Combined supra and infrasellar approach for the treatment of large hypophyseal tumors. *Arch Invest Med (Mex).* 1985; 16: 75-84.
- Hardy J. Transphenoidal microsurgery of the normal and pathological pituitary. *Clinical neurosurgery.* 1969; 16: 185-217.
- Fu RH, Toyoda Y, Li L, Baser O, Rohde CH, Otterburn DM. Smoking and Postoperative Complications in Plastic and General Surgical Procedures: A Propensity Score-Matched Analysis of 294,903 Patients from the National Surgical Quality Improvement Program Database from 2005 to 2014. *Plast Reconstr Surg.* 2018; 142: 1633-1643.