

Case Report

Atrial Fibrillation in a Patient with Subacute Thyroiditis

Keiichi Kamijo*

Kamijo Thyroid Clinic, Japan

*Corresponding author: Keiichi Kamijo, Kamijo Thyroid Clinic, Japan

Received: June 01, 2018; Accepted: June 15, 2018;

Published: June 26, 2018

Abstract

Atrial fibrillation is the most common arrhythmia worldwide, increasing in prevalence with age. There are few reports about the relationship between atrial fibrillation and subacute thyroiditis. We describe the case of a 54-year-old man who had unexpected atrial fibrillation. He also had thyrotoxicosis caused by subacute thyroiditis. After admission, conversion to sinus rhythm was soon achieved without specific therapy. The present case suggested subacute thyroiditis may contribute to the occurrence of atrial fibrillation as a trigger, but the specific mechanism has not been settled.

Keywords: Atrial fibrillation; Subacute thyroiditis

Introduction

Thyrotoxicosis caused by subacute thyroiditis is self-limited and results from the subacute release of preformed thyroid hormone. Our data showed that the hyperthyroid state may last for 1 or 2 months as the stored thyroid hormone is depleted. It may be followed by a hypothyroid phase in approximately 60% of the cases, but 91% of them return to the euthyroid state and the remaining 9% remained hypothyroid, as presented in Figure 1.

Atrial fibrillation occurs in up to 15% of patients with hyperthyroidism compared to 4% of people in the general population and more common in men [1]. But the case report of subacute thyroiditis with atrial fibrillation is rare. We report the case of a 54-year-old man with subacute thyroiditis who had unexpected atrial fibrillation.

Case Report

A 54-year-old man presented to our observation in November 2017 with 10 days of neck pain, high fever, chills, fatigue, sweating, dysphagia, odynophagia, palpitation, and an 8kg weight loss. A recent history of upper respiratory tract infection was not evident. Bilateral thyroid pain and tenderness were noted. Past medical history was not significant. Family history was pertinent for his niece with hyperthyroidism. On physical examination, the patient had a temperature of 39.9°C, blood pressure of 110/70 mmHg, and weight of 55kg. There was no proptosis, lid lag, conjunctiva; redness, periorbital edema, or erythema. His thyroid gland was enlarged to 48g (normal range 15-35g) estimated by ultrasonography without palpable nodules or lymphadenopathy. Both sides of the anterior thyroid gland were tender to palpation. A cardiovascular examination showed irregular tachycardia without murmurs which was diagnosed as atrial fibrillation (Figure 2). His lungs were clear to auscultation. Laboratory examination revealed the following values: C-reactive protein 11.2mg/dL (reference <0.5), FT3 4.64pg/mL (reference 2.00-4.40), FT4 2.58ng/dL (reference 0.80-1.90), TSH <0.01μU/mL (reference 0.45-4.50), thyroglobulin 584.20ng/mL (reference ≤33.7), thyroglobulin antibody 16.9IU/mL (reference <40), thyroperoxidase antibody 13.7IU/mL (reference <52), TSH Receptor Antibody (TRAb(ECLIA)) <0.3IU/L (reference 2.0). A thyroid ultrasound showed an enlarged heterogeneous hypoechoic

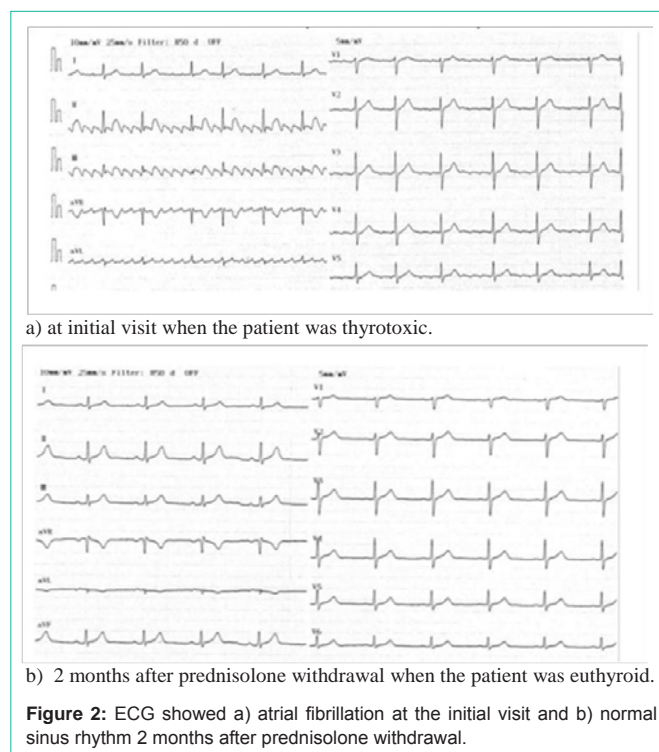
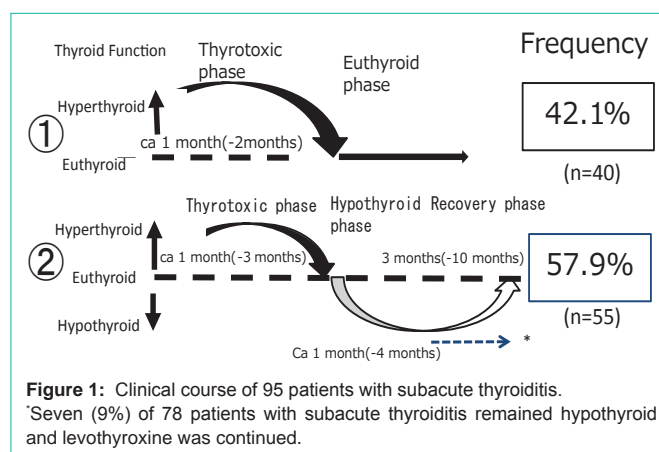


Table 1: Incidence of tachycardia in untreated Graves' disease.

	Females	Males	p value	OR	95% CI
less than 60 years	34.2% (692/2,024)*	26.7% (96/360)	0.0052	1.4286	1.1125-1.8346
60 years and over	18.8% (38/201)	20% (8/40)*	NS		
p value	p<0.0001	NS			
OR	2.2284				
95% CI	1.5597-3.1829				

Tachycardia was present in 834(31.8%) of 2,625 patients with untreated Graves' disease who have been seen in Kamijo Thyroid Clinic between February 1994 and May 2018.

Table 2: Incidence of atrial fibrillation in untreated Graves' disease.

	Females	Males	p value	OR	95% CI
less than 60 years	0.5% (11/2,024)	2.8% (10/360)	p<0.0001	5.2288	2.4075-11.3554
60 years and over	4.5%(8/201)	10%(4/40)	NS		
p value	p<0.0001	p=0.0184			
OR	8.5781	3.8888			
95% CI	4.0627-18.1120	1.2576-12.0257			

Atrial fibrillation was present in 33(1.26%) of 2,625 patients with untreated Graves' disease who have been seen in Kamijo Thyroid Clinic between February 1994 and May 2018.

thyroid gland without discrete nodules. A diagnosis of subacute thyroiditis was made and treatment with prednisolone, 15 mg daily was instituted. He was hospitalized with an acute episode of atrial fibrillation on November 21, 2018. After admission, conversion to sinus rhythm was soon achieved spontaneously and discharged on Nov 30, 2018. Prednisolone 15mg PO daily was tapered by 5mg every 2 weeks and continued over 6 weeks. On Dec 19, 2018, a diagnosis of subacute thyroiditis is finally confirmed by the complete spontaneous resolution of symptoms, thyroid enlargement, and abnormal laboratory data. Two months after prednisolone withdrawal, sinus rhythm was continued, as shown in Figure 1b.

Discussion

We described the case of a 54-year-old man with atrial fibrillation which was soon converted to sinus rhythm without specific therapy. Subacute thyroiditis also was diagnosed.

Sinus tachycardia is the most common rhythm disturbance and is recorded in 31.8% of 2,625 patients with untreated Graves' disease in our clinic, as shown in Table 1 and in 14.8% of patients with subacute thyroiditis (data not shown). However, it is atrial fibrillation that is most commonly identified with thyrotoxicosis. Between 4.5% and 10% of hyperthyroid patients have atrial fibrillation, with the higher end of that range accounting for hyperthyroid patients (primary males) aged 60 and older; conversely only 0.5% and 2.8% of female and male hyperthyroid patients under age 60 have atrial fibrillation, respectively as shown in Table 2 based on our experience. In a large study including more than 23,000 persons, atrial fibrillation was present in 513 subjects (2.3%) in the group with normal values for serum TSH, and in 78(12.7%) and 100(13.8%) in the groups with subclinical and overt hyperthyroidism, respectively [2].

Hamburger et al. [3] also reported the case of a 38-year-old man with subacute thyroiditis who was hospitalized with acute episode of atrial fibrillation. In this case, conversion to sinus rhythm was achieved with bed rest, digitalis, and quinidine.

In conclusion, the present case report suggested subacute thyroiditis may contribute to the occurrence of atrial fibrillation as a trigger, although further studies will be needed to clarify its exact mechanism.

References

1. Bielecka Dabrowa A, Mikhallidis DP, Rysz J, Banach M. The mechanism of atrial fibrillation in hyperthyroidism. *Thyroid Res.* 2009; 2: 4.
2. Auer J, Scheibner P, Mische T, Langsteger W, Eber O, Eber B. Subclinical hyperthyroidism as a risk factor for atrial fibrillation. *Am Heart J.* 2001; 142: 838-842.
3. Hamburger JL. Subacute thyroiditis: diagnostic difficulty and simple treatment. *J Nucl Med.* 2018; 15: 81-89.