

## Case Report

# Inhabitual Abdominal Pain: A Mesenteric Venous Thombosis wih Negative D-Dimer, a Case Report

Lamarque L<sup>1\*</sup> and Thomas L<sup>2</sup><sup>1</sup>Hospital Begin, France<sup>2</sup>Department of Emergency, Hospital Begin, France**\*Corresponding author:** Louis Lamarque, Hospital Begin, Intern in General Medicine, France**Received:** February 22, 2021; **Accepted:** March 01, 2021; **Published:** March 08, 2021

## Background

Abdominal pain is a frequent reason for medical consultation, event more so in emergency sevices. In France, this can represent up to 10% of emergency admissions. But, most of most urgent diagnoses can be made clinically (abdominal defense, fecaloid vomiting, etc.) or biologically (D-Dimer, inflammatory syndrome, etc.). In these case, clinical and biology favored mild functional pain.

The annual incidence of Deep Vein Thrombosis (DVT) in the general population in France is about 1% to 1.6%. It can occur without triggering factor identified or in patients with risk factors. When the predictive score of venous thromboembolic disease is low, the diagnostic strategy is that D-dimers are assayed for eliminating DVT, the negative predictive value being very high, around 94% to 100%. The cases of false negatives reported in the literature are few and question the false negative D-dimer etiology.

## Case Presentation

We report the case of a 39-year-old man, without any medical history, presenting himself to emergency consultation for abdominal pain. The pain was umbilical, as a cramp, since two or three days without trigger factor descripting. This man had no disorder of the transit, no urinary functional signs and no fever or asthenia.

The clinical examination revealed a hemodynamically stable patient, his blood pressure was 134/84 mmHg, with a heart rate of 75 beats per minute, a respiratory rate of 14 cycles per minute and a temperature of 36.8° Celsius. . However, we note an abdomen very sensitive to the peri-umbilical palpation, and this despite analgesics of levels 1 and 2, without clear defense.

We decided, first to make some blood test and try to treat the patient with analgesic, because he didn't seem particularly serious. The blood test does not show any abnormalities otherwise minimal hyperleukocytosis. D-Dimers are negative (<0.27). A CT scan (Figure 1) is requested due to the pain and abnormal palpation, and feeling of medical staff. It discovers a mesenteric thrombosis without signs of digestive distress. The patient is then treated with unfractionated heparin continuously before being transferred to the internal medicine department for further explorations. These explorations have so far not found any genetic abnormalities explaining the spontaneous appearance of his disease. However, there is a long history of phlebitis in the patient's family without any mutation having been identified.

## Abstract

It is about the fortuitous discovery of a mesenteric thrombosis without signs of gravity, in front of an atypical abdominal pain in a man of 39 without antecedents and without clinical or biological abnormalities, in particular negative D-Dimer.

**Keywords:** Thrombosis; Mesenteric; Negative d-dimer; Abdominal pain

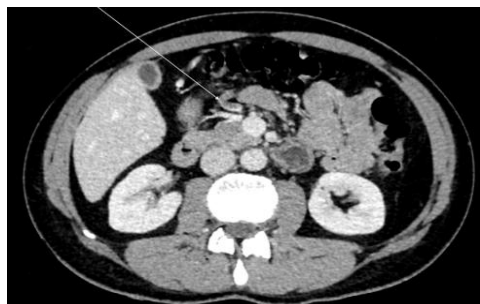
The patient is actually treated by new oral anticoagulants.

## Discussion

Mesenteric venous thrombosis is a difficult diagnosis among the abominable acute or subacute pain panel due to the absence of specific signs and the low incidence of this pathology [1]. Not very well known by practitioners, it does not have a specific ICD classification [2] and is therefore classified among deep thromboembolic diseases (portal vein thrombosis, specified vein thrombosis or other thrombosis). That's why epidemiology of this disease is complicated. According to many studies [3-5], it's a trouble estimated at 2, 7 per 100 000 person-years. The overall incidence of mesenteric venous thrombosis is estimated at 1 in 1000 emergency department admissions and accounts for 6% to 9% of all acute mesenteric ischemic event [3,6]. However, many mesenteric venous thrombosis was preceded by acute or chronic thrombosis (respectively 71 per cent et 29 per cent in Malmo series [1]). That's why our patient is surprising, because, at the age of 39 years old, he started with an acute mesenteric venous thrombosis without any other thrombosis elsewhere or earlier. And, he does not present transitory or permanent (as we know on this time obviously) risk factor for thrombosis. Whatever, the only way to diagnose an acute venous mesenteric thrombosis is a CT-Scan. Obviously, we cannot make this irradiating examination at all patient with abdominal pain. That's why it's must be a set of argument and we can try to rely on biological tests.

In all the studies of prevalence and risk factors concerning this mesenteric venous thrombosis, D-dimer is described as a very sensitive marker, as in all thromboembolic events [7]. Indeed, Acosta et al. [1] demonstrate increased D-dimer in all patients studied with mesenteric venous thrombosis and Yang and al. describe D-Dimer as an early marker of severity for acute superior mesenteric venous thrombosis [8]. Furthermore, the sensitivity and negative D-dimers levels are very high, between 94% to 100% [9] in the diagnosis of DVT in «all comers» patients and 100% in patients with predisposing factors [10]. The main problem of this blood test, described by many studies is this lack of specificity, Indeed, many factor can increase the rate of D-Dimer, this product of fibrin degradation, present in blood after fibrinolysis, like sepsis, age or pregnancy.

While false negatives are rare, the study by Kraaijenhagen et al. highlights a few factors that may be responsible for a decrease in the sensitivity of D-dimers. This is the time between dosing and onset



**Figure 1:** Sagittal CT scan.

of symptoms or preventative administration of LMWH. This is absolutely not the case with our young patient.

In superficial venous thrombosis or in suspicion of pulmonary embolism, we can use two score (Well and Geneve) which, associated with D-Dimers can exclude with a negative predictive value of almost 100 per cent the diagnostics [11]. Unfortunately, there is no such predictive score in mesenteric thrombosis.

### Learning Point

- He can exist deep venous thrombosis with negative D-Dimer.
- We must think about mesenteric thrombosis, a rare but potential diagnostic.
- We cannot base our medical reasoning only on predictive scores and biology.
- Gut feeling can be useful and sometimes must be followed.

### References

1. Acosta S, Alhadad A, Svensson P, Ekberg O. Epidemiology, risk and prognostic factors in mesenteric venous thrombosis. *BJS Br J Surg*. 2008; 95: 1245-1251.
2. Classification Internationale des Maladies (CIM).
3. Md M, Ji E, Ac C, Js M, Wh P, Js Y. Mesenteric venous thrombosis: a changing clinical entity. *Journal of vascular surgery. J Vasc Surg*. 2001; 34: 680-684.
4. Umpleby HC. Thrombosis of the superior mesenteric vein. *BJS Br J Surg*. 1987; 74: 694-696.
5. Kumar S, Kamath PS. Acute superior mesenteric venous thrombosis: one disease or two?. *The American journal of gastroenterology. Am J Gastroenterol*. 2003; 98.
6. Harnik IG, Brandt LJ. Mesenteric venous thrombosis. *Vascular medicine (London, England). Vasc Med*. 2010; 15.
7. Becker DM, Philbrick JT, Bachhuber TL, Humphries JE. D-dimer testing and acute venous thromboembolism. A shortcut to accurate diagnosis? *Arch Intern Med*. 1996; 156: 939-946.
8. Yang S, Fan X, Ding W, Liu B, Meng J, Wang K, et al. D-Dimer as an Early Marker of Severity in Patients With Acute Superior Mesenteric Venous Thrombosis. *Medicine (Baltimore)*. 2014.
9. Evaluation of the usefulness of a D dimer test in combination with clinical pretest probability score in the prediction and exclusion of Venous Thromboembolism by medical residents. 2014.
10. Rahiminejad M, Rastogi A, Prabhudesai S, McClinton D, MacCallum P, Platon S, et al. Evaluating the Use of a Negative D-Dimer and Modified Low Wells Score in Excluding above Knee Deep Venous Thrombosis in an Outpatient Population, Assessing Need for Diagnostic Ultrasound. *ISRN Radiol*. 2014; 2014: 519875.
11. Exclusion of deep vein thrombosis using the Wells rule in clinically important subgroups: individual patient data meta-analysis. *The BMJ*. 2014.