

Clinical Image

Headache, Vertigo in a Teenage Dental Patient

Shreya Gupta^{1*}; Munira Ali²¹Ziva Dental, Clinical Practice, San Antonio, Texas, USA²Department of Radiology, Thumbay Hospital, Ajman, UAE***Corresponding author: Shreya Gupta**

Lead Dentist & Orthodontist, Ziva Dental, 5835 Culebra Road #105, San Antonio, Texas 78228, USA.

Email: drshreyagupta@gmail.com

Received: September 20, 2023**Accepted:** October 12, 2023**Published:** October 19, 2023

Clinical Image

A 13-year-old female patient presented to the dental office for routine dental checkup and correction of her proclined teeth through braces. Patient's medical history suggested that the patient suffers from frequent episodes of headache, vertigo, dizziness and confusion. These episodes are random and have begun after the onset of menarche. Her physician diagnosed it as migraine and had prescribed medications which are helping with the headache but the episodes still happen at random. Routine lateral cephalometric x-ray done for orthodontic diagnosis, revealed a bony bridge on the posterosuperior articular process of atlas (C1 vertebra).

The most common presentation of this condition is:

- Atlantoaxial assimilation
- Ponticulus posticus
- Congenital defect of posterior arch
- Artifact due to inaccurate neck posture

Ponticulus Posticus (PP) is created through ossification of the posterior atlantooccipital ligament. Several studies [1,2] have indicated that, the presence of arcuate foramen is associated with headache, musculoskeletal pain and vertebrobasilar stroke due to occlusion of the vertebral artery and the surgical excision of such a PP occlusion appears to alleviate these symptoms. The cephalogram must be looked upon as a baseline screening tool for detecting anomalies and pathology in the cervical spine region and may prove to be of great benefit to chronic headache sufferers who have as yet gone without the proper diagnosis.

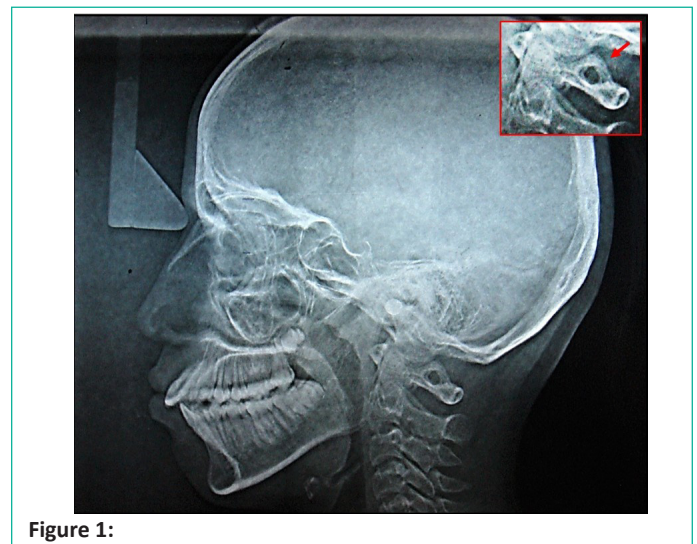


Figure 1:

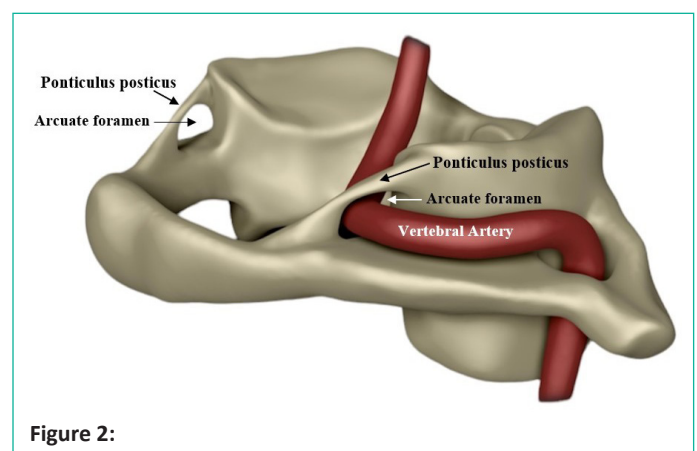


Figure 2: