

Review Article

Congenital Diaphragmatic Hernia: More than Just a Lung Problem

Emam D^{1,2*}, Van der Veecken L^{2,5}, El Badry A³, Elattar A¹, Awara A¹ and Deprest J^{2,4}

¹Department Obstetrics and Gynaecology, University Hospitals Tanta, Tanta, Egypt

²Clinical Department Obstetrics and Gynaecology, University Hospitals Leuven, Leuven, Belgium

³Department Radiology, University Hospitals Tanta, Tanta, Egypt

⁴Institute for Women's Health, University College London, London, UK

⁵Departement Obstetrics and Gynecology, University Hospital Antwerp, Belgium

*Corresponding author: Emam D, Department Obstetrics and Gynaecology, Tanta University, El-Gaish, Tanta Qism 2, 31527, Tanta, Gharbia Governorate, Egypt

Received: July 13, 2021; Accepted: July 29, 2021;

Published: August 05, 2021

Abstract

Congenital Diaphragmatic Hernia (CDH) is a rare congenital anomaly characterized by a defect in the diaphragm, which permits abdominal organs to herniate into the thorax. This causes lung hypoplasia and at birth, children with CDH experience respiratory distress and pulmonary hypertension. Despite optimal neonatal treatment, CDH is still associated with a high mortality and morbidity. In severe cases, Fetal Intervention (FETO) may alter the natural course of this disease. Herein we describe the rationale, action mechanism and technique to perform this intervention. Despite hope giving results, this technique remains investigational for left sided CDH. However, an increased survival may come at the cost of increased morbidity. Children born with CDH are at increased risk for long and short-term morbidity, including neurodevelopmental problems. Until now, there are still uncertainties about the severity and prevalence of neurologic morbidity. Furthermore, it remains uncertain if these problems are already present prenatally and if a prenatal intervention influence this.

Keywords: Congenital diaphragmatic hernia; CDH; FETO; Neurologic outcome; Neurodevelopment

Abbreviations

CDH: Congenital Diaphragmatic Hernia; FETO: Fetoscopic Endoluminal Tracheal Occlusion; TOTAL Trial: Tracheal Occlusion to Accelerate Lung Growth Trial; o/e LHR: Observed-to-Expected LHR; ECMO: Extracorporeal Membrane Oxygenation; CI: Confidence Interval

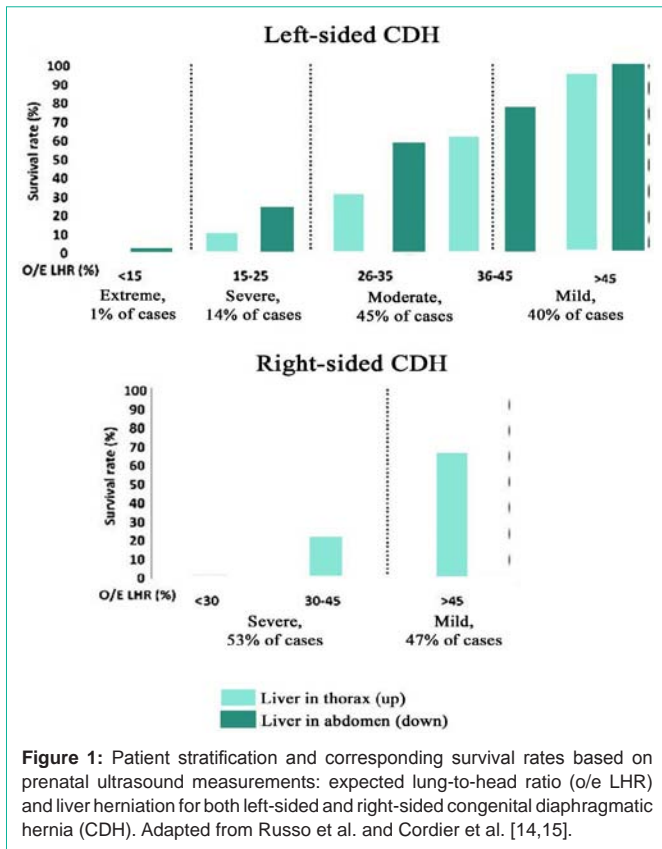
Introduction

Congenital Diaphragmatic Hernia (CDH) is a rare congenital anomaly affecting approximately 3/10,000 pregnancies [1]. In this condition, there is a defect in the diaphragm that is either left-sided (85%), right-sided (13%); rarely it is bilateral (2%) or other rare forms. The hole in the diaphragm, permits abdominal organs to herniate into the thorax and interfere with normal lung development. This causes pulmonary hypoplasia, characterized by fewer and less developed airway branches and pulmonary vessels. Clinically at birth, CDH babies experience respiratory insufficiency and or pulmonary hypertension. In current screening programs, around 70% of cases are diagnosed prenatally. Despite optimal treatment, only 71% of prenatally and 83% of postnatally diagnosed cases will survive [2]. Survivors often suffer from short and long-term complications including chronic lung disease, transient or persistent pulmonary hypertension, gastro-oesophageal reflux, thoracic deformities, neurodevelopmental and behavioural problems and hearing loss [3-9].

Prenatal diagnosis is typically made on mid-gestational screening ultrasound. Once foetuses are diagnosed with CDH, advanced imaging is needed to identify the side of the defect, measure the lung size and to exclude additional malformations. Genetic testing (preferentially micro-arrays) is mandatory and syndromic cases may need to be ruled out. Accurate measurement of the lung is needed to

predict survival, neonatal morbidity and to select foetuses that might benefit from a prenatal intervention [10-12]. On ultrasound, the contralateral lung can be measured accurately in the four-chamber view, either by measuring the longest axis but best by measuring the contour of the lung [10]. The measurement of the lung area is then divided by the head circumference to calculate the Lung-to-Head Ratio (LHR). Because the LHR is dependent on the gestational age, measurements in the index case are compared to the LHR of a normal foetus of the same gestational age, allowing calculation of the Observed-to-Expected LHR (o/e LHR) (www.totaltrial.eu) [13]. Next to measurements of the lung, the position of the liver is described as "up" or "down" and the position of the stomach is graded (grade 1-4) as illustrated at Figure 1 and 2 [14-16]. Based on either increasing survival rates, CDH can then be categorized as severe, moderate or mild, each corresponding with a given range in o/e LHR and liver position. Fetal MRI can be used to rule out additional malformations and to calculate the Total Lung Volume (TFLV), which can also be expressed as a function of what is expected in a normal fetus of either the same gestation, or body-volume. MRI can also be used to measure the degree of liver in the chest [17-19]. The advantage of MRI is that it is less influenced by maternal habitus, amniotic fluid quantity and it allows measurement of both lungs.

Patients should be referred to deliver in a high-volume center because that has been demonstrated to increase neonatal survival [20]. The route of delivery does not influence survival chances but it is best planned at term (37-40 weeks). After birth, newborns are immediately cared for by experienced neonatologist who will assess if intubation with ventilation and sedation are necessary. Evaluation of pulmonary hypertension and cardiac function will be performed and treatment initiated if necessary. Treatment of pulmonary hypertension can be difficult and persistent pulmonary hypertension is associated with a high mortality [21]. Surgical correction of the



defect is not an emergency and should be performed after stabilization of the neonate. Repair can be performed by laparotomy/laparoscopy or by thoracotomy/thoracoscopy. During surgery, abdominal organs will be repositioned from the thorax into the abdomen and the diaphragmatic defect will be closed primarily or with a patch depending on the size of the defect.

Fetal Intervention

Because of its poor outcome, there has been much interest in a prenatal therapy. Originally Harrison et al. considered primary in utero repair of the defect. However, a randomized trial failed to demonstrate a clear benefit [22]. Observations of hyperplastic lungs in fetuses with Congenital High Airway Obstruction Syndrome

Table 1: Neurodevelopmental delay rate of impairment in isolated congenital diaphragmatic hernia.

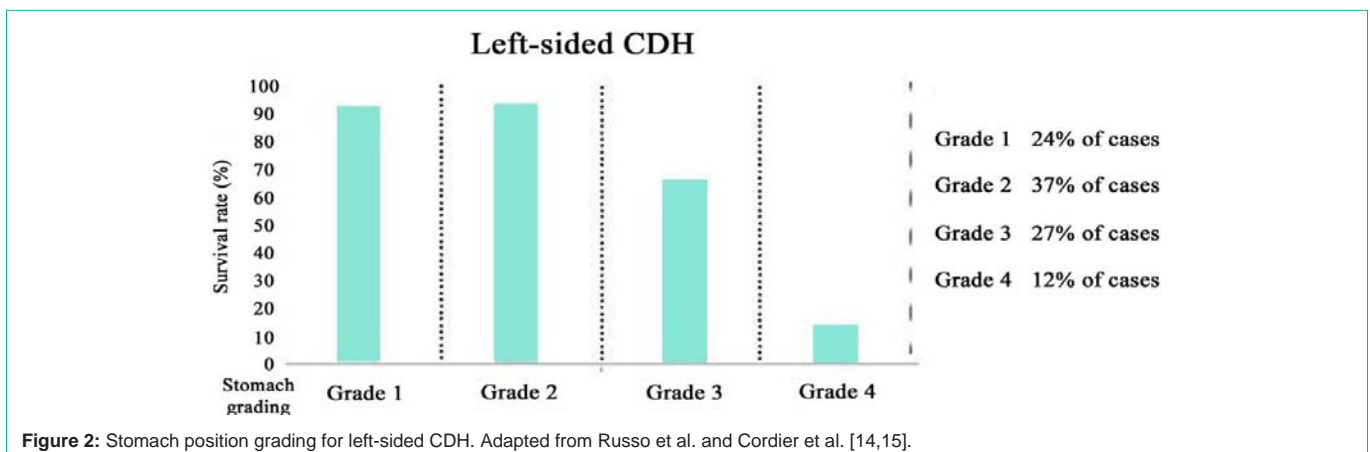
Neurological Domain	Rate of Impairment	Confidence Interval (CI)
Overall developmental problems	16%	3-35%
Motor function problems	13%	2-30%
Abnormal Cognition	5%	0-20%
Hearing abnormalities	3%	1-7%

(CHAOS) led to the concept that fetal Tracheal Occlusion (TO) may reverse experimental pulmonary hypoplasia [23,24]. In experimental conditions sustained TO markedly reduce the number of type II pneumocytes hence surfactant expression. This can be prevented by in utero release of the TO (typically referred to as “plug-unplug sequence”) [25]. Occlusion is currently clinically achieved by introducing a balloon in the trachea, which can also be punctured prenatally. This procedure is referred to as FETO (Fetoscopic Endoluminal Tracheal Occlusion). An initial trial demonstrated an increased survival in both left and right sided severe cases [26]. Similar results were reported by others, but eventually the benefit of fetal surgery was investigated in a large randomized controlled trial in left sided CDH fetuses (Tracheal Occlusion to Accelerate Lung growth-trial, or TOTAL trial). The results of this trial remain awaited. We recently reported on significant higher survival rates in fetuses with RCDH. Today, therefore we offer FETO clinically in severe cases with RCDH, and we will define our strategy in left-sided cases based on the outcome of the TOTAL trial [27,28].

Technique

Balloon insertion or plug

To prevent caval compression, the patient is positioned dorsal supine in lateral tilt. FETO is a minimally invasive; ultrasound guided fetoscopic procedure, which can be done under local anesthesia. Maternal conscious sedation can be used as well. A combination of fentanyl, curare and atropine are administered to the fetus for analgesia, immobilization and the prevention of bradycardia. The fetoscope (1.3mm, Karl Storz) is housed within a curved 3.3mm sheath (Karl Storz), with three ports, which allow insertion of instruments (balloon on microcatheter, adjustable puncture needle or forceps) and irrigation Figure 3A and 3B). Accurate placement of the trocar is needed to avoid the placenta and to ensure that the



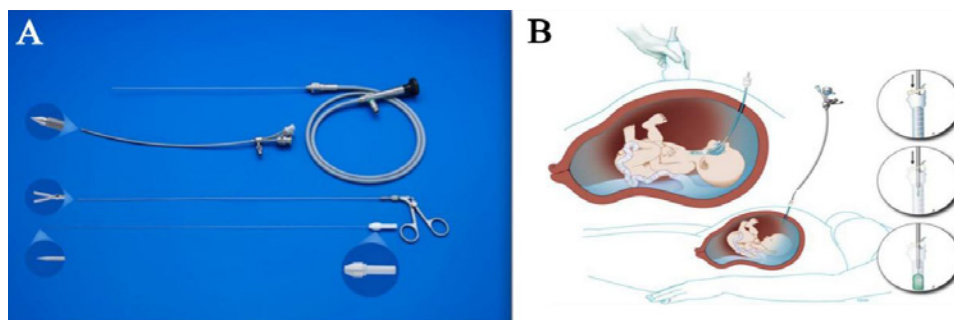


Figure 3: A-Fetoscope, fetoscopic forceps, and stylet, courtesy of KARL STORZ Endoscope, Tuttlingen, Germany. B-Fetal endoscopic tracheal occlusion (FETO): a schematic drawing showing access to uterus and the fetal trachea. ©UZ Leuven, UZ Leuven, Belgium, drawing Myrthe Boymans.

fetoscope can enter at the level of the tip of the fetal nose, and easily directed towards the fetal mouth and pharynx. By following the different landmarks (fetal lips, tongue, raphe of the palatum, uvula and the epiglottis), the fetoscope is advanced into the trachea until the carina is visualized (Figure 4). A detachable balloon (Goldbal2, Balt, Montmorency, France) which was originally designed for endovascular occlusion, is placed between the carina and the vocal cord, using a delivery catheter (Baltacci-BDPE-100 0.9mm; Balt) and filled with 0.6mL saline. When inflated, the balloon measures 7x20 mm. Typically, this procedure takes 10 minutes. In the randomized clinical “TOTAL trial”, balloon insertion was between 27 and 29 gestational weeks in severe cases, in moderate cases this was between 30 and 32 weeks. The inflated can be visualized using ultrasound, where it appears as a hypoechoic fluid filled structure in between the neck vessels, which can be visualized using colour Doppler flow [29]. Postoperatively patients are followed weekly by ultrasound to assess the fetal condition, measure lung response, screen for complications (such as polyhydramnios and chorioamniotic membrane separation) and exclude spontaneous deflation.

Balloon removal or unplug

Ideally, the balloon is removed at 34 weeks, for several reasons. First, release induces lung maturation; second, it makes vaginal birth possible and it enables patients to travel back to a tertiary center where she typically delivers. Prenatal removal also increases survival rate [30]. When the patient ruptures her membranes prior to 34 weeks, and there be threatening premature birth, the balloon may need to be removed earlier.

In the balloon can be removed fetoscopically, by percutaneous ultrasound guided puncture of the balloon, or, if impossible, also during caesarean section, when the baby is still on placental circulation. The choice of removal technique is dependent on operator preference, accessibility of the fetal mouth and neck and, or the fetal or maternal condition. The technique for removal does not influence the mean gestational age at delivery [31]. When balloon removal needs to be done in an emergency by an unprepared team, not familiar with the procedure, there is one in three risk for iatrogenic fetal death [32].

Outcomes of FETO

Initial results demonstrated that, when compared to historical data, survival in severe cases increased from 24% to 49% [32]. In right sided cases, it was demonstrated that survival increased from 15% to 41% in severe (o/e LHR <55%) [33]. A 2016 systematic review

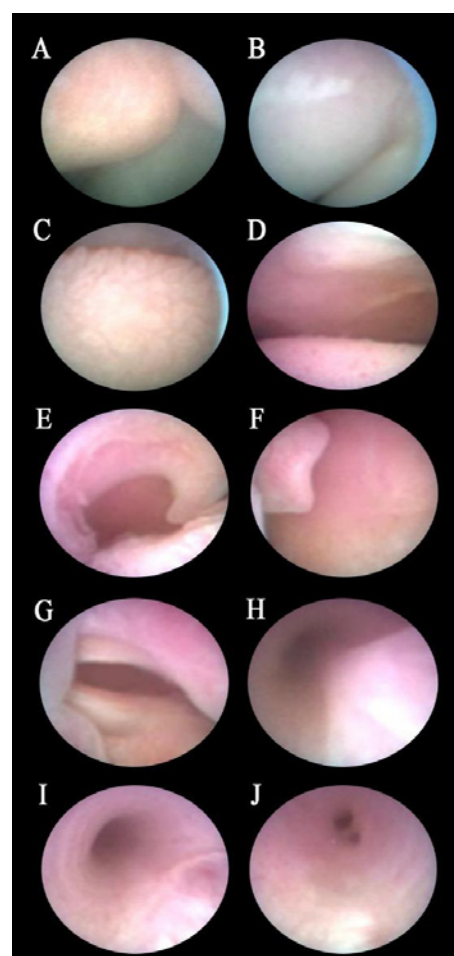


Figure 4: Fetoscopic pathway within FETO from A to J. A: Tip of the nose. B) Philtrum; C) Tongue; D) The raphe of the palate. E) Uvula; F) Epiglottis; G) Vocal cords; H) Inwards bulging pars membrane. I: tracheal rings. J-carina. ©UZ Leuven, UZ Leuven, Belgium.

including 5 studies suggest increased survival after FETO (OR 13.32 (5.40-32.87)) at the expense of an increased risk for prematurity [34]. Because of lack of randomized data, the TOTAL trial was set up in 2010, and concluded in 2020; its results are eagerly awaited. In that trial, also moderate cases (o/eLHR 25-34.9% or o/eLHR 35-44.9 % with liver ‘up’) were included, and balloon insertion was at a later gestational age (30-32 weeks).

Serious adverse fetal effects are rare. A barking cough and tracheomegaly have been described but reportedly, they disappear over time [35-37]. The most frequent complication remains preterm birth. Median delivery is at 35.3 weeks and 30% delivers before 34 weeks. This is typically associated with membrane rupture. In a systematic review and meta-analysis of fetal surgery series, severe maternal complications (such as placental abruption) were seen in 1.08% of FETO cases [38]. Minor complications occurred in 2.39%, these include bleeding during the procedure, the need for maternal blood transfusion, chorioamnionitis, wound infection or mild pulmonary edema.

Future Research

CDH remains linked with a high mortality and in survivors, long-term morbidity. For parents expecting a child with CDH, the impact of long-term morbidity will play a significant role when choices have to be made on prenatal treatment or termination of pregnancy. Morbidity in CDH survivors can become evident early as well as later on in life, in many different domains. At present, there are no studies enable prenatal prediction of these. Chronic lung disease, (transient) pulmonary hypertension, gastro-oesophageal reflux, failure to thrive and thoracic deformities are frequent in CDH survivors. Children with CDH may be at increased risk for neurologic morbidity such as neurodevelopmental delay, hearing loss and behavioural problems. Several studies found cognitive and motor problems in children with CDH to be prevalent in 16-80% [21,39-46]. The risk for neurologic complications has been correlated to certain postnatal events, such as the use of Extracorporeal Membrane Oxygenation (ECMO), perioperative hypoxic brain injury and long stay in the neonatal intensive care unit [41,47-49]. The use of anesthesia for neonatal repair may also impair to impair normal brain development, as suggested in preclinical studies [50-52]. However, whether brain development in CDH children is altered as a consequence of postnatal events and its complications, or if they are part of the condition and already present before birth, remains to be elucidated. There is some recent evidence that changes may already be present prenatally. On prenatal ultrasound, peak systolic velocity of the middle cerebral artery has been found to be lower in children with CDH [53]. In another report, the pulsatility index of the middle cerebral artery was lower in CDH fetuses coinciding with reduced left cardiac output [54]. Also, in a large cohort of CDH fetuses, transcerebellar diameters were smaller in CDH fetuses, compared to normal towards the end of pregnancy, and this was correlated to the severity of the disease. Prenatal MRI demonstrated the presence of an enlarged extra axial space in up to 50% of CDH fetuses, though the relevance of it is unknown [55]. To our knowledge there are no studies looking into cortical folding, gyration patterns or volumetric assessment of both the brain and fluid, have been performed.

Postnatal data are scarce and very often outcomes of isolated and non-isolated cases are mixed, neither is there information on severity of hypoplasia. Structural as well as genetic associated problems are independent determinants of outcome, including neurocognitive function [56-62]. In non-isolated cases, the relative risk for developmental problems was found to be 2.35 (CI 1.33-4.14), which was also found by Tureczek et al. in their study [63,64]. Similar findings were observed for motor, cognitive and hearing problems [65-67]. The risk for autism would be nine times higher in non-

isolated cases [68].

We recently performed a systematic review, and demonstrated that in isolated CDH there were overall development problems in 16% of children, mainly due to motor function problems (13%; CI: 2-30%). Cognition was abnormal in 5% (CI: 0-20%) which is comparable to that in the normal population [69-71]. Hearing abnormalities were detected in 3% (CI: 1-7%) (Table 1). An important limitation of that review and meta-analysis was that these conclusions are based on very few studies and a limited number of patients. There were only four studies on general development and cognition with less than 100 patients. Motor evaluation was reported in 7 studies including 168 patients. The data on hearing loss were reported in two studies. This demonstrates that more data is needed on the neurologic outcome of children born with CDH, preferentially severity related, and that follow-up of CDH children would benefit from a standardized core outcome set.

Lastly, there is a lack of data on the outcome of children treated prenatally. In one study, comparing fetuses treated prenatally with FETO to fetuses treated postnatally [4], no differences were found. That study however included only 9 (expectant) and 7 (FETO) patients. Based on the limited outcome data in fetuses with isolated CDH, there may be an increased risk for neurologic morbidity. Also, prenatal imaging studies may demonstrate whether that problem already originates in utero. There is clearly room for new prospective studies, which may also take the severity of the condition into account, as well as fetal treatment.

Conclusion

Congenital Diaphragmatic Hernia (CDH) is a rare congenital anomaly with high risk for mortality and morbidity. Because of poor postnatal outcome in cases with severe pulmonary hypoplasia, a Fetal Intervention (FETO) that may alter the natural course of the disease was introduced. Clinical trials have now been concluded and demonstrate benefit for severe left and right sided CDH. Children born with CDH are at increased risk for long and short-term morbidity in multiple domains, including neurodevelopmental problems. It remains uncertain if these problems are already present prenatally and if a prenatal intervention can change the natural course. Further research should be aimed at clarifying this.

Funding

DE is funded by the Egyptian educational scholarship from the Ministry of Higher Education and Scientific Research, Egypt. LvdV is funded by the Erasmus + Program of the European Union (Framework Agreement number: 2013-0040). JD is receiving support from the Wellcome Trust (WT101957) and Engineering and Physical Sciences Research Council (ESPRC) (NS/A000027/1) and the Great Ormond Street Hospital Charity Fund. EE is funded by (SLT008/18/000156). This publication reflects the views only of the authors, and the Commission cannot be held responsible for any use, which may be made of the information contained therein.

References

1. EUROCAT. EUROCAT Statistical Monitoring Report - 2012. 2015.
2. van den Hout L, Schaible T, Cohen-Overbeek TE, Hop W, Siemer J, van de Ven K, et al. Actual outcome in infants with congenital diaphragmatic hernia: the role of a standardized postnatal treatment protocol. *Fetal Diagn Ther*.

- 2011; 29: 55-63.
3. Bagolan P, Morini F. Long-term follow up of infants with congenital diaphragmatic hernia. *Semin Pediatr Surg.* 2007; 16: 134-144.
 4. Cortes RA, Keller RL, Townsend T, Harrison MR, Farmer DL, Lee H, et al. Survival of severe congenital diaphragmatic hernia has morbid consequences. *J Pediatr Surg.* 2005; 40: 36-45; discussion 45-46.
 5. Grover TR, Murthy K, Brozanski B, Gien J, Rintoul N, Keene S, et al. Short-term outcomes and medical and surgical interventions in infants with congenital diaphragmatic hernia. *Am J Perinatol.* 2015; 32: 1038-1044.
 6. Lally KP, Engle W. Post discharge follow-up of infants with congenital diaphragmatic hernia. *Pediatrics.* 2008; 121: 627-632.
 7. Tracy S, Chen C. Multidisciplinary long-term follow-up of congenital diaphragmatic hernia: a growing trend. *Semin Fetal Neonatal Med.* 2014; 19: 385-391.
 8. van den Hout L, Sluiter I, Gischler S, De Klein A, Rottier R, Ijsselstijn H, et al. Can we improve outcome of congenital diaphragmatic hernia? *Pediatr Surg Int.* 2009; 25: 733-743.
 9. Verbelen T, Lerut T, Coosemans W, De Leyn P, Naftoux P, Van Raemdonck D, et al. Antireflux surgery after congenital diaphragmatic hernia repair: a plea for a tailored approach. *Eur J Cardiothorac Surg.* 2013; 44: 263-267; discussion 268.
 10. Metkus AP, Filly RA, Stringer MD, Harrison MR, Adzick NS. Sonographic predictors of survival in fetal diaphragmatic hernia. *J Pediatr Surg.* 1996; 31: 148-151; discussion 151-152.
 11. Done E, Debeer A, Gucciardo L, Van Mieghem T, Lewi P, Devlieger R, et al. Prediction of neonatal respiratory function and pulmonary hypertension in fetuses with isolated congenital diaphragmatic hernia in the fetal endoscopic tracheal occlusion era: a single-center study. *Fetal Diagn Ther.* 2015; 37: 24-32.
 12. Jani J, Nicolaides KH, Keller RL, Benachi A, Peralta CF, Favre R, et al. Observed to expected lung area to head circumference ratio in the prediction of survival in fetuses with isolated diaphragmatic hernia. *Ultrasound Obstet Gynecol.* 2007; 30: 67-71.
 13. Dekoninck P, Gratacos E, Van Mieghem T, Richter J, Lewi P, Ancel AM, et al. Results of fetal endoscopic tracheal occlusion for congenital diaphragmatic hernia and the setup of the randomized controlled TOTAL trial. *Early Hum Dev.* 2011; 87: 619-624.
 14. Russo FM, Eastwood MP, Keijzer R, Al-Maary J, Toelen J, Van Mieghem T, et al. Lung size and liver herniation predict need for extracorporeal membrane oxygenation but not pulmonary hypertension in isolated congenital diaphragmatic hernia: systematic review and meta-analysis. *Ultrasound Obstet Gynecol.* 2017; 49: 704-713.
 15. Cordier AG, Jani JC, Cannie MM, Rodo C, Fabietti I, Persico N, et al. Stomach position in prediction of survival in left-sided congenital diaphragmatic hernia with or without fetoscopic endoluminal tracheal occlusion. *Ultrasound Obstet Gynecol.* 2015; 46: 155-161.
 16. Kitano Y, Okuyama H, Saito M, Usui N, Morikawa N, Masumoto K, et al. Re-evaluation of stomach position as a simple prognostic factor in fetal left congenital diaphragmatic hernia: a multicenter survey in Japan. *Ultrasound Obstet Gynecol.* 2011; 37: 277-282.
 17. Lazar DA, Ruano R, Cass DL, Moise KJ Jr., Johnson A, Lee TC, et al. Defining "liver-up": does the volume of liver herniation predict outcome for fetuses with isolated left-sided congenital diaphragmatic hernia? *J Pediatr Surg.* 2012; 47: 1058-1062.
 18. Mayer S, Klaritsch P, Petersen S, Done E, Sandaite I, Till H, et al. The correlation between lung volume and liver herniation measurements by fetal MRI in isolated congenital diaphragmatic hernia: a systematic review and meta-analysis of observational studies. *Prenat Diagn.* 2011; 31: 1086-1096.
 19. Cannie M, Jani J, Chaffiotte C, Vaast P, Deruelle P, Houfflin-Debarge V, et al. Quantification of intrathoracic liver herniation by magnetic resonance imaging and prediction of postnatal survival in fetuses with congenital diaphragmatic hernia. *Ultrasound Obstet Gynecol.* 2008; 32: 627-632.
 20. Snoek KG, Greenough A, van Rosmalen J, Capolupo I, Schaible T, Ali K, et al. Congenital Diaphragmatic Hernia: 10-Year Evaluation of Survival, Extracorporeal Membrane Oxygenation, and Foetoscopic Endotracheal Occlusion in Four High-Volume Centres. *Neonatology.* 2018; 113: 63-68.
 21. Wynn J, Aspelund G, Zygmunt A, Stolar CJ, Mychaliska G, Butcher J, et al. Developmental outcomes of children with congenital diaphragmatic hernia: a multicenter prospective study. *J Pediatr Surg.* 2013; 48: 1995-2004.
 22. Harrison MR, Adzick NS, Bullard KM, Farrell JA, Howell LJ, Rosen MA, et al. Correction of congenital diaphragmatic hernia in utero VII: a prospective trial. *J Pediatr Surg.* 1997; 32: 1637-1642.
 23. Wilson JM, DiFiore JW, Peters CA. Experimental fetal tracheal ligation prevents the pulmonary hypoplasia associated with fetal nephrectomy: possible application for congenital diaphragmatic hernia. *J Pediatr Surg.* 1993; 28: 1433-1439; discussion 1439-1440.
 24. Hedrick MH, Estes JM, Sullivan KM, Bealer JF, Kitterman JA, Flake AW, et al. Plug the lung until it grows (PLUG): a new method to treat congenital diaphragmatic hernia in utero. *J Pediatr Surg.* 1994; 29: 612-617.
 25. Flageole H, Evrard VA, Piedboeuf B, Laberge JM, Lerut TE, Deprest JA. The plug-unplug sequence: an important step to achieve type II pneumocyte maturation in the fetal lamb model. *J Pediatr Surg.* 1998; 33: 299-303.
 26. Deprest J, Gratacos E, Nicolaides KH, Group FT. Fetoscopic Tracheal Occlusion (FETO) for severe congenital diaphragmatic hernia: evolution of a technique and preliminary results. *Ultrasound Obstet Gynecol.* 2004; 24: 121-126.
 27. Deprest JA, Nicolaides KH, Benachi A, Gratacos E, Ryan G, Persico N, et al. Randomized Trial of Fetal Surgery for Severe Left Diaphragmatic Hernia. *N Engl J Med.* 2021; 385: 107-118.
 28. Deprest JA, Benachi A, Gratacos E, Nicolaides KH, Berg C, Persico N, et al. Randomized Trial of Fetal Surgery for Moderate Left Diaphragmatic Hernia. *N Engl J Med.* 2021; 385: 119-129.
 29. Van der Veecken L, Russo FM, De Catte L, Gratacos E, Benachi A, Ville Y, et al. Fetoscopic endoluminal tracheal occlusion and reestablishment of fetal airways for congenital diaphragmatic hernia. *Gynecological surgery.* 2018; 15: 9.
 30. Done E, Gratacos E, Nicolaides KH, Allegaert K, Valencia C, Castanon M, et al. Predictors of neonatal morbidity in fetuses with severe isolated congenital diaphragmatic hernia undergoing fetoscopic tracheal occlusion. *Ultrasound Obstet Gynecol.* 2013; 42: 77-83.
 31. Jimenez JA, Eixarch E, DeKoninck P, Bennini JR, Devlieger R, Peralta CF, et al. Balloon removal after fetoscopic endoluminal tracheal occlusion for congenital diaphragmatic hernia. *Am J Obstet Gynecol.* 2017; 217: 78e1-78e11.
 32. Jani JC, Nicolaides KH, Gratacos E, Valencia CM, Done E, Martinez JM, et al. Severe diaphragmatic hernia treated by fetal endoscopic tracheal occlusion. *Ultrasound Obstet Gynecol.* 2009; 34: 304-310.
 33. Russo FM, Cordier AG, Basurto D, Salazar L, Litwinska E, Gomez O, et al. Fetoscopic endoluminal tracheal occlusion reverses the natural history of right-sided congenital diaphragmatic hernia: a European multicenter experience. *Ultrasound Obstet Gynecol.* 2020.
 34. Al-Maary J, Eastwood MP, Russo FM, Deprest JA, Keijzer R. Fetal Tracheal Occlusion for Severe Pulmonary Hypoplasia in Isolated Congenital Diaphragmatic Hernia: A Systematic Review and Meta-analysis of Survival. *Ann Surg.* 2016; 264: 929-933.
 35. Breyssem L, Debeer A, Claus F, Proesmans M, De Keyzer F, Lewi P, et al. Cross-sectional study of tracheomegaly in children after fetal tracheal occlusion for severe congenital diaphragmatic hernia. *Radiology.* 2010; 257: 226-232.
 36. Zani A, Sellars M, Allen P, Tyraskis A, Nicolaides K, Greenough A, et al. Tracheomegaly in infants with severe congenital diaphragmatic hernia treated with fetal endoluminal tracheal occlusion. *The Journal of pediatrics.* 2014; 164: 1311-1315.
 37. Fayoux P, Hosana G, Devisme L, Deprest J, Jani J, Vaast P, et al. Neonatal

- tracheal changes following in utero fetoscopic balloon tracheal occlusion in severe congenital diaphragmatic hernia. *J Pediatr Surg*. 2010; 45: 687-692.
38. Sacco A, Van der Veecken L, Bagshaw E, Ferguson C, Van Mieghem T, David AL, et al. Maternal complications following open and fetoscopic fetal surgery: A systematic review and meta-analysis. *Prenat Diagn*. 2019; 39: 251-268.
39. Benjamin JR, Gustafson KE, Smith PB, Ellingsen KM, Tompkins KB, Goldberg RN, et al. Perinatal factors associated with poor neurocognitive outcome in early school age congenital diaphragmatic hernia survivors. *J Pediatr Surg*. 2013; 48: 730-737.
40. Danzer E, Gerdes M, D'Agostino JA, Bernbaum J, Hoffman C, Herkert L, et al. Neurodevelopmental outcome at one year of age in congenital diaphragmatic hernia infants not treated with extracorporeal membrane oxygenation. *J Pediatr Surg*. 2015; 50: 898-903.
41. Danzer E, Gerdes M, D'Agostino JA, Hoffman C, Bernbaum J, Bebbington MW, et al. Longitudinal neurodevelopmental and neuromotor outcome in congenital diaphragmatic hernia patients in the first 3 years of life. *J Perinatol*. 2013; 33: 893-898.
42. Danzer E, Hoffman C, D'Agostino JA, Gerdes M, Bernbaum J, Antiel RM, et al. Neurodevelopmental outcomes at 5 years of age in congenital diaphragmatic hernia. *J Pediatr Surg*. 2017; 52: 437-443.
43. Friedman S, Chen C, Chapman JS, Jeruss S, Terrin N, Tighiouart H, et al. Neurodevelopmental outcomes of congenital diaphragmatic hernia survivors followed in a multidisciplinary clinic at ages 1 and 3. *J Pediatr Surg*. 2008; 43: 1035-1043.
44. Leeuwen L, Walker K, Halliday R, Fitzgerald DA. Neurodevelopmental outcome in Congenital Diaphragmatic Hernia survivors during the first three years. *Early Hum Dev*. 2014; 90: 413-415.
45. Snoek KG, Capolupo I, Braguglia A, Aite L, van Rosmalen J, Valfre L, et al. Neurodevelopmental Outcome in High-Risk Congenital Diaphragmatic Hernia Patients: An Appeal for International Standardization. *Neonatology*. 2016; 109: 14-21.
46. Tracy S, Estroff J, Valim C, Friedman S, Chen C. Abnormal neuroimaging and neurodevelopmental findings in a cohort of antenatally diagnosed congenital diaphragmatic hernia survivors. *Journal of pediatric surgery*. 2010; 45: 958-965.
47. Antiel RM, Lin N, Licht DJ, Hoffman C, Waqar L, Xiao R, et al. Growth trajectory and neurodevelopmental outcome in infants with congenital diaphragmatic hernia. *J Pediatr Surg*. 2017; 52: 1944-1948.
48. Bevilacqua F, Morini F, Zaccara A, Valfre L, Capolupo I, Bagolan P, et al. Neurodevelopmental outcome in congenital diaphragmatic hernia survivors: role of ventilatory time. *J Pediatr Surg*. 2015; 50: 394-398.
49. Partridge EA, Bridge C, Donaher JG, Herkert LM, Grill E, Danzer E, et al. Incidence and factors associated with sensorineural and conductive hearing loss among survivors of congenital diaphragmatic hernia. *J Pediatr Surg*. 2014; 49: 890-894; discussion 894.
50. Ikonomidou C, Bosch F, Miksa M, Bittigau P, Vöckler J, Dikranian K, et al. Blockade of NMDA receptors and apoptotic neurodegeneration in the developing brain. *Science (New York, NY)*. 1999; 283: 70-74.
51. Lee J-R, Loepke AW. Does pediatric anesthesia cause brain damage? - Addressing parental and provider concerns in light of compelling animal studies and seemingly ambivalent human data. *Korean J Anesthesiol*. 2018; 71: 255-273.
52. Lin EP, Lee JR, Lee CS, Deng M, Loepke AW. Do anesthetics harm the developing human brain? An integrative analysis of animal and human studies. *Neurotoxicol Teratol*. 2017; 60: 117-128.
53. Van Mieghem T, Sandaite I, Michielsen K, Gucciardo L, Done E, Dekoninck P, et al. Fetal cerebral blood flow velocities in congenital diaphragmatic hernia. *Ultrasound Obstet Gynecol*. 2010; 36: 452-457.
54. Kosiv KA, Moon-Grady A, Hogan W, Keller R, Rapoport R, Rogers E, et al. Fetal cerebral vascular impedance is abnormal in left congenital diaphragmatic hernia. *Ultrasound Obstet Gynecol*. 2020.
55. Radhakrishnan R, Merhar SL, Burns P, Zhang B, Lim FY, Kline-Fath BM. Fetal brain morphometry on prenatal magnetic resonance imaging in congenital diaphragmatic hernia. *Pediatr Radiol*. 2019; 49: 217-223.
56. Lim JM, Kingdom T, Saini B, Chau V, Post M, Blaser S, et al. Cerebral oxygen delivery is reduced in newborns with congenital heart disease. *J Thorac Cardiovasc Surg*. 2016; 152: 1095-1103.
57. Masoller N, Sanz-Cortes M, Crispi F, Gomez O, Bennasar M, Egana-Ugrinovic G, et al. Severity of Fetal Brain Abnormalities in Congenital Heart Disease in Relation to the Main Expected Pattern of in utero Brain Blood Supply. *Fetal Diagn Ther*. 2016; 39: 269-278.
58. Owen M, Shevell M, Majnemer A, Limperopoulos C. Abnormal brain structure and function in newborns with complex congenital heart defects before open-heart surgery: a review of the evidence. *J Child Neurol*. 2011; 26: 743-755.
59. Khalil A, Suff N, Thilaganathan B, Hurrell A, Cooper D, Carvalho JS. Brain abnormalities and neurodevelopmental delay in congenital heart disease: systematic review and meta-analysis. *Ultrasound Obstet Gynecol*. 2014; 43: 14-24.
60. Rollins CK, Newburger JW, Roberts AE. Genetic contribution to neurodevelopmental outcomes in congenital heart disease: are some patients predetermined to have developmental delay? *Current opinion in pediatrics*. 2017; 29: 529-533.
61. Carey AS, Liang L, Edwards J, Brandt T, Mei H, Sharp AJ, et al. Effect of copy number variants on outcomes for infants with single ventricle heart defects. *Circulation Cardiovascular genetics*. 2013; 6: 444-451.
62. Wynn J, Yu L, Chung WK. Genetic causes of congenital diaphragmatic hernia. *Semin Fetal Neonatal Med*. 2014; 19: 324-330.
63. Putnam LR, Harting MT, Tsao K, Morini F, Yoder BA, Luco M, et al. Congenital Diaphragmatic Hernia Defect Size and Infant Morbidity at Discharge. *Pediatrics*. 2016; 138.
64. Tureczek I, Cafilisch J, Moehrlen U, Natalucci G, Bernet V, Latal B. Long-term motor and cognitive outcome in children with congenital diaphragmatic hernia. *Acta Paediatr*. 2012; 101: 507-512.
65. Church JT, Mon R, Wright T, Coughlin MA, Ladino-Torres M, Tapley C, et al. Neurodevelopmental outcomes in CDH survivors: A single institution's experience. *J Pediatr Surg*. 2018; 53: 1087-1091.
66. Dennett KV, Fligor BJ, Tracy S, Wilson JM, Zurakowski D, Chen C. Sensorineural hearing loss in congenital diaphragmatic hernia survivors is associated with postnatal management and not defect size. *J Pediatr Surg*. 2014; 49: 895-899.
67. Bojanic K, Woodbury JM, Cavalcante AN, Grizelj R, Asay GF, Colby CE, et al. Congenital diaphragmatic hernia: outcomes of neonates treated at Mayo Clinic with and without extracorporeal membrane oxygenation. *Paediatr Anaesth*. 2017; 27: 314-321.
68. Danzer E, Hoffman C, D'Agostino JA, Miller JS, Waqar LN, Gerdes M, et al. Rate and Risk Factors Associated with Autism Spectrum Disorder in Congenital Diaphragmatic Hernia. *Journal of autism and developmental disorders*. 2018; 48: 2112-2121.
69. Emerson E. Deprivation, ethnicity and the prevalence of intellectual and developmental disabilities. *Journal of epidemiology and community health*. 2012; 66: 218-224.
70. McManus BM, Robinson CC, Rosenberg SA. Identifying Infants and Toddlers at High Risk for Persistent Delays. *Maternal and Child Health Journal*. 2016; 20: 639-645.
71. Demirci A, Kartal M. The prevalence of developmental delay among children aged 3-60 months in Izmir, Turkey. *Child: Care, Health and Development*. 2016; 42: 213-219.