

Case Report

Acute Abdomen as Complication of a Knee Arthroscopy - A Case Report

Ana Jurin Martić^{1*}, Nenad Vidanec¹, Josko Smilovic², Matija Mavric², Miljenko Novak³ and Petra Mustač Jambrešić³

¹Department of Anesthesiology, Reanimatology and Intensive Care with ICU, County Hospital Cakovec, Croatia

²Department of Traumatology, County Hospital Cakovec, Croatia

³Department of Radiology and Ultrasound, County Hospital Cakovec, Croatia

*Corresponding author: Ana Jurin Martić, Department of Anesthesiology, Reanimatology and Intensive Care with ICU; County Hospital Cakovec, Croatia

Received: November 10, 2020; Accepted: December 03, 2020; Published: December 10, 2020

Abstract

A knee arthroscopy in spinal anaesthesia was performed on a 67 years old male patient. During the procedure the patient was hemodynamically stable, until he suddenly turned pale and started complaining of severe pain in lower abdomen with signs of guarding. The procedure was finished as urgently as possible and after releasing the tourniquet we noticed significant difference in volume of the leg, with redness distal to tourniquet. Urgent lab results were essentially unremarkable and the patient was sent for the urgent radiological diagnostics.

CD of the left leg described fluid in the soft tissues of the thigh, scrotum, and abdomen; and the unenhanced CT of the abdomen showed free fluid along the entire femoral shaft of the left thigh, extending towards pelvis and abdomen to perihepatic and perisplenic space, and retroperitoneum, with gas bubbles tracking along anterior aspect of the left thigh into the left retroperitoneum.

He was admitted to the ICU, and within few hours all symptoms have resolved and his further recovery was without complications.

Keywords: Arthroscopy Complications; Acute Abdomen; Knee Arthroscopy

Case Presentation

67 years old male patient was taken for a knee arthroscopy under spinal (subarachnoid) anaesthesia. He had a history of hyperlipidaemia and enlarged prostate. He had surgery for protrusion of the intervertebral disc L4-L5 and bile surgery 40 years ago. His BMI is 28.4kg/m².

During the procedure he was hemodynamically stable, towards the end of the procedure he suddenly turned pale and started complaining of severe pain in the lower abdomen on the left side; clinically developing signs of guarding. NG tube was placed, only the gastrointestinal-bile contents were obtained in trace amounts. Hemodynamically he was still stable (140 / 80mmHg).

The procedure was completed as quickly as possible. After releasing the tourniquet, initially set at 250mmHg, a significantly larger volume of the left leg was noted when compared to the right one, and there was redness distal to the tourniquet position. Urgent radiological diagnostics was requested with a differential diagnosis of hollow organ rupture or thromboembolic event. Abdominal X-ray in lateral decubitus position and CD of the left leg showed fluid in the soft tissues of the thigh, scrotum, and abdomen; non enhanced and contrast enhanced, venous phase CT of the abdomen and pelvis showed a free fluid along the entire left thigh around the femoral shaft, extending towards the scrotum, gluteal region, into the pelvis, and into the abdomen. Fluid was present in the perihepatic and perisplenic spaces with gas bubbles in the left retroperitoneum and anterior aspect of the left thigh.

He was admitted to the ICU for noninvasive monitoring: BP 120/80, pulse 70/ min, SpO₂ 99%, BF 19/min. Heart and lung sounds were normal, abdomen was painless, and peristalsis was audible. Left

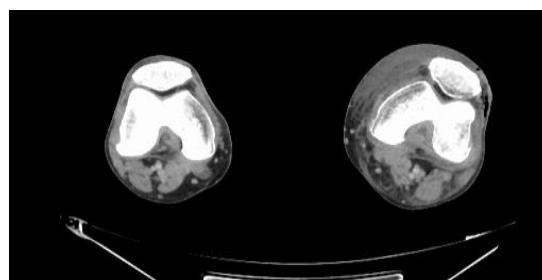


Figure 1: CT images - cross section with free gas: Patellar.

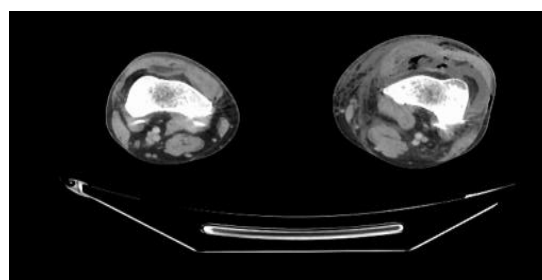


Figure 2: CT images - cross section with free gas: Thigh.

foot was oedematous with good peripheral pulsation, right foot was unremarkable.

The patient was pale and hypothermic, emergency lab was within a normal range, except for moderate compensated metabolic acidosis (bicarbonates 17, BE -7.9, lactates 1.6).

He was hemodynamically stable, excess fluid was resorbed and

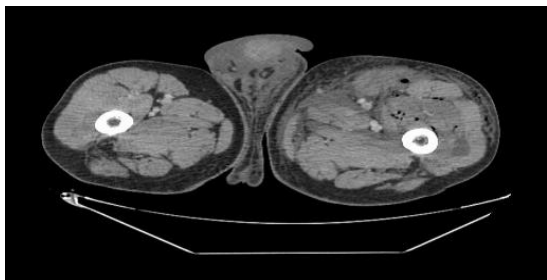


Figure 3: CT images - cross section with free gas: Upper thigh and scrotum.

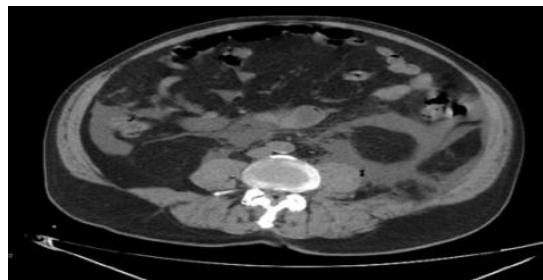


Figure 6: CT images - cross section with free gas: Abdomen.

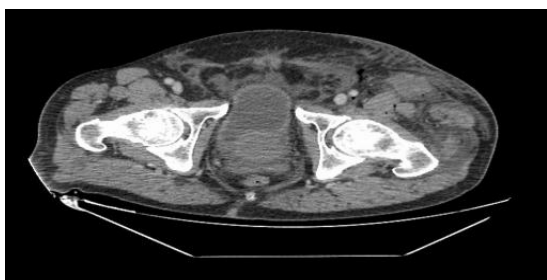


Figure 4: CT images - cross section with free gas: Hips and lower pelvis.

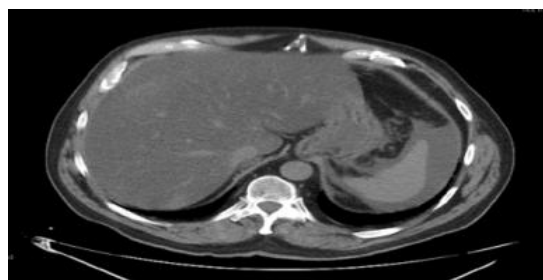


Figure 7: CT images - cross section with free gas: Abdomen: transhepatic/transsplenic cross section.

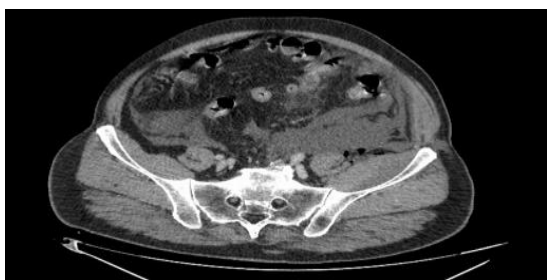

Figure 5: CT images - cross section with free gas: Pelvis.

excreted by stimulated diuresis and all of the symptoms resolved within a few hours after the surgery.

He was transferred to the ward the following day and his postoperative course was uneventful, without further complications.

Inclusive; this complication was presumably caused by a ruptured knee capsule, although we couldn't see it with arthroscope, but whether the cause of the rupture is a faulty arthroscopic pump, a tourniquet, or something else, we cannot say with certainty (both

were tested after the procedure, but we didn't find any malfunctions). The available literature shows only two similar cases, of which one did not use the tourniquet at all; in most cases with rupture of the joint capsule there was a compartment syndrome distal to the site of the tourniquet.

We believe pressure settings of the pump catalyzed formation of negative pressure which has sucked in the air visible along the leg and retroperitoneum, subsequently causing abdominal pain.

We learned that this might have been avoided if we monitored liquid balance (output should be almost equal as input) in arthroscopy more closely; therefore, we would recommend it as one of the safety measures.

In our opinion, it was fortunate we performed this arthroscopy in spinal (subarachnoid) anaesthesia, because the patient was awake and could alert us of something unexpected happening; should general anaesthesia been used, the consequences would probably be worse due to larger amount of fluid which would have been used before anything would have been noticed.