

## Special Article – Surgery Case Reports

# Nasolabial Cysts: Case Series

Riahi I, De Dorlodot CL and Philippe E\*

Department of ENT, CHU UCL Namur - Site Godinne, Belgium

\*Corresponding author: Eloy Philippe, Department of ENT, CHU UCL Namur - Site Godinne, Avenue Therasse 1, 5530 Yvoir, Belgium

Received: August 22, 2019; Accepted: September 11, 2019; Published: September 18, 2019

## Abstract

Nasolabial cyst is a rare, benign soft tissue mass located in the nasolabial fold. It is submucosal and extra osseous. It affects more commonly middle aged women with coloured skin. They can be regularly infected or cause nasal obstruction and alar deformity. Clinical examination, nasal endoscopy and imaging are necessary to make the diagnosis. When symptomatic surgery is the treatment. It may consist of a complete excision via a transoral sublabbial incision or an endonasal marsupialization. Both techniques have the same efficacy. We report herein a series of 6 patients treated successfully in the ENT department of the CHU UCL Namur from Belgium.

**Keywords:** Nasolabial cyst; Case series; Imaging; Sublabial excision; Endonasal marsupialization

## Introduction

Nasolabial cysts also called nasoalveolar cysts or Klesath tumors are rare, benign, non-odontogenic, soft tissue cysts, located in the nasolabial fold. They are submucosal and remain extraosseous [1]. The cysts are lined by respiratory epithelium, stratified squamous epithelium, pseudostratified columnar epithelium or a combination of these. They expand into and in front of the pyriform aperture, downward into the gingivolabial sulcus, and laterally into the soft tissue of the face [2]. They are usually unilateral and affected more commonly women. They have a predilection for black's people. When they are symptomatic, surgery is the treatment of choice, usually performed with a limited transoral sublabbial approach.

## Illustrative Clinical Case

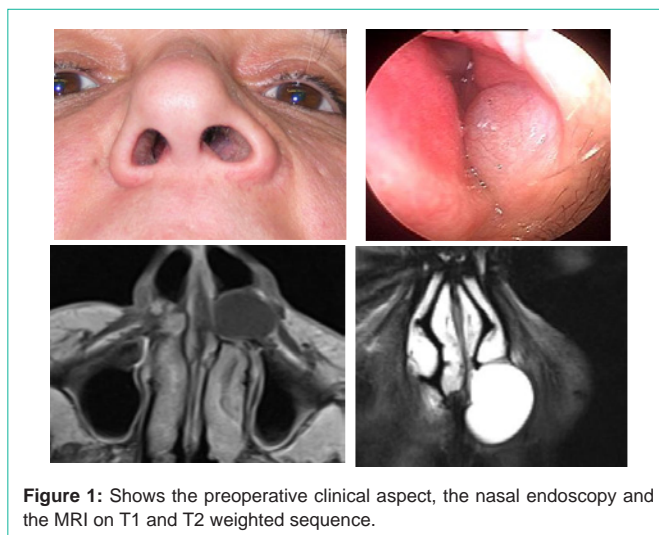
A 47 yo, heavy smoker, from Marocco, was referred to the ENT department for left nasal obstruction and alar deformity. The clinical examination confirmed a bulging of the left alar region. The nasal endoscopy visualized an expanding cystic process in the left nasal vestibule causing nasal obstruction. There is no infection. An MRI confirmed the presence of a cystic soft tissue mass located in the premaxillary region without bony erosion. (Figure 1) illustrates the lesion. The treatment consisted with a marsupialization of the lesion performed under endoscopic control. After a 1 year follow-up, the MRI confirms the absence of recurrence of the lesion. The patient is free of symptoms.

## Aim of the Paper

We report a series of 6 cases of Nasolabial cyst treated at the ENT department of the CHU UCL Namur between April 2010 and October 2019.

## Patients and Method

The table reports our cohort of patients and the modality of treatment. 2 patients were not operated as they were asymptomatic after administration of antibiotics to treat infection and despite the persistence of a lesion on MRI. 3 patients were operated transnasally with the microdebrider (Medtronic – tricut blade) because the lesion was easily accessible via the nostril. In one case the cyst was excised



**Figure 1:** Shows the preoperative clinical aspect, the nasal endoscopy and the MRI on T1 and T2 weighted sequence.

via a transoral sublabbial incision because the lesion was small and frequently infected (Table 1).

## Result

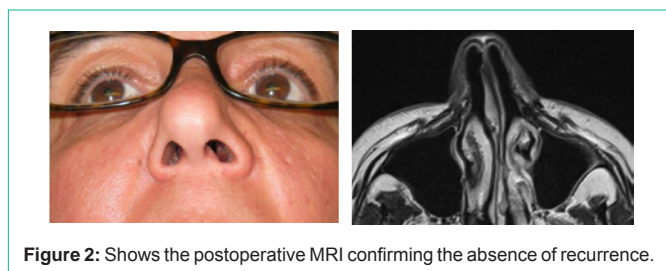
All the operated patients are free of symptoms with a follow-up of minimum 1 year. The 2 other patients were followed at the consultation every 4 months.

## Discussion

Nasolabial cysts represent about 0.7% of all cysts in the maxillofacial region, and 2.5% of non-odontogenic cysts [2]. The prevalence seems to be higher than presented in the literature as the diagnosis is often delayed [3]. Females are more frequently affected than males and particularly blacks people. 5 out of our 6 patients were originated from Marocco. The lesion is usually unilateral with no prevalence of side. We have only one patient with bilateral lesions. The prevalence of bilateral lesions is about 10% [4]. The lesion can become symptomatic because of an acute bacterial infection. In our series we have had 2 patients who had such presentation. The other patients complained of facial deformity. Indeed, the lesion can cause

**Table 1:** The table reports our cohort of patients and the modality of treatment.

| Our cohort of patients |      |            |   |                      |   |            |                                     |
|------------------------|------|------------|---|----------------------|---|------------|-------------------------------------|
| 1                      | MR   | 22/12/62   | F | Marocco Heavy smoker | Alar deformity Nasal obstruction                                | Left side  | Endonasal approach marsupialization |
| 2                      | B.L  | 07/01/58   | F | Marocco Heavy smoker | Alar deformity Nasal obstruction                                | Left side  | Endonasal approach Marsupialization |
| 3                      | M.Y. | 28/07/1955 | F | Marocco              | Alar deformity Nasal obstruction                                | Bilateral  | Endonasal approach Marsupialization |
| 4                      | F.D. | 7/12/1963  | M | Belgium              | Alar deformity during bacterial infection; resolution after Abs | Left side  | Wait & see                          |
| 5                      | L.F. | 23/03/1948 | M | Marocco              | Alar deformity during infection: resolution afr ABs             | Left side  | Wait & see                          |
| 6                      | Ab F | 7/7/1982   | F | Marocco              | Purulent secretion expressed by finger pressure                 | Right side | Sublabial incision                  |

**Figure 2:** Shows the postoperative MRI confirming the absence of recurrence.

alar nose flaring, upper lip swelling, diminished nasolabial sulcus, nasal floor elevation and greater volume in the maxillary labial sulcus. Very commonly the patient's complaint with nasal obstruction when the cyst is developed in the nasal vestibule and inferior meatus. (Figure 2) illustrates such a clinical presentation.

The diagnosis is made by the combination of the clinical examination, nasal endoscopy and imaging. The finger palpation is important to confirm that the lesion is flat and fluctuant. It can also express purulent secretion as we have observed in the 6th case. Nasal endoscopy can visualize the lesion in the nasal vestibule and appreciate the impact on the nasal patency. Imaging is necessary to confirm the cystic aspect of the lesion and to rule out any other odontogenic lesions. In the literature computed tomography is the most commonly employed imaging study [1,5]. Based on our experience MRI seems to be better to visualize the cyst, evaluate its cystic contents and analyze its relationships with the neighboring structures. The differential diagnosis must distinguish them from dental or periodontal abscess, odontogenic cyst and tumor. Management of the lesion depends on the patient's complaint. In 2 cases the patients were asymptomatic after administration of antibiotics. Despite the persistence of the lesion on MRI, a wait and see attitude was proposed after informed consent. These patients are followed at the consultation every 4 months.

In one case we performed an excision of the cyst via an intraoral sublabial approach. This was done because the cyst was small and frequently infected. The sublabial approach is the traditional approach reported in the literature [1,6,7]. For the other 3 patients we preferred to do a marsupialization of the cyst via an endonasal approach using the microdebrider and a tricut blade [1,7,8]. The

cysts had a significant size and were visualized in the nasal vestibule. This approach was successful. No recurrence was observed. In the literature both techniques have their advantages and similar efficacy [1,7,9].

## Conclusion

Nasolabial cysts are underdiagnosed soft tissue cystic lesions located in the nasolabial fold. It affects more commonly women in middle aged. The lesion is usually unilateral. It can cause alar deformity or be regularly infected. Surgery is therefore the option of treatment; Complete excision performed via an intraoral sublabial incision or a marsupialization performed via an endonasal endoscopic approaches are the 2 options with similar efficacy.

## References

1. Sheikh AB, Chin OY, Fang CH, Liu JK, Baredes S, Eloy JA. Nasolabial cysts: A systematic review of 311 cases. *Laryngoscope*. 2016; 126: 60-66.
2. Yanelba Toribio, MH Roehrl. The Nasolabial Cyst: A Nonodontogenic Oral Cyst Related to Nasolacrimal Duct Epithelium. *Archives of Pathology & Laboratory Medicine*. 2011; 135: 1499-1503.
3. Smith RA, Katibah RN, Merrell P. Nasolabial cyst: report of a case. *J Canad Dent Assoc*. 1982; 11: 727-729.
4. Patil AR, Singh AP, Nandikoor S, Meganathan P. Bilateral nasolabial cysts - case report and review of literature. *Indian J Radiol Imaging*. 2016; 26: 241-244.
5. Aquilino RN, Bazzo VJ, Faria RJA, Eid NLM, Boscolo FN. Nasolabial cyst: presentation of a clinical case with CT and MR images. *Braz J Otorhinolaryngol*. 2008; 74: 467-471.
6. Paramjit Kajla, Jeevan Lata, Reecha Agrawal. Nasolabial Cyst: Review of Literature and a Case Report. *J Maxillofac Oral Surg*. 2014; 13: 227-230.
7. Lee JY, Baek BJ, Byun JY, Chang HS, Lee BD, Kim DW. Comparison of Conventional Excision via a Sublabial Approach and Transnasal Marsupialization for the Treatment of Nasolabial Cysts: A Prospective Randomized Study. *Clin Exp Otorhinolaryngol*. 2009; 2: 85-89.
8. Su CY, Chien CY, Hwang CF. A new transnasal approach to endoscopic marsupialization of the nasolabial cyst. *Laryngoscope*. 1999; 109: 1116-1118.
9. Chao WC, Huang CC, Chang PH, Chen YL, Chen CW, Lee TJ. Management of nasolabial cysts by transnasal endoscopic marsupialization. *Arch Otolaryngol Head Neck Surg*. 2009; 135: 932-935.