

## Special Article - Laparoscopic Surgery

# Laparoscopic Management of Simple Liver Cysts

Hablus MA<sup>1</sup>, Fawzy R<sup>2</sup>, Esmail TA<sup>2\*</sup> and Elattar A<sup>1</sup>

<sup>1</sup>Department of General Surgery, Faculty of Medicine, Tanta University, Egypt

<sup>2</sup>Department of General Surgery, Faculty of Medicine, Kafr-elsheikh University, Egypt

\*Corresponding author: Esmail TA, Department of General Surgery, Faculty of Medicine, Kafr-elsheikh University, Egypt

Received: June 18, 2019; Accepted: August 14, 2019;

Published: August 21, 2019

## Abstract

This study was conducted in Tanta and Kafr-elsheikh university hospitals and included, twenty- two patients presented with simple liver cysts between April 2015 and Oct 2018.

Our aim was to evaluate, feasibility and safety of the laparoscopic management of simple liver cysts.

Laparoscopic unroofing of the cyst was the chosen technique.

**Results:** The outcome of this technique was satisfactory with minimal morbidity and no mortality, only one patient suffered from postoperative collection treated by ultrasonic guided drainage also no recurrence was experienced during the follow up period.

**Keywords:** Laparoscopic unroofing; Simple liver cysts

## Introduction

Laparoscopic management of simple liver cyst is still not popularized and selecting large accessible either superficial or exophytic peripheral lesions is the role [1].

Also, the general tendency has led to a progressive restriction and tailoring of indications for surgical treatment in benign liver tumors, selecting only patients with huge, specifically symptomatic or compressive benign tumors or patients suffering from hepatocellular tumors associated with a complicated natural history [2,3].

Deep, centrally located lesions near major vascular or biliary structures are not ideal candidates for this technique [3].

But, when comparing surgical trauma required in open hepatic surgery versus the laparoscopic approach, laparoscopy appears to be a promising technique for hepatobiliary surgeons [4,5].

Simple liver cysts located in segment VIII are more prone to early cyst recurrence after laparoscopic deroofting because the residual cyst cavity is immediately covered by the diaphragm, except if in situ omentoplasty is employed to obliterate the cystic cavity [6].

Deeply sited and posterior liver cysts are difficult to reach during laparoscopic exploration [6,7].

These patients may be good candidates for percutaneous alcohol sclerotherapy or for an open surgical approach [8].

Our aim was to evaluate, feasibility and safety of the laparoscopic management of simple liver cysts.

## Patients and Methods

This study was conducted in Tanta and Kafr-elsheikh university hospitals and included, twenty- two patients presented with simple liver cysts between April 2015 and Oct 2018.

An approval was obtained from the local ethical committee and an informed written consent was taken from all patients enrolled in this study.

A thorough history, clinical examination and routine laboratory investigations as well as abdominal ultrasound, triphasic CT study of the abdomen and tumor markers to exclude cystic tumors namely {alpha fetoprotein and CA19.9}.

Also, serology to exclude hydatid cyst is a must in all cases.

Patients with Child's-Pough C and deep or central lesions and those with history of previous liver surgery were excluded from this study.

**Operative technique:** Four laparoscopic ports were used, but their position was tailored according to the site of the cyst.

Starting by laparoscopic abdominal exploration to confirm the diagnosis and to exclude concomitant lesions or dense adhesions, extensive varices which may abort the technique and to assess the hepatic status.

The falciform, left and right triangular ligaments were taken down according to the site of the cyst to allow good exposure.

Starting with aspirating the fluid inside the cyst to decrease its size, allowing better handling and to exclude hydatid disease surely.

Cyst unroofing was the chosen technique by removing the cyst wall except the posterior one, opening all crypts and cauterization of the posterior wall and then, packing the remaining cavity with

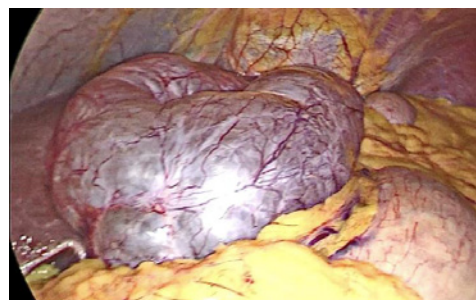


Figure 1: Large superficial simple liver cyst.

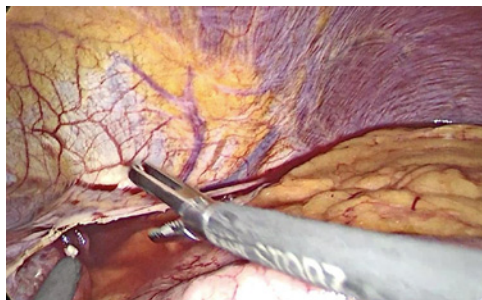


Figure 2: Division of the left triangular ligament.

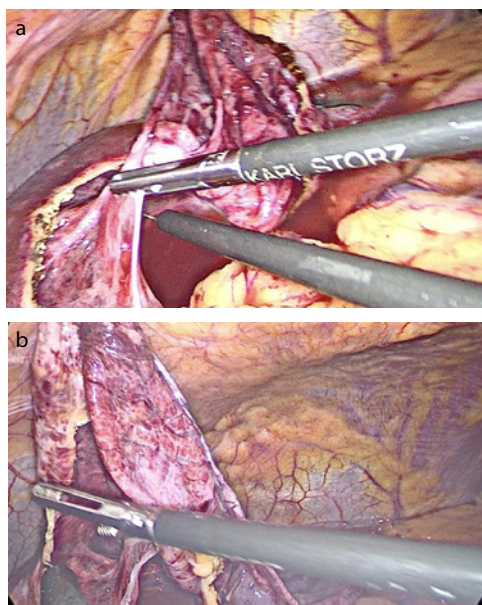


Figure 3 a,b: Stripping of the anterior wall of the cyst.

omentum.

Finally, tube drain was inserted, and the port sites were closed.

The excised cyst wall together with the aspirated fluid were sent for histopathological examination.

Follow up ranged from 6 months to three years with a mean of 20 months.

## Results

Demographic data of the patients and cysts.

## Discussion

Laparoscopic management of simple liver cysts is widely adopted nowadays, but not all of them are amenable to laparoscopic treatment C:\pmc\articles\PMC2020682\figure\F0003[2,3].

The best candidates for a laparoscopic approach being large, superficial, accessible cysts at the liver surface, located in the anterior segments of the right liver or in the left lateral liver segments [3].

Our aim was to evaluate, feasibility and safety of the laparoscopic management of simple liver cysts.

Table 1: Demographic data of the patients and cysts.

Age [yrs.]	Range [9-60]	Mean [45.5]
Sex	Male [8]	Female [14]
Size of the cyst [cm]	Range [8-18]	Mean [10]
Number of the cyst[s]	Single [22]	Multiple [0%]
	100%	
Main symptoms	Pain (90.9%)	
	Swelling (9.1%)	
Liver status:		Percentage
Cirrhotic	4 cases	[18.2%]
Non-cirrhotic	18 cases	[81.8%]

Table 2: Surgical technique used.

Intraoperative result:	
Operative time[ <i>min</i> ]	Mean [67±15]
Blood loss[ <i>ml</i> ]	Mean [20 ±7]
Conversion rate (%)	0%
Postoperative complications:	
collections	One case [4.55%]
Liver insufficiency	One case [4.55%]
recurrences	0%
Hospital stay	Range [3-7] Mean [5±1.2]

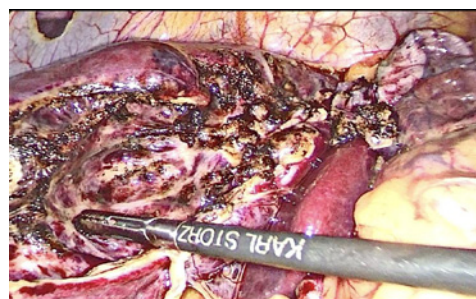


Figure 4: Cauterization of the posterior wall.

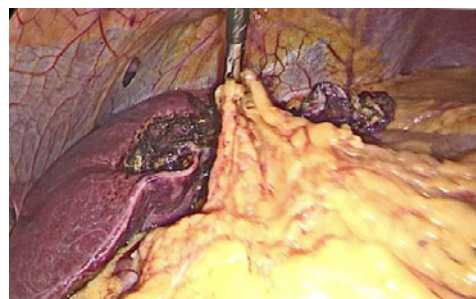

Figure 5: Packing the residual cyst cavity with omentum.

Laparoscopic unroofing of the cyst was the chosen technique {done in all cases} the outcome of this technique was satisfactory with minimal morbidity and no mortality, nor major intra-operative complications but only one patient (4.55%) suffered from postoperative collection treated by ultrasonic guided drainage

also another patient experienced manifestation of temporary liver insufficiency.

No recurrence was recorded during the follow up period. This correlates with Seong-Ryong Kim, 2012 who compared cyst unroofing with ethanol injection and concluded that laparoscopic unroofing was safer and effective than ethanol injection due to higher recurrence and possibility of acetic acid intoxication which lead to death in one case in his series [4].

Erdogan D, et al 2007 compared Percutaneous sclerotherapy for polycystic disease in 9 patients with recurrence in 7 pts (77.8%). Surgical treatment [deroofting] was undertaken in 4 pts (30.8%) with recurrence in all of them [9].

We believe that our results were satisfactory due to good selection of patients amenable for this technique and that polycystic disease possibly nictitates major liver resection.

VARDAKOSTAS D., et al; 2018 concluded that, minimally invasive techniques have been applied in simple liver cysts when became enlarged and symptomatic. The preferred methods are the laparoscopic unroofing and the percutaneous sclerotherapy, which are equally effective, but percutaneous sclerotherapy has fewer complications and attributed this to the cumulative experience in interventional radiology in their center [10].

Some authors adopted, much more simple techniques like just fenestration of the cyst, this method is easy, rapid, safe and usually is followed by rapid symptomatic relieve, but cyst recurrence is high [11,12].

Ardito F 2013 recorded radiological recurrence rate of 14.9% in his series in laparoscopic fenestration, but only 4.3% of them developed symptoms required reoperation [13].

Stanescu CA et al;2015 concluded that laparoscopic deroofting of simple liver cysts simple, efficient without recurrence (this method allows free longstanding peritoneal drainage), and safe method with minimal surgical trauma and must be the standard therapeutic approach for cystic liver diseases located in anterolateral sites of the liver [14].

## Conclusion and Recommendations

Laparoscopic unroofing of simple liver cysts is effective minimal invasive technique but large series and long follow up periods may be needed for better evaluation of this technique.

## References

1. Jean-François Gigot, Catherine Hubert,Radu Banice, Michael L Kendrick. Laparoscopic management of benign liver diseases: where are we? HPB (Oxford). 2004; 6: 197-212.
2. Gigot JF, Legrand M, Hubens G. Laparoscopic treatment of nonparasitic liver cysts: adequate selection of patients and surgical technique. World J Surg. 1996; 20: 556-561.
3. Gigot JF, Metairie S, Etienne J. The surgical management of congenital liver cysts: the need for a tailored approach with appropriate patient selection and proper surgical technique. Surg Endosc. 2001; 15: 357-363.
4. Sonographic needle aspiration. Am J Roentgenol. 1981; 136: 1065-1070.
5. Seong-Ryong Kim, Do-Sang Lee, Il-Young Park. Managements of simple liver cysts: Ablation therapy versus cyst unroofing Korean J Hepatobiliary ancreat Surg. 2012; 16: 134-137.
6. Z'graggen K, Metzger A, Klaiber C. Symptomatic simple cysts of the liver: treatment by laparoscopic surgery. Surg Endosc. 1991; 5: 224-225.
7. Weber T, Sendt W, Scheele J. Laparoscopic unroofing of nonparasitic liver cysts within segments VII and VIII: technical considerations. J Laparoendosc Adv Surg Tech A. 2004; 14: 37-42.
8. Edwards JD, Eckhauser FE, Knol JA. Optimizing surgical management of symptomatic solitary hepatic cysts. Am Surg. 1987; 53: 510-514.
9. Chun KS, Park JM, Ha HK. A huge hepatic cyst successfully treated with absolute ethanol. J Korean Radiol Soc. 1989; 25: 564-568.
10. Erdogan D, van Delden OM, Rauws EA, Busch OR, Lameris JS, Gouma DJ, et al. Results of percutaneous sclerotherapy and surgical treatment in patients with symptomatic simple liver cysts and polycystic liver disease. World J Gastroenterol. 2007; 13: 3095-3100.
11. D. VARDAKOSTAS C. DAMASKOS N. GARMPIE EA. Minimally invasive management of hepatic cysts: indications and complications. European Review for Medical and Pharmacological Sciences. 2018; 22: 1387-1396.
12. Tan YM, Chung A, Mack P. Role of fenestration and resection for symptomatic solitary liver cysts. Anz J Surg. 2005; 7: 577-580.
13. Chan CY, Tan CH, Chew SP CH. Laparoscopic fenestration of a simple hepatic cysts. Singapore Med J. 42: 268-270.
14. Ardito F, Bianco G, Vellone M, Sarno G, Ranucci G, Giovannini I. Long-term outcome after laparoscopic fenestration of simple liver cysts. Surg Endosc. 2013; 27: 4670-4674.