

Clinical Image

Gastrobronchial Fistula after Splenectomy

Foroulis CN^{1*}, Kleontas A¹, Papageorgiou T² and Anastasiadis K¹

¹Cardiothoracic Surgery, Aristotle University of Thessaloniki, Greece

²Department of Pediatrics, Hematology-Oncology Unit, Aristotle University of Thessaloniki, Greece

***Corresponding author:** Foroulis CN, Cardiothoracic Surgery, Aristotle University of Thessaloniki, AHEPA University Hospital, S. Kyriakidi 1, 54636 Thessaloniki, Greece

Received: April 23, 2019; **Accepted:** April 26, 2019;

Published: May 03, 2019

Clinical Image

A 5-year old female patient underwent vigorous splenectomy through a left-sided Kocher incision for multiple, persistent to antifungal treatment, candida splenic abscesses secondary to pulmonary and hepato-splenic candidiasis. Systemic candidiasis was developed during the course of chemotherapy for acute lymphoblastic leukemia. Following a normal initial postoperative recovery, the patient developed sepsis and the need for mechanical ventilation on 10th postoperative day. Since the intubation of the patient and the initiation of mechanical ventilation, a large amount of air escaped through the nasogastric tube. A gastro bronchial fistula was detected by a contrast study of the stomach. Gastro bronchial fistula is a rare complication of splenectomy (Figure 1). Inadvertent serosal trauma and ischemia of the larger curvature of the stomach during surgery, especially in the presence of perisplenitis, can result in sub diaphragmatic abscess formation which can further result in erosion of the hemi diaphragm and rupture within the lung parenchyma developing a gastro bronchial fistula.

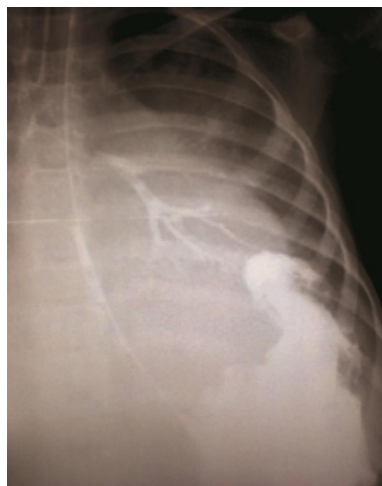


Figure 1: Contrast study of the stomach by infusion of gastrografin through the nasogastric tube results in bronchography of the left lower pulmonary lobe, confirming gastrobronchial communication.