

## Special Article - Brain Tumor Surgery

# Coccydynia: A Story Retold

Sarmast AH\*, Kirmani AR and Bhat AR

Department of Neurosurgery, Sher I Kashmir Institute of Medical Sciences, India

\*Corresponding author: Arif Hussain Sarmast, Department of Neurosurgery, Sher I Kashmir Institute of Medical Sciences, Dalipora Kawadara Srinagar Kashmir, India

Received: May 06, 2016; Accepted: October 20, 2016;

Published: October 26, 2016

## Abstract

Coccydynia refers to a pathological condition in which pain occurs in the coccyx or its immediate vicinity. The pain is usually provoked by sitting or rising from sitting. Most cases are associated with abnormal mobility of the coccyx, which may trigger a chronic inflammatory process leading to degeneration of this structure. The exact incidence of coccydynia has not been reported; however, factors associated with increased risk of developing coccydynia include obesity and female gender. Several non operative interventions are currently used for the management of coccydynia including Non-Steroidal Anti-Inflammatory Drugs (NSAIDs), hot baths, ring-shaped cushions, intrarectal massage and manipulation (manual therapy), steroid injection, dextrose prolotherapy, ganglion impar blocks, pulsed Radio Frequency Thermocoagulation (RFT) and psychotherapy. Several studies have reported good or excellent results after coccygectomy especially in patients who are refractory to conservative treatment.

**Keywords:** Coccydynia; Coccygectomy; Sacrococcygeal joint

## Introduction

The word 'coccyx' has its ancestry from the Greek word used the beak of the cuckoo bird due to remarkable resemblance in appearance when viewed from the side [1-3].

Any pain that occurs in the coccyx or its immediate vicinity is termed as coccydynia, inherently referring to varied pathological condition which gives rise to it [4]. The pain symptoms may be particularly acute when external force acts directly on the tailbone; this typically occurs during every-day activities such as sitting. Along with the bilateral ischial tuberosities, the coccyx bears the brunt of body weight during sitting. Notably, when a seated individual leans back, the weight load is borne almost entirely by the coccyx, and gives rise to classic pain syndrome when a person leans backwards [5].

Surgical treatment for coccydynia has been viewed with caution historically [4] as it has been associated with high complication rates and variable effectiveness. Better outcomes with coccygectomy have been reported more recently [6].

The term coccydynia was coined by Simpson in 1859 [7]. The pain is usually provoked by sitting or rising from sitting position as was described by Maigne et al. [8]. They found a high diagnostic value of this symptom in predicting instability. Most cases are associated with abnormal mobility of the coccyx, which may trigger a chronic inflammatory process leading to degeneration of this structure [9].

Postacchini and Massobrio described four types of configuration of the coccyx and designated them type I through type IV. In type I, the coccyx is curved slightly forward with its apex directed downward and caudally. In type II, the forward curvature is more marked and the apex extends straightforward. In type III, the coccyx most sharply angles forward (Figure 1). Finally in type IV, the coccyx is subluxated at the sacrococcygeal or intercoccygeal joint. The coccygeal configuration also appears to influence prevalence and causative lesion. Types II, III, and IV are more prone to become painful than

those with type I [10]. Anterior subluxation is a rare lesion and tends to occur in type III and type IV patterns. Posterior subluxation is more common in the straighter type I configuration [11].

Maigne et al. [11] also described four types of coccyges: rigid (with or without a spicule), normal mobility, hypermobile and dislocating.

## Incidence & Etiology

The exact incidence of coccydynia has not been reported; however, factors associated with increased risk of developing coccydynia include obesity and female gender. Women are 5 times more likely to develop coccydynia than men. Adolescents and adults are more likely to present with coccydynia than children. Anecdotally, rapid weight loss can be a risk factor because of the loss of mechanical cushioning. The most common etiology of coccydynia is external or internal trauma. External trauma usually occurs due to a backwards fall, leading to a bruised, dislocated, or broken coccyx. The location of the coccyx makes it particularly susceptible to internal injury during childbirth, especially during a difficult or instrumented delivery.

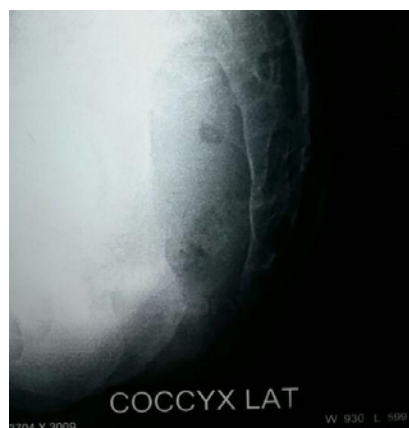


Figure 1: Coccyx Lat configuration.

Minor trauma can also occur from repetitive or prolonged sitting on hard, narrow, or uncomfortable surfaces [11-13].

However, a study conducted by Maigne et al. has suggested that only a traumatic event occurring within 1 month of onset is significant in increasing the risk of instability and subsequent coccydynia [11,14]. They demonstrated that the proportion of patients who develop instability following a traumatic event before 1 month of onset is nearly equal to the proportions that develop instability without a history of trauma (55 and 53%, respectively). By contrast, the instability rate was found to be 77.1% when the traumatic event was less than a month previously [11].

In addition, the coccygeal lesion pattern observed in obese, normal-weight, and thin coccydynia patients markedly differs. Obese patients have mainly posterior subluxation, normal-weight patients have mainly hyper mobility or radiographically normal coccyges, and thin patients have mainly anterior subluxation and spicules [11,15].

These findings suggest the following explanation. The coccyx of a leaner patient normally rotates during sitting so that the coccyx is in an optimal position to absorb the forces that are generated during this activity. As the BMI increases, the degree of pelvic rotation with sitting is reduced and the angle of incidence is increased. Consequently, the coccyx in obese patients is more susceptible to sudden elevations in intrapelvic pressure that occur with a fall and repeated sitting down. This increased exposure to pressure places the coccyx at an increased risk of posterior subluxation, which as mentioned previously is the typical post-traumatic lesion. Normal and below-normal weight patients are more likely to develop coccydynia consequent to lesion patterns other than posterior subluxation as their coccyges rotate in a more optimal fashion to lessen forces from falls and sitting [11,15].

Nontraumatic coccydynia can result from a number of causes, including degenerative joint or disc disease, hyper mobility or hypo mobility of the sacrococcygeal joint, infectious etiology, and variants of coccygeal morphology. Coccydynia can also be radicular or referred pain, although this type of pain usually is not associated with the hallmark coccygeal tenderness on physical examination. Less commonly, neoplasms have been associated with coccydynia. Coccydynia can also be associated with nonorganic causes, such as somatization disorder and other psychological disorders. Idiopathic coccydynia has been described in the absence of any obvious pathologic changes involving the coccyx, although this is considered a diagnosis of exclusion; in these patients the pain may actually result from spasticity or other abnormalities affecting the musculature of the pelvic floor [16].

### Presentation

The classic presentation of coccydynia is localized pain over the coccyx. Patients present complaining of "tailbone pain". The pain will usually be worse with prolonged sitting, leaning back while seated, prolonged standing, and rising from a seated position. Pain may also be present with sexual intercourse or defecation. History may be significant for a recent trauma with an acute onset of pain, or the onset of pain may have been insidious with no clear inciting factor. Physical examination will reveal tenderness over the coccyx, non tender coccygeal pain rules out coccydynia & should guide the examiner to look for disc disorder etc Local clinical examination should rule

out pilonidal sinus & rarely perianal abscess. Rectal examination allows the coccyx to be grasped between the forefingers and thumb. Manipulation will elicit pain and may reveal hyper mobility or hypo mobility of the sacro coccygeal joint [11]. Coccydynia is also qualified as acute or chronic. Chronic coccydynia is defined as lasting > 2 months [17].

### Differential diagnosis

The differential diagnosis of coccydynia is large and includes lumbar spondylosis or disc herniation, proctalgia fugax, levator ani syndrome, Alcock canal syndrome, descending perineal syndrome, piriformis syndrome, anogenital syndrome, perianal abscess or fistula, and rectal tumors or teratomas [18]. Tarlov cyst has been reported as a rare cause of coccydynia [19]. Care must be taken to exclude patients with offending local pathological conditions or atypical symptoms from consideration for coccygectomy. Primary coccydynia is distinguished from referred coccydynia (so-called pseudococcygodynia) [20] by infiltrating the periosteum at the tender point with 10 ml of 0.25% bupivacaine and 40 mg of methylprednisolone acetate, which will elicit temporary symptomatic relief in primary coccydynia. Although the injection provides relief of coccydynia, the results are typically quite temporary, rendering this more useful as a diagnostic tool than as a feasible long term solution. Nevertheless, repeated periosteal injections may be considered a treatment option in selected cases. Those with pseudococcygodynia should not experience relief of pain with the injection, and these patients must not be considered for coccygectomy.

### Diagnosis; imaging studies

**Dynamic radiographs:** Single position radiographs seldom demonstrate any definitive morphologic differences between normal individuals and patients with coccydynia; hence these views are not diagnostic [10]. Dynamic radiographs obtained in both the sitting and standing positions may be more useful than static X-rays because they allow for measurement of the sagittal rotation of the pelvis and the coccygeal angle of incidence. A comparison of sitting and standing films will yield radiographic abnormalities in up to 70% of symptomatic coccydynia cases [21]. Dynamic radiographs are usually taken to assess the hyper mobility of the sacrococcygeal region. The first radiograph is taken when the patient is standing for at least 10 min in order to get the coccyx in a neutral position. Then the patient is asked to sit with a straight back and thighs horizontal. Patient is asked to bend backwards until pain is reproduced and a second radiograph is taken at this point. A posterior subluxation occurs when the coccyx is pushed backwards when sitting and comes back to its normal place when standing up. A coccyx normally pivots between 5 and 25 degrees when the patient sits and returns to its original angle once the subject stands. In contrast, individuals with coccydynia frequently exhibit coccygeal displacement, immobility (<5° motion) or hyper mobility (described as flexion of >25° of motion) on lateral radiographs [14,22].

### Computed Tomography (CT) /Magnetic Resonance Imaging (MRI)

Advanced imaging modalities may be also be utilized to establish a diagnosis of coccydynia, although these techniques may not be as accurate as dynamic radiographs. Lumbosacral MRI with contrast is recommended in all patients to define normal and abnormal bony

anatomy and to rule out less common causes of coccydynia, such as abscess or tumors. CT is superior to MRI in defining normal and abnormal bony anatomy. CT should be ordered in cases of acute pelvic trauma, and as an adjunct to MRI in evaluating neoplastic disease. Magnetic Resonance Imaging (MRI) and technetium Tc-99m bone scans may demonstrate inflammation of the sacrococcygeal area indicative of coccygeal hyper mobility. Provocative testing of the coccyx, such as pressing on the region with a blunted needle to elicit pain, and pain relief with the injection of local anesthetic under fluoroscopic guidance may also be useful in diagnosis as well [14,23].

### Non operative management

Several non operative interventions are currently used for the management of coccydynia including Non-Steroidal Anti-Inflammatory Drugs (NSAIDs), hot baths, ring-shaped cushions, intrarectal massage and manipulation (manual therapy) steroid injection, dextrose prolotherapy, ganglion impar blocks, pulsed Radio Frequency Thermo coagulation (RFT), corticosteroid and methylene blue injections, intradiscal injections, intradiscal electro thermal therapy and psychotherapy [16,24-32].

One possible mechanism for persistent coccydynia is excessive activity or sensitivity of the ganglion impar, thus creating sympathetically maintained coccyx pain [30]. Injection therapies utilized in the management of coccydynia involve the following possible mechanisms of pain relief: anti-inflammatory effects [31], formation of scar tissue [27], and inhibition of the ganglion impar [17]. Local injection of an anesthetic can effectively block the ganglion impar and thereby relieve coccyx pain. In a published report by Foye and colleagues, nerve blocks using local anesthetics with a fast onset (e.g., lidocaine) were shown to provide substantial relief even by the time a patient sat up on the procedure table [29]. After the local anesthetic block wears off, some of the coccyx pain may start to return, but generally it returns at a much lower severity than existed prior to the injection. Physical medicine and rehabilitation coccydynia physicians and researchers at New Jersey Medical School refer to this new plateau of severity as “resetting the thermostat”. Published reports document that some patients with coccydynia receive complete and permanent relief *via* a single ganglion impar block [29].

Thermo coagulation of the ganglion impar using Radiofrequency Ablation (RFA) has been reported [31,33,34]. Ablation can also be accomplished chemically (e.g., by carefully injecting neurotoxic agents such as phenol and/or ethyl alcohol directly onto the targeted nerve tissues). These coccygeal ablation injections have been in clinical use for multiple decades and thus are no longer considered experimental [1]. Ablation is typically reserved for patients whose pain has failed to be adequately relieved *via* oral analgesic medications, cushions, coccyx steroid injections, and coccygeal sympathetic nerve blocks (ganglion impar).

Maigne et al. [24] reported intra rectal manipulation had only mild effectiveness in the treatment of chronic coccydynia and tended to be more successful in patients with post-traumatic etiology, a stable coccyx, and shorter duration of symptoms. Khatri et al. [25] reported that intra rectal manipulation was effective for treating idiopathic coccydynia. However, in their methods they did not adequately control for the use of analgesics, which threatens the validity of

their conclusion. Two investigators performed manipulation in the sagittal plane [24,26] while one chose to manipulate the coccyx in the coronal plane [25]. Two studies included massage to the levatorani as part of the manual therapy provided [24,26], however, the role of the levatorani muscle in coccydynia is an area for further research. In only one study was intra rectal manipulation performed by a physiotherapist [27].

For patients who do not respond to these forms of intervention, coccygectomy is often recommended. Willems P et al. [35] however in their study consistently showed a lack of consensus among spine surgeons in surgical decision making. Despite high levels of training and continuous medical education, patient selection for fusion surgery in the treatment of chronic low back pain does not have a uniform evidence base in clinical practice.

### Operative management-Coccygectomy

Several studies have reported good or excellent results after coccygectomy [3,10,36-47].

### Surgical Technique

#### Preoperative preparation

Before being listed for coccygectomy, each patient must have failed medical therapy and nonsurgical treatment. This includes the failure of Manipulation Under Anesthetic (MUA) and at least 2 attempts at local anesthetic and steroid infiltration [48].

Usually a low-residue diet is started 5 days prior to surgery and a fleet enema is given 24 hrs before or on the day of the surgery. Some surgeons start low residue diet just 1 day before surgery. An increased risk of wound infection after coccygectomy has been reported; therefore, preoperative antibiotics are given after induction of anesthesia. Anecdotally, this is due to the anatomical region where the surgery is performed.

#### Position

Patient is put in prone position on bolsters, or on a Wilsons frame and the operation table is flexed at the patient's waist. Both buttocks are separated by a hard tape to expose the area properly. The coccygeal region and anus are prepared with iodine or chlorhexidine. The skin is infiltrated with lidocaine and epinephrine. Lateral fluoroscopic images are used to locate the sacro coccygeal junction. Most surgeons prefer median longitudinal incision starting above the sacro coccygeal joint and extending down to the coccyx. Care should be taken not to extend the incision near perianal skin. The incision is deepened through the fascia and gluteus muscles until the bone is felt. With blunt dissection, the tip of the coccyx is located. The sacro coccygeal disc is removed or osteotomized in the case of a synchondrosis. The coccygeal vessels on each side are ligated or cauterized. The anococcygeal ligament is incised and the tip of the coccyx is elevated. The coccygeus and ileococcygeus muscles are dissected through muscle attachments and incised carefully, protecting the rectum. All segments and layers of the coccyx including the periosteum are excised.

Some surgeons prefer to create a subperiosteal plane on both sides of tip by sharp dissection and leave the ligamentous and muscular attachments along with periosteum behind. coccyx is separated from the surrounding tissues in a subperiosteal plane using monopolar electro cautery, elevating the coccyx posterior, and proceeding with an

en bloc resection in a rostra to caudal direction according the method of Key [49]. Dissection from a proximal to distal direction limits the risk of rectal injury, especially in the case of an anteverted coccyx. En bloc resection prevents treatment failures secondary to incomplete resection. The results of a recent study show that periosteum preservation and closure result in low risk of postoperative infection. Care is taken in excising the coccyx as it lies close to the rectum. Gardener described a technique in mobilizing the rectum and dense fascia deep to sacro coccygeal joint with advantages of protecting the rectum, less risk of infection, and more rapid healing [42]. After the coccyx is removed the distal prominent end of the sacrum is beveled. A complete resection may be ascertained by examining the resected specimen and by checking a lateral C-arm fluoroscopic radiograph to ensure complete resection compared with preoperative imaging. The dead space is obliterated by drawing the cut ends of aponeurotic tissues in the midline, and applying two to four mattress stitches with absorbable sutures. The subcutaneous and skin is closed in layers. Usually a small drain is placed if the dead space is left and a small dressing is applied [42,48].

Nevertheless, wound infection is the most important complication of this procedure. Apart from total coccygectomy, a partial resection of the coccyx has also been described for the surgical treatment of coccydynia. Postacchini reported no difference in the outcome for partial resection compared to that of complete coccygeal resection [10]. However, other authors have demonstrated superior postoperative outcomes with complete coccygectomy in comparison to partial coccygectomy [40]. In our series, only a complete resection was performed.

## Complications

Coccygectomy may seem to be a technically facile procedure. However, myriad complications have been documented in the extant literature. In a review of 24 studies involving 671 patients, an overall 11% complication rate has been reported. Complication rates in studies varied from 0% [49] to 50% [50]. The most common complications cited were: wound infections (8.34%), and wound healing problems with dehiscence. Delayed healing (0.9%) and wound hematomas (0.3%) were also reported [6]. Wound infections were in the majority of cases superficial. Serious complications, such as severe infections or injuries of the intestinal tract, rectal prolapsed etc have also been described; however, these were extremely rare [6]. In myriad studies, perioperative antibiotic prophylaxis was administered. The local skin flora, proximity to the anus, and hygiene difficulties due to the anatomical location of the operative site increases the risk of contamination. The most common causative agents of postoperative wound infection were gram-negative rods [31]. Several studies have shown that a five-day course of postoperative antibiotics (second-generation cephalosporins) can effectively reduce the infection rate [22,41,46,50].

Doursounian L et al. [51] in their study of 136 coccygectomy patients proposed the use of a topical skin adhesive on the postoperative wound as a significant contributor in preventing post operative infections.

## References

- Howarth B. The painful coccyx. *Clin Orthop*. 1959; 14: 145-160.
- Sugar O. Coccyx. The bone named for a bird. *Spine (Phila Pa 1976)*. 1995; 20: 379-383.
- Pennekamp PH, Kraft CN, Stutz A, Wallny T, Schmitt O, Diedrich O. Coccygectomy for coccygodynia: does pathogenesis matter? *J Trauma*. 2005; 59: 1414-1419.
- Duncan GA. Painful coccyx. *Arch Surg*. 1937; 34: 1088-1104.
- Johnson PH. Coccygodynia. *J Ark Med Soc*. 1981; 77: 421-424.
- Karadimas EJ, Trypsiannis G, Giannoudis PV. Surgical treatment of coccygodynia: an analytic review of the literature. *Eur Spine J*. 2011; 20: 698-705.
- Powers JA. Coccygectomy. *South Med J*. 1957; 50: 675-678.
- Maigne JY, Tamalet B. Standardized radiologic protocol for the study of common coccygodynia and characteristics of the lesions observed in the sitting position. Clinical elements differentiating luxation, hypermobility, and normal mobility. *Spine*. 1996; 21: 2588-2593.
- Patel R, Appannagari A, Whang PG. Coccydynia. *Curr Rev Musculoskelet Med*. 2008; 1: 223-226.
- Postacchini F, Massobrio M. Idiopathic coccygodynia. Analysis of fifty-one operative cases and a radiographic study of the normal coccyx. *J Bone Joint Surg*. 1983; 65: 1116-1124.
- Maigne JY, Doursounian L, Chatellier G. Causes and mechanisms of common coccydynia: role of body mass index and coccygeal trauma. *Spine (Phila Pa 1976)*. 2000; 25: 3072-3079.
- Maigne JY, Pigeau I, Aguer N, Doursounian L, Chatellier G. Chronic coccydynia in adolescents. A series of 53 patients. *Eur J Phys Rehabil Med*. 2011; 47: 245-251.
- Schapiro S. Low back and rectal pain from an orthopedic and proctologic viewpoint; with a review of 180 cases. *Am J Surg*. 1950; 79: 117-128.
- Fogel G, Cunningham P, Esses S. Coccygodynia: evaluation and management. *J Am Acad Orthop Surg*. 2004; 12: 49-54.
- Van Deursen LL, Patijn J, Durinck JR, Brouwer R, van Erven-Sommers JR, Vortman BJ. Sitting and low back pain: the positive effect of rotary dynamic stimuli during prolonged sitting. *Eur Spine J*. 1999; 8: 187-193.
- Nathan ST, Fisher BE, Roberts CS. Coccydynia: a review of pathoanatomy, aetiology, treatment and outcome. *J Bone Joint Surg Br*. 2010; 92: 1622-1627.
- Mlitz H, Jost W. Coccygodynia. *J Dtsch Dermatol Ges*. 2007; 5: 252-254.
- Schrot RJ. Coccygodynia. *Epocrates Online*.
- Ziegler DK, Batnitzky S: Coccygodynia caused by perineural cyst. *Neurology*. 1984; 34: 829-830.
- Traycoff RB, Crayton H, Dodson R. Sacrococcygeal pain syndromes: diagnosis and treatment. *Orthopedics*. 1989; 12: 1373-1377.
- Maigne JY, Guedj S, Straus C. Idiopathic coccygodynia. Lateral roentgenograms in the sitting position and coccygeal discography. *Spine*. 1994; 19: 930-934.
- Maigne JY, Lagache D, Doursounian L. Instability of the coccyx in coccydynia. *J Bone Joint Surg Br*. 2000; 82: 1038-1041.
- Maigne JY, Pigeau I, Roger B. Magnetic resonance imaging findings in the painful adult coccyx. *Eur Spine J*. 2012; 21: 2097-2104.
- Maigne J, Chatellier G, Le Faou M, Archambeau M. The treatment of chronic coccydynia with intrarectal manipulation: a randomized controlled study. *Spine*. 2006; 31: E621-627.
- Khatri SM, Nitsure P, Jatti RS. Effectiveness of coccygeal manipulation in coccydynia: a randomized control trial. *Indian J PhysiotherOccupTher*. 2011; 5: 110-112.
- Wu CL, Yu K, Chuang H, Huang M, Chen T, Chen C. The application of infrared thermography in the assessment of patients with coccygodynia

- before and after manual therapy combined with diathermy. *J Manipulative PhysioTher.* 2009; 32: 287-293.
27. Khan SA, Kumar A, Varshney MK, Trikha V, Yadav CS. Dextrose prolotherapy for recalcitrant coccygodynia. *J OrthopSurg (Hong Kong).* 2008; 16: 27-29.
  28. Datir A, Connell D. CT-guided injection for ganglion impar blockade: a radiological approach to the management of coccydynia. *Clin Radiol.* 2010; 65: 21-25.
  29. Demircay E, Kabatas S, Cansever T, Yilmaz C, Tuncay C, Altinors N. Radiofrequency thermo coagulation of ganglion impar in the management of coccydynia: preliminary results. *Turk Neurosurg.* 2010; 20: 328-333.
  30. Oh CS, Chung IH, Ji HJ, Yoon DM. Clinical implications of topographic anatomy on the ganglion impar. *Anesthesiology.* Jul. 2004; 101: 249-250.
  31. Mitra R, Cheung L, Perry P. Efficacy of fluoroscopically guided steroid injections in the management of coccydynia. *Pain Physician.* 2007; 10: 775-778.
  32. Itz CJ, Willems PC, Zeilstra DJ, Huygen FJ. Dutch Multidisciplinary Guideline for Invasive Treatment of Pain Syndromes of the Lumbosacral Spine. *Pain Pract.* 2016; 16: 90-110.
  33. Atim A, Ergin A, Bilgiç S, Deniz S, Kurt E. Pulsed radiofrequency in the treatment of coccygodynia. *Agri.* 2011; 23: 1-6.
  34. Reig E, Abejon D, del Pozo C, Insausti J, Contreras R. Thermocoagulation of the ganglion impar or ganglion of Walther: description of a modified approach. Preliminary results in chronic, nononcological pain. *Pain Pract.* 2005; 5: 103-110.
  35. Willems P, de Bie R, Oner C, Castelein R, de Kleuver M. Clinical decision making in spinal fusion for chronic low back pain. Results of a nationwide survey among spine surgeons. *BMJ open.* 2011; 1: e000391.
  36. Balain B, Eisenstein SM, Alo GO, Darby AJ, Cassar-Pullicino VN, Roberts SE, et al. Coccygectomy for coccydynia: case series and review of literature. *Spine (Phila Pa 1976).* 2006; 31: E414-E420.
  37. Bayne O, Bateman JE, Cameron HU. The influence of etiology on the results of coccygectomy. *ClinOrthop.* 1984; 190: 266-272.
  38. Doursounian L, Maigne JY, Faure F, Chatellier G. Coccygectomy for instability of the coccyx. *Int Orthop.* 2004; 28: 176-179.
  39. Grosso NP, van Dam BE. Total coccygectomy for the relief of coccygodynia: a retrospective review. *J Spinal Disord.* 1995; 8: 328-330.
  40. Hellberg S, Strange-Vognsen HH. Coccygodynia treated by resection of the coccyx. *Acta Orthop Scand.* 1990; 61: 463-465.
  41. Hodges SD, Eck JC, Humphreys SC. A treatment and outcomes analysis of patients with coccydynia. *Spine J.* 2004; 4: 138-140.
  42. Key JA. Operative treatment of coccygodynia. *J Bone Joint Surg Am.* 1973; 19: 759-764.
  43. Perkins R, Schofferman J, Reynolds J. Coccygectomy for severe refractory sacrococcygeal joint pain. *J Spinal Disord Tech.* 2003; 16: 100-103.
  44. Pyper JB. Excision of the coccyx for coccydynia; a study of the results in twenty-eight cases. *J Bone Joint Surg Br.* 1957; 39: 733-737.
  45. Sehirlioglu A, Ozturk C, Oguz E, Emre T, Bek D, Altinmakas M. Coccygectomy in the surgical treatment of traumatic coccygodynia. *Injury.* 2007; 38: 182-187.
  46. Wood KB, Mehbood AA. Operative treatment for coccygodynia. *J Spinal Disord Tech.* 2004; 17: 511-515.
  47. Wray CC, Easom S, Hoskinson J. Coccydynia. Aetiology and treatment. *J Bone Joint Surg Br.* 1991; 73: 335-338.
  48. Lyons M. Coccygodynia: background. *Medscape Reference, Drugs, Diseases and Procedures Web site.* 2012.
  49. Traub S, Glaser J, Manino B. Coccygectomy for the treatment of therapy-resistant coccygodynia. *J Surg Orthop Adv.* 2009; 18: 147-149.
  50. Cebesoy O, Guclu B, Kose KC, Basarir K, Guner D, Us AK. Coccygectomy for coccygodynia: do we really have to wait? *Injury.* 2007; 38: 1183-1188.
  51. Doursounian L, Maigne JY, Cherrier B, Pacanowski J. Prevention of post-coccygectomy infection in a series of 136 coccygectomies. *Int Orthop.* 2011; 35: 877-881.