

Research Article

Surgical Exploitation of Venous Interconnections in Upper Limb for Creation of Arteriovenous Vascular Access for Hemodialysis

Elamaran E^{1*} and **Hemachandar R²**¹Department of Cardiothoracic and Vascular Surgery, Sri Balaji Vidayapeeth University, India²Department of Nephrology, Sri Balaji Vidayapeeth University, India

***Corresponding author:** Elamaran E, Department of Cardiothoracic and Vascular Surgery, Mahatma Gandhi Medical College and Research Institute, Sri Balaji Vidayapeeth University, Pondicherry, India

Received: July 19, 2016; **Accepted:** August 31, 2016;**Published:** September 06, 2016**Abstract**

Aim: This article describes our experience of Arterio Venous (AV) vascular access creation for hemodialysis (HD) and its outcomes.

Results: A total of 107 AV vascular accesses were created in 102 patients from September 2014 to December 2015. Mean follow-up duration was 12 months. The preferred hand was left in 73 (68.22%) patients compared to the right hand 34 (31.77%). Cephalic vein was used in 63 (58.88%) patients, median basilic or antecubital vein in 30 (28.04%) cases, median vein of forearm in 3 (2.80%) cases, saphenous vein in 3 (2.80%), accessory cephalic vein 2 (1.87%) and AV graft in 6 (5.61%) patients. End (vein) to side (artery) anastomosis was done in 39 (36.45%) cases and side to side anastomosis was done in 68 (63.55%) cases. Complications include distal edema in 8 (7.48%) patients, seroma in 2 (1.87%), hematoma in 2 (1.87%), surgical site infection in 2 (1.87%), aneurysm in 4 (3.74%) and skin necrosis in 1 (0.93%) patient. Primary failure occurred in 9 (8.41%) patients due to thrombosis and non maturation and secondary failure due to thrombosis in 6 (5.61%) patients.

Conclusion: Venous interconnections of the upper limb provides vascular surgeon an opportunity for successful construction of native Arteriovenous Fistula (AVF) when conventional sites were exhausted.

Keywords: Vascular access; Venous interconnections; Arteriovenous fistula

Introduction

Vascular access is considered as the Achilles heel of hemodialysis. Though AVF is the most ideal vascular option available, AVF could not be created in many patients due to poor quality of blood vessels from prior venipuncture, cannulation, poor calibre of vessels and arteriosclerosis. Though AVG has its own advantages, it is more costly and has more complications than AVF. Hence we exploited the variations of venous anatomy in upper limb to create AVF in all patients. In this context, we analysed AVF creation procedures, its complications and outcomes.

Materials and Methods

This prospective observational single centre study was carried out in our institute from September 2014 to December 2015. Patients were assessed for their feasibilities of AVF creation by physical examination of superficial venous system and Allen test which assesses the arterial competence of palmar arch. Preoperative venous mapping was done in selected patients in whom physical examination was not contributory. All vascular accesses procedures were performed by a single vascular surgeon. We tried to utilise the various venous interconnections in the forearm and cubital fossa to create AVF, thereby Avoiding Arteriovenous Graft (AVG) which is 5-6 times costlier than AVF in our centre. Synthetic AV graft was done in the last resort only after exhausting all native veins for fistula creation.

Operative procedure

The venous drainage of upper limb has a lot of variations which was exploited in creation of AVF, thereby reducing the need for AVG creation. The venous interconnections which were used for AVF creation includes cephalic vein and accessory cephalic vein at the wrist; cephalic vein, and median vein of forearm at the mid forearm, cephalic vein, median cubital vein, medial cephalic and basilic vein at the elbow; cephalic vein, basilic vein in the arm (Figure 1).

The procedure was done under local anaesthetic (2% Xylocaine+0.25% Bupivacaine) injection. The anaesthetic agent was injected between the radial artery and cephalic vein during radio cephalic AVF creation and centering the brachial artery pulsation for Brachio-cephalic AVF creation. Regional anaesthesia was used for Brachio-basilic AVF with transposition. The arteriotomy size varies according to the inflow vessel (radial artery 6 - 8 mm, brachial artery 5 - 6mm). Both end to side anastomosis and side to side anastomosis with one end ligation was used in AVF creation. Side to side anastomosis with distal vein ligation was done during radio cephalic AVF creation. Side to side anastomosis with proximal ligation of basilic vein was done during creation of brachio cephalic AVF through median cubital or median basilic vein, whereas end to side anastomosis was done in brachio cephalic AVF. The modifications in AVF creation adapted in the present series includes at the wrist: ligation of oblique vein at the wrist, in the forearm: ligation of multiple tributaries to the main outflow vein in the forearm and in

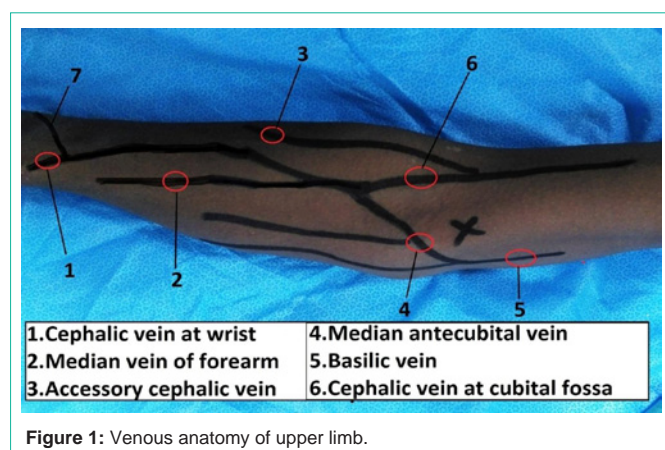


Figure 1: Venous anatomy of upper limb.

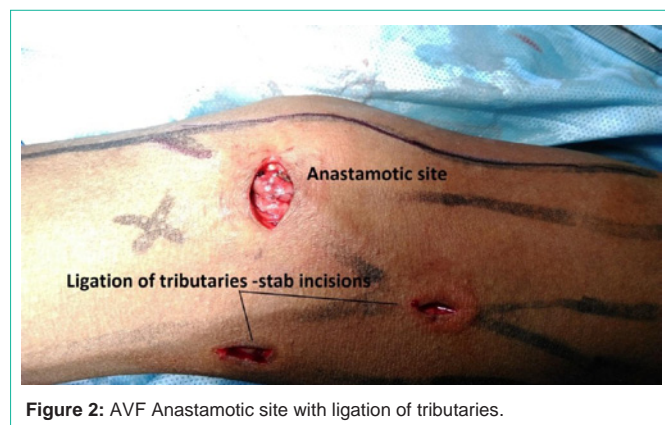


Figure 2: AVF Anastomotic site with ligation of tributaries.

the elbow: ligation of the perforating vein, one of the main superficial veins (cephalic and basilic) and tributaries from forearm to cubital fossa. These tributaries were ligated through multiple stab incisions (Figure 2).

The idea behind the above described modifications in AVF creation is to augment the flow of blood to the outflow vein thereby enabling early maturation and to better patency rates. This will also prevent development of venous hypertension, steal phenomenon and high output cardiac failure. When the arterIALIZED vein dilates, the tributaries with valves may become incompetent. Also if the functioning fistula develops stenosis or thrombosis, the segment of veins distal to the lesion may open up and lead to development of venous hypertension.

Isometric exercise was initiated after 6 hours of the procedure in all the patients. Patients were prescribed on low dose aspirin (75 mg) for one month. Patients were followed every 2 weeks after the procedure, till the cannulation of the access could work.

Primary failure was defined as fistula thrombosis, or failure to mature resulting in inadequate functioning for hemodialysis in 6 weeks.

Results

From September 2014 to December 2015, 107 AV access procedures were done in 102 patients. There were 78 (76.47%) males and 24 (23.53%) females. The mean age of patients was 51.41 years ranging from 17 to 87 years-old. The co-morbidities include

diabetes mellitus in 43 (42.16%) patients, hypertension in 86 (84.31%), ischemic heart disease in 23 (22.55%) and malignancy in 2 (1.96%) patients. The etiology of chronic kidney disease included was unknown cause in 46 patients (45.10%), diabetic nephropathy in 35 (34.31%) patients, hypertensive nephropathy in 10 (9.80%) patients, chronic interstitial nephritis in 3 (2.94%) patients, chronic glomerulonephritis in 6 (5.88%) patients, and polycystic kidney disease in 2 (1.96%) patients. Only 6 patients (5.88%) underwent AV access creation in the predialysis stage whereas the rest 94.12% had their AV access created after the initiation of dialysis through temporary catheter. Five (4.67%) underwent second AVF creation due to prior fistula failure. The average follow-up period was 12 months ranging from 4 to 20 months?

AV access in our series include native AVF in 101 (94.39%) and AV graft in 6 (5.61%). AV access was created in right limb in 34 (31.77%) patients and left limb in 73 (68.22%) patients. AVF was created at wrist in 34 (31.78%) patients, midforearm in 3 (2.80%), arm in 61 (57.01%) and saphenous vein translocation in 1 (0.93%) patient.

Cephalic vein was used in 63 (58.88%) patients, median basilic or antecubital vein in 28 (26.17%) cases, basilic vein in 2 (1.87%) patients, median vein of forearm in 3 (2.80%) cases, saphenous vein in 3 (2.80%), accessory cephalic vein 2 (1.87%) and AV graft in 6 (5.61%). Inflow arteries used for AVF creation included radial artery in 37 (34.58%) patients, brachial artery in 62 (57.94%) patients, and posterior tibial artery in 2 (1.87%) patients. Inflow artery used for AVG creation were ulnar artery in 1 (0.93%) patient, brachial artery bifurcation in 1 (0.93%) patient and brachial artery in 4 (3.74%) patients. End (vein) to side (artery) anastomosis was done in 39 (36.45%) cases and side to side anastomosis was done in 68 (63.55%) cases. Thrill was present in 100 (93.46%) cases during the operation period.

Surgical complications included distal edema in 8 (7.48%) patients, seroma in 2 (1.87%) patients, hematoma in 2 (1.87%) patients, surgical site infection in 2 (1.87%) patients, and skin necrosis in 1 (0.93%) patient. Late complications include aneurysm formation in 4 patients (3.74%), distal steal phenomena in 1 (0.93%) patient, and AVG infection in 1 (0.93%) patient. Primary failure occurred in 9 (8.41%) patients due to thrombosis and maturation failure. Secondary failure occurred in 6 (5.61%) patients due to thrombosis and aneurysm. None of our patients had undergone any salvage procedure due to the high costs associated with such procedures in our centre.

Discussion

A functioning vascular access is the key to successful management of hemodialysis patients. Despite advances in the hemodialysis technology over years, vascular access continues to be a major determinant of morbidity and mortality for these patients. Native arteriovenous fistula is considered to be the ideal access of choice in most dialysis patients [1]. AVG has higher rates of access events, infections, greater mortality risk, and high costs of implantation compared to native fistula [2].

The most common etiology of chronic kidney disease in our series was unknown cause in 45.10% followed by diabetic nephropathy in 34.31% of patients. Due to poor predialysis care in our country, most

Table 1: Order of preference of AVF creation.

S.No	Ascending order of AVF creation
1	Radio cephalic AVF at wrist
2	Radio cephalic at mid forearm
3	Radio-Median vein of forearm at mid forearm
4	Radio Accessory cephalic AVF at wrist
5	Brachio cephalic AVF at cubital fossa
6	Brachio cephalic AVF through median antecubital vein
7	Brachio basilic AVF with transposition
8	Autogenous AV Graft in the arm
9	Lower limb AVF
10	Synthetic AVG

Table 2: Distribution of AVF.

Cephalic vein at wrist & forearm	32 (29.90%)
Accessory cephalic vein at wrist	2 (1.87%)
Median vein of forearm	3 (2.80%)
Cephalic vein at cubital fossa	31 (28.97%)
Median antecubital vein	28 (26.17%)
Basilic vein	2 (1.87%)
Saphenous vein	3 (2.80%)

of our patients were initiated on emergency hemodialysis through temporary catheter.

The KDOQI recommended order of preference for placement of fistulae in hemodialysis patients should be (in descending order of preference) wrist (radiocephalic) primary fistula, elbow (brachiocephalic) primary fistula, transposed brachial basilic vein fistula followed by AVG of synthetic or biological material [2]. The guidelines discourage the use of AVG and strongly recommend the creation of native AVF [2]. Our idea is also to create AVF in all patients by exploiting the multiple venous interconnections and their variations in the upper limb. AVG was used as the last option only in patients with no suitable vein in both upper and lower limbs.

When radio cephalic fistula was not feasible, instead of creating brachiocephalic AVF in elbow, we exploited the forearm venous interconnections for creating AVF thereby preserving proximal veins for future use. When brachiocephalic AVF was not feasible, instead of brachio basilic AVF with transposition, we exploited the cubital fossa venous interconnections for creating brachiocephalic AVF through median cubital vein. In patients with no suitable veins in upper limb for AVF creation, we tried using lower limb veins for AVF creation.

Beathard GA et al. reported accessory veins in 46% of patients with non maturation and accessory vein ligation resulted in 100% success rate [3]. We identified and ligated the tributaries draining to the outflow vein in all patients which aided in maturation of fistula in our thought.

Apart from conventional sites of AVF creation, many authors have suggested alternative sources (artery and vein) for AVF creation. Jennings WC reported successful creation of proximal radial artery arteriovenous fistula when wrist AVF was not feasible [4]. We have used proximal radial artery similarly in 3 (2.80%) patients. Pantea and

Bengulescu described creation of brachiocephalic fistula by using the median basilic vein continued with the median cephalic vein to create a smooth loop between the brachial artery and the cephalic vein, which has been adapted by us in 28 (26.17%) patients [5].

According to Shibutani S et al. Brachio basilic AVF with transposition is a complex procedure with satisfactory patency rates (89.7% at 1 year) and fewer postoperative complications. This technique was initiated in 2 (1.87%) of our patients [6].

Our Primary failure rate (8.41%) was much lower than compared to 15 -30% failure rates reported in most large volume centres [7,8]. Our strict criteria of selecting veins and ligation of tributaries to the outflow vein could have resulted in better success rate in our patients. Primary failure was more common in diabetes, atherosclerosis and elderly (> 60 years). Sahasrabudhe et al. reported that primary failure was common in distal fistulas, radial artery fistulas, and in diabetics [7]. Presence of thrill on table was the only factor that correlated with successful maturation of AVF in our series (Tables 1 & 2).

Distal limb edema (7.48%) was the most common complication in our study. Aneurysm occurred in 3.47% of our patients whereas the reported incidence in literature ranged from 6.6% to as high as 51% [9,10]. None of our patients developed fistula infection whereas Derakhshanfar A et al. reported 4.4% rate of fistula infection [9].

Conclusion

Every vascular access that fails gets the patient one step closer to a terminal point where all roads seem closed. Creation of the preferred AVF configurations may not be possible in all patients due to limited inflow and outflow vessels. Our study shows that exploiting the multiple venous interconnections in the upper limb for AVF creation with certain modifications could avoid AVG and catheter dependence.

References

- Ethier J, Mendelssohn DC, Elder SJ, Hasegawa T, Akizawa T, Akiba T, et al. Vascular access use and outcomes: an international perspective from the Dialysis Outcomes and Practice Patterns Study. *Nephrol Dial Transplant*. 2008; 23: 3219-3126.
- K/DOQI Clinical Practice Guidelines and Clinical Practice Recommendations 2006 Updates Hemodialysis adequacy Peritoneal Dialysis Adequacy Vascular Access. *Am J Kidney Dis*. 2006; 48: 1.
- Beathard GA, Arnold P, Jackson J, Litchfield T. Physician operator's forum of RMS lifeline. Aggressive treatment of early fistula failure. *Kidney Int*. 2003; 64: 1487-1494.
- Jennings WC. Creating arteriovenous fistulas in 132 consecutive patients: exploiting the proximal radial artery arteriovenous fistula: reliable, safe, and simple forearm and upper arm hemodialysis access. *Arch Surg*. 2006; 141: 27-32.
- Pantea S, Bengulescu I. Smooth loop arterio-venous fistula. *Chirurgia (Bucur)*. 2014; 109: 678-681.
- Shibutani S, Obara H, Ono S, Kakefuda T, Kitagawa Y. Transposed brachio basilic arteriovenous fistula. *Ann Vasc Dis*. 2013; 6: 164-168.
- Sahasrabudhe P, Dighe T, Panse N, Patil S. Retrospective analysis of 271 arteriovenous fistulas as vascular access for hemodialysis. *Indian J Nephrol*. 2013; 23:191-195.
- Al Shohaib S, Al Sayyari A, Abdelkarin Waness A. Hemodialysis angioaccess choice and survival in a tertiary care Saudi Arabian center from 1993 to 2004. *Nephro-Urology Monthly*. 2011; 3: 69-73.

9. Derakhshanfar A, Gholyaf M, Niayesh A, Bahiraii S. Assessment of frequency of complications of arterio venous fistula in patients on dialysis: a two-year singlecenter study from Iran. Saudi J Kidney Dis Transpl. 2009; 20: 872-875.
10. Nakagawa Y, Ota K, Sato Y, Fuchinoue S, Teraoka S, Agishi T. Complications in blood access for hemodialysis. Artif Organs. 1994; 18: 283-288.