

Case Series

Retraction Scar Treatment with Fat Injection

Guerrissi JO, Siniger TB* and Di Lisio MG

Department of Plastic and Reconstructive Surgery, Dr. Cosme Argerich Hospital, Argentina

*Corresponding author: Siniger TB, Department of Plastic and Reconstructive Surgery Dr. Cosme Argerich Hospital, Buenos Aires University, Pi y margall 750, Buenos Aires, Argentina, Tel: 1565174994; Email: tatiana.belen.siniger@gmail.com

Received: June 09, 2015; Accepted: August 05, 2015;

Published: August 12, 2015

Keywords

Fat injection; Scar correction; Adipose cell; Burn; Minimally invasive surgery

Introduction

When the healing process begins the lesion can progress to contraction-retraction, which is considered the basic process where the edges are brought to the center by their tension lines, or it may contract generating a scar against cosmetics or functional objectives. The healing process is inherent to each individual, but there are various circumstances such as traumatic injuries, closures by second intention and burn scar that can contribute to the development of a scar retraction. In the case of a burn scar the tissue is subjected to a state of chronic hypoxia. Now a day's some of the possible treatments include: laser therapy [1] external silicone patches, injectable glucocorticoids [2], superficial radiotherapy, drug treatments such as interferon and colchicine (the still mostly under review), and a surgical treatment conventionally referred as z or w plasty, used to change the vertical axis of the scar and distribute better and without anarchy the basic tensions generated by the scar. The lipotransference [3] was developed in recent years. The method consists of taking fat removed by liposuction under low pressure and places it on the treated area. This is use in aesthetic lipofilling, for the treatment of chronic ulcers members and also as a relaxation treatment of scars or retracted areas postcicatrizales. This method has been published as effective in several health international centers [4]. The reason for this paper is to contribute to show the effectiveness of this process in 4 patients with retracted scars in Plastic Surgery Service Hospital Cosme Argerich, Buenos Aires, Argentina.

Table 1: Patients with scar retractions.

CAUSES	COMPROMISED AREAS	NUMBER OF PATIENTS
BURNS: TYPE B	HAND	6
	FINGERS	5
	NECK	4
	ARMPIT	3
TRAUMA	POPLITEAL	2
AFTERMATH OF SURGERY	ARMPIT	1
	NECK	1

Materials and Methods

This study is based on a prospective clinical evaluation in the period of 2010 to 2013 in 22 patients with scars retractions. The patients' ages ranged between sixty and ninety-four. The reason for consultation was mainly due the functional limitations in joint and tendon movements, associated with pain and itching, and changes in the aesthetic appearance characteristics, elasticity, texture and color (Table 1).

Eighteen of the 22 cases were treated with fat injection in the area with scar retraction that had as a result of burns type B with functional limitation in the regions where they were located: palm, finger and anterior cervical region in 3cases (13%) and popliteal in 1 case (4%).

All cases were followed under the recommendations of Coleman [5,6] for removal, preparation and transfer the fat to scar area. After an infiltration with a local abdominal anesthetic, the fat is extracted. Liposuction is performed manually avoiding aspiration systems to limit the effect of the negative pressure on adipocytes. The tissue obtained is centrifuged at 3000 rounds per minute for 3 min to separate the fat tissue from the oils, serum and red blood cells. The adipocyte cell is injected by sharp 3mm cannulas at the dermal-hypodermal junction in the scar areas.

A 3 mm cannula is used for autologous fat infiltration in the receiving area and it was performed doing a retrograde infiltration, radiated from a sub dermal plane to retro muscular.

Case 1

A 19 year old female patient, who suffered an electrical burn when she was 5 years old. She had a compromised ring finger on the left hand and she has had no treatment until the consultation.

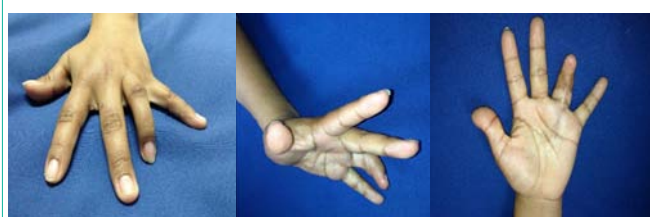


Figure 1: Preoperative view: Palmar face, back and profile respectively in maximum extension.

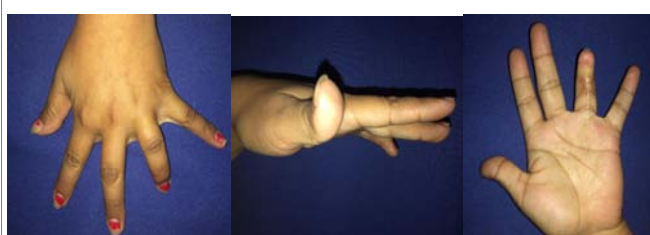


Figure 2: Postoperative view 3 months after the second treatment with fat injection.

Hypertrophic scar is in the palm side of the ring finger, retractable, hyper pigmented with limited extension, flexion and abduction (Figure 1).

The patient underwent two transfers of 20 and 15 cc of autologous fat respectively with an interval of six months between procedures. After 15 days of the first transfer an improvement was observed in finger movements and color uniformity of the scar (Figure 2).

Case 2

A 23-year-old male patient, who has burn his right-hand palm side at the age of 2. During the acute and sub acute phase underwent multiple procedures through skin to cover the bloody bed grafts.

He presents a limitation in maximum extension and flexion, inability to thumb opposition and abduction with spontaneous amputation of the distal phalanx of the index finger (Figure 3).

The patient was operated twice with six months apart. There were transferred 70 to 50 cc of autologous fat respectively.

Since the immediate postoperative period (1 month) it was found: full extension and flexion; thumb opposition recovered in 80% and good interphalangeal abduction. There was no significant improvement in the aesthetic conditions of the area (Figure 4).

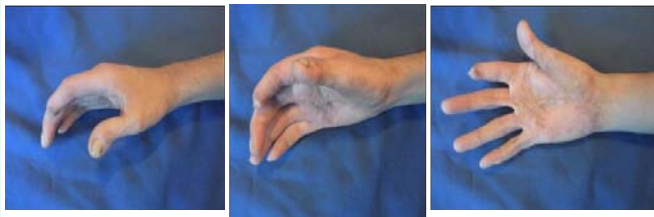

Figure 3: Preoperative view: Extension, palmar flexion and maximum respectively.

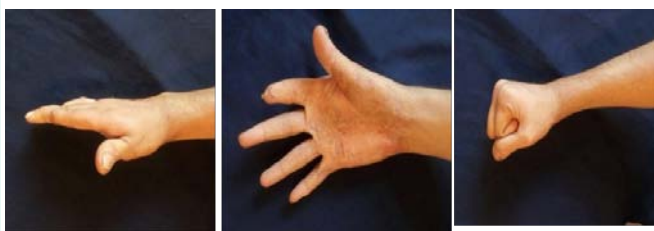

Figure 4: Postoperative view 1 year after the third treatment with fat injection.

Case 3

A 27-year-old female patient who suffered burns on 25% of the total body surface, including the anterior cervical region. Her reason for consultation corresponds to pain and cervical mobility limitation (Figure 5). The patient underwent a single intervention to transfer 40 cc of fat. The patient reported spontaneous elimination of pain after 20 days of the surgery (Figure 6). The spontaneous and associated with the movements and there was a clear improvement in neck extension (Figure 7).

Case 4

A 21-year-old female patient with circumferential burns on his right leg made at the age of 3 years. Search by persistent pain that

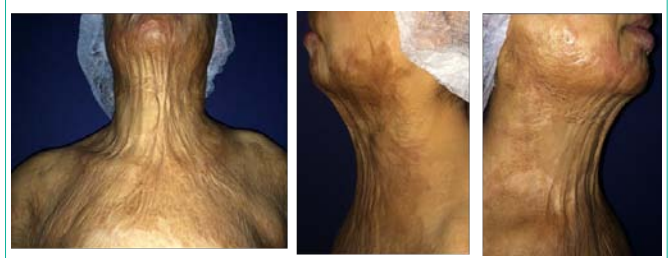


Figure 5: Preoperative view: front and both profiles at maximum extension. 1/3 retractable flanges cervical half.

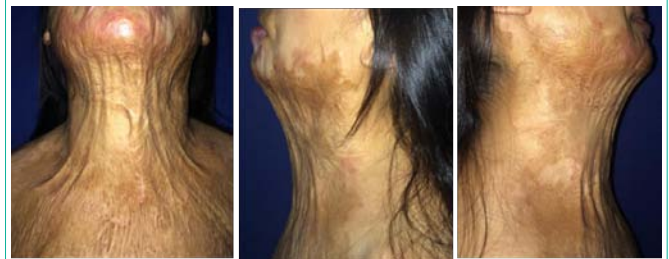


Figure 6: View of the patient 1 month after burn injuries.

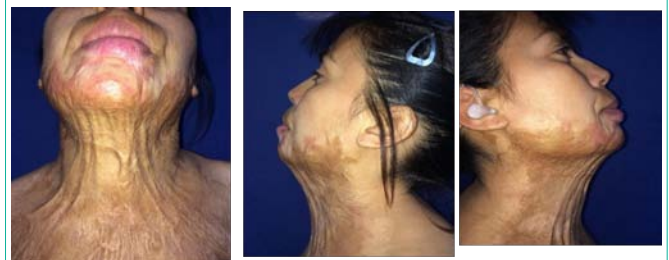

Figure 7: View of the patient 3 months after burn injuries.

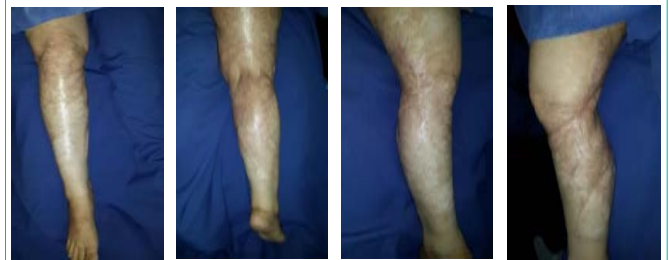

Figure 8: Preoperative view: anterior, posterior, external and internal.

increases with movement and limiting the extension and flexion of the leg (Figure 8).

She underwent an intervention in which they were transferred 80cc autologous fat. Within 30 days of postoperative it was found resting pain reduction and movements associated with greater extension and reduced lower limb edema (Figure 9).

Results

A functional improvement in skin elasticity and joint movements has been shown between 15 to 30 days after the first lipotransference in the monitored patients. The improvement was stabilized with the following infiltrations. The patients have been questioned about

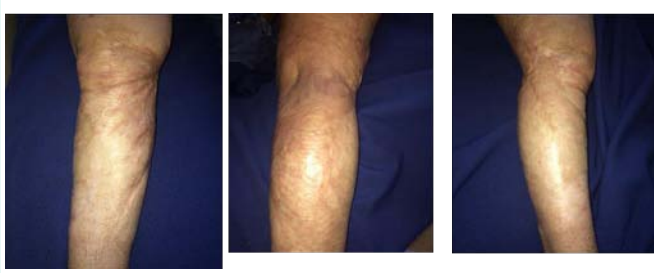


Figure 9: Postoperative view 3 months after the second treatment with fat injection.

clinical developments related to the aesthetic and functional post infiltration comparatively response with the same preoperative conditions. A functional improvement was proved by direct observation of the surgeons. Who have mainly asked the patients about elasticity of the skin and scar neighboring area, mobility and pain in the affected area? Both patients and surgeons agree that the texture of the skin was the most significant change they experimented in an aesthetic level.

Discussion

The exact mechanism, by which fat cells improve the appearance of scars and retractions caused by them, is not yet proven. The result of a chemical, physical and mechanical synergistic effect can be considered responsible for the benefits achieved.

Recognizing the adipocyte as a result of a mesenchymal cell [7] capable of endocrine secretion and release of various hormones and growth factors such as IGF1 (insulin-like growth factor), IL6 (mediator of the inflammatory response) TGF β (growth factor beta transforming regulator of biological processes of proliferation, differentiation and development), VEGF (vascular endothelial growth factor), we can infer that their presence does trigger an inflammatory response necessary for the formation of new extracellular matrix favoring the reorganization of dermal fibers, neoangiogenesis and epithelial hyperplasia, all own healing process by providing ad integrum beneficial qualities to the fabric in appearance, elasticity and laxity characteristics.

The procedure itself from the puncture as a method of infiltration into the receiving area generates an additional physical stimulated to trigger a local inflammatory response by enhancing the chemical action of autologous fat.

Not least the mechanical action exerted by the infiltrated volume that contribute to the breakdown of fiber tracts flanges and whose macroscopic translation it is the shrinkage. A limitation that shows the procedure corresponds to the evaluation of the results because the subjectivity of the benefits reported by patients and the absence of standardized scores for the evaluation of scar contractures in different locations.

Because of this drawback, the Vancouver Scar Scale (VSS) [8] is use for that assessment in similar works done in other health centers worldwide. Here it is consider flexibility, pigmentation, color and height by scores. Other authors have described a set of values called POSAS [9] where unlike the rest, is one of the only instruments of assessment that includes the eyes of patients based on

the subjective comparison of ratings given by the surgeon and the patient in reference to flexibility, color, pain, stiffness and irregularity; determining tissue oxygen saturation by spectrophotometry; measurement of hemoglobin; photographic and clinical record for comparison by experienced plastic surgeons and biopsy preoperative and postoperative in order to determine the persistence of fat tissue and vascularization that can be generated by the action of infiltrated tissue [10].

In the preoperative and postoperative histological studies in our patients could determine the persistence of fat cells, newly formed vessels and epithelial hyperplasia after infiltration of fat [11,12].

These results contribute to consider some of the ways that could explain, at least partially, how fat cells contribute to tissue changes that favor improving the clinical course of patients

The most significant results in the 4 patients were treated with this technique: from the functional point increasing skin elasticity and recovery of sub dermal soft tissue and improving joint movement and a drastic reduction of pain. Another finding was functional improvement was obtained after the first infiltration with fat; however the filling and decreased scar retraction were boosted with subsequent injections.

According to patients and surgeons, no significant improvement has been shown in the aesthetic appearance of scars and retracted areas.

Besides the aforementioned subjective benefits, increased subcutaneous fat tissue, release and increased laxity scar tissue and neoangiogenesis area could be beneficial for planning aesthetic and / or functional future surgeries.

Conclusion

While the scar is a definitive result is also the conclusion of the dynamic process of tissue repair and regeneration. Because this is regulated by cytokines, growth factors, chemicals and cellular elements, the influence on the various physiological activities influence the development of the wound.

It is at this point; through the staging of the molecular basis of healing and the scar itself that lipotransference is presented as an alternative treatment.

An improvement in the functionality of the areas involved, skin texture and increment in the elasticity of the tissues has been shown by the results.

The spontaneous and generated pain during movements decreased dramatically and has even disappeared. This made the patients very receptive to future infiltrations.

The possibility of using local Anesthesia, the ambulatory patient management, (Factors that managed to reduce the cost of the procedure), the rapid recovery and low complication rate makes the procedure presented as first-line alternative treatment.

References

1. Alster TS, Williams CM. Treatment of keloid sternotomy scars with 585 nm flashlamp-pumped pulsed-dye laser. *Lancet*. 1995; 345: 1198-1200.

2. Boyadjiev C, Popchristova E, Mazgalova J. Histomorphologic changes in keloids treated with Kenacort. *J Trauma*. 1995; 38: 299-302.
3. Illouz YG. Body contouring by lipolysis: a 5-year experience with over 3000 cases. *Plast Reconstr Surg*. 1983; 72: 591-597.
4. La Rusca I, Schonauer F, Molea G. Core fat graft transplantation for depressed scar. *Plast Reconstr Surg*. 2009; 123: 1394-1395.
5. Coleman SR. Facial recontouring with lipostructure. *Clin Plast Surg*. 1997; 24: 347-367.
6. Coleman SR. Long-term survival of fat transplants: controlled demonstrations. *Aesthetic Plast Surg*. 1995; 19: 421-425.
7. Tholpady SS, Llull R, Ogle RC, Rubin JP, Futrell JW, Katz AJ. Adipose tissue: Stem cells and beyond. *Clin Plast Surg*. 2006; 33: 55-62FC.
8. Pallua N, Pulsfort AK, Suschek C, Wolter TP. Content of the growth factors bFGF, IGF-1, VEGF, and PDGF-BB in freshly harvested lipoaspirate after centrifugation and incubation. *Plast Reconstr Surg*. 2009; 123: 826-833.
9. Stavrou D, Haik J, Weissman O, Goldan O, Tessone A, Winkler E. Patient and observer scar assessment scale: how good is it? *J Wound Care*. 2009; 18: 171-176.
10. Draaijers LJ, Tempelman FR, Botman YA, Tuinebreijer WE, Middelkoop E, Kreis RW, et al. The patient and observer scar assessment scale: a reliable and feasible tool for scar evaluation. *Plast Reconstr Surg*. 2004; 113: 1960-1965.
11. Klinger M, Marazzi M, Vigo D, Torre M. Fat injection for cases of severe burn outcomes: a new perspective of scar remodeling and reduction. *Aesthetic Plast Surg*. 2008; 32: 465-469.
12. Brzoska M, Geiger H, Gauer S, Baer P. Epithelial differentiation of human adipose tissue-derived adult stem cells. *Biochem Biophys Res Commun*. 2005; 330: 142-150.