

Special Article - Surgical Case Reports

Chylous Ascites and Chylothorax after Pancreaticoduodenectomy: Case Report and Literature Review

Ian Greenwalt*, Jana Hambley and John Ammori
University Hospitals Case Medical Center, USA

*Corresponding author: Ian Greenwalt, University Hospitals Case Medical Center, USA, Email: greenwalti@gmail.com

Received: April 21, 2015; Accepted: June 01, 2015;

Published: June 10, 2015

Abstract

Chyle leak is a lesser known complication of pancreaticoduodenectomy. The purpose of this case report is to describe the unusual complication of chyle leak associated with pancreaticoduodenectomy, discuss our team's management of this complication and review the literature describing postoperative chyle leaks.

Keywords: Chylous ascites; Chylothorax; Chyle leak

Introduction

Beginning with Codivilla and Kausch at the end of the 19th and early 20th century, the evolution of the pancreaticoduodenectomy has been marked by significant advances in operative technique as well as description and management of the mortality and morbidity associated with this procedure. Chyle leak is a lesser known complication of pancreaticoduodenectomy and is the focus of this report. The accumulation of chyle in the abdominal and/or thoracic cavities (chylous ascites and chylothorax) can be caused by a lymphatic leak following disruption of lymphatic channels or major lymphatic structures including the thoracic duct or cisterna chyli. If unaddressed, chyle leak can result in electrolyte abnormalities, malnutrition, immunodeficiency, sepsis and increased mortality. The purpose of this report is to describe a case of chyle leak associated with pancreaticoduodenectomy, discuss our team's management of this unusual complication, and review the literature regarding postoperative chyle leaks.

Case Presentation

71-year-old male with a past medical history of multiple myeloma, hypertension, gastro esophageal reflux disease, chronic obstructive pulmonary disease, and Child's alcoholic cirrhosis who presented with epigastria pain, anorexia, early satiety, fatigue, and a 60lb weight loss. CT abdomen and pelvis showed thickening of the second part of the duodenum with proximal dilatation of the duodenal bulb concerning for periampullary neoplastic process. Upper endoscopic ultrasound showed a thick ended and edematous duodenal bulb. Fine needle aspiration from the head of pancreas showed atypical cells.

Patient underwent an uncomplicated classic pancreaticoduodenectomy with gastrostomy tube and feeding jejunostomy tube placement because of his preoperative gastric outlet obstruction and significant gastric dilation.

The patient's hospital course was complicated by erythematous and fluid leakage from the midline incision on postoperative day 9. The midline incision was partially opened and a large amount of thin, milky fluid drained from the wound. CT scan demonstrated a peripancreatic fluid collection and a large right-sided pleural effusion fluid (Figure 1).

The patient underwent percutaneous drainage of the abdominal fluid collection and thoracentesis. Fluid triglyceride was 907 mg/dL confirming chyle leak with chylous ascites and chylothorax. A wound manager was placed over the opened midline incision to control continued drainage. Daily output from the abdominal drain and wound manager ranged from 1-3.8L. Therefore, the patient was allowed nothing per os, treated with octreotide 100mcg SQ every 8 hours, and administered total parenteral nutrition. Over the next 7 days, drain output tapered down and transitioned in character from chylous to clear ascitic fluid with a normal triglyceride level, likely related to the patient's underlying alcoholic cirrhosis. Eventually the output decreased to 325ml over 24 hours on postoperative day 17, at which point an oral diet was reintroduced. Ultimately, the drain was removed and the patient was discharged home on postoperative day 26 tolerating a regular diet.

Discussion

Chyle leak is a complication more often associated with esophagectomy, radical neck dissection, pneumonectomy or extensive

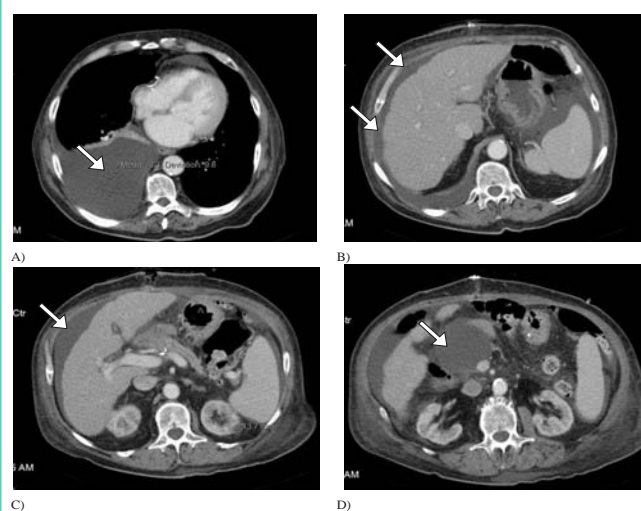


Figure 1: Post-operative CT Chest, Abdomen Pelvis. CT imaging A-D illustrating post-operative chyle leak. A) Representing right pleural effusion. B&C) Representing chylous ascites. D) Peripancreatic fluid collection.

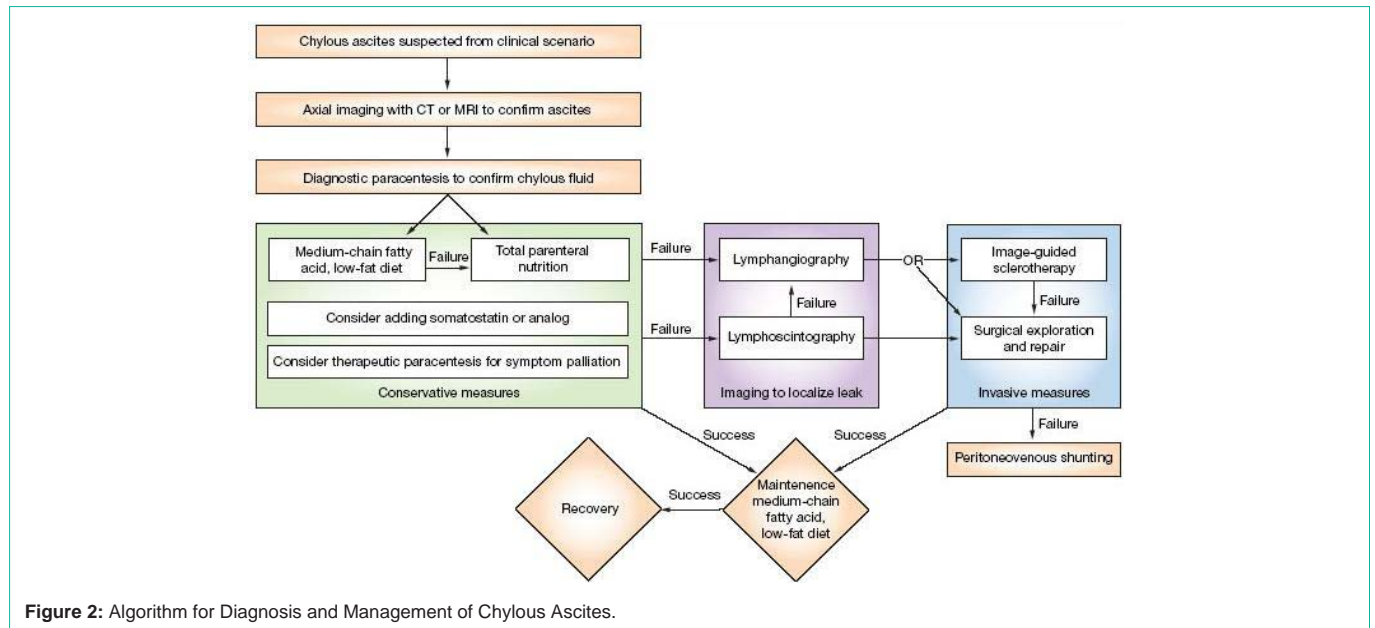


Figure 2: Algorithm for Diagnosis and Management of Chylous Ascites.

retroperitoneal lymphadenectomy [1]. Following pancreatic resection, chyle leak occurs with a frequency of approximately 1.3 % [2]. When chyle leaks develop, they are often associated with protracted clinical courses and poorer long term survival [3]. Reported risk factors for chyle leak following pancreatic resection include female gender, history of chronic pancreatitis, extensive lymphadenectomy as well as formation of portal or mesenteric thrombosis [4]. The most common presentation of chyle leak is abdominal distension after the patient has been introduced to a diet [5]. Chyle leaks often present on post-operative days 5-9 and are frequently incited by initiation of enteral feeding [6]. In addition to abdominal distention following introduction of enteral feeding, a classical feature of chylous ascites is milky discharge from the incision site. The diagnosis of chylous ascites or chylothorax is confirmed by a fluid triglyceride level of 110 mg/dL or greater. Sampling the fluid from a suspected leak is generally recognized as a more reliable means of diagnosis than imaging such as CT [7]. While CT is not strongly endorsed as a means of diagnosing chyle leak, lymphangiography can be used to effectively localize and characterize a leak [8]. In addition to its diagnostic qualities, there is evidence from small case studies that lymphoangiography can also be therapeutic; resulting in lymphatic leak closure following this procedure [9].

Ideally, management of a chyle leak should gradually increase in invasiveness; beginning with dietary restrictions, then radiological interventions and, lastly, surgical interventions for those patients refractory to more conservative management (Figure 2).

In large, retrospective case reviews, it has been found that 67% of chyle leaks can be successfully managed through a conservative approach based on dietary modification; whereas the remaining 33% require invasive radiological or surgical intervention [10]. The goals of nutritional management of chyle leaks are to decrease chyle production allowing damaged lymphatics to heal, replace fluids and electrolytes and maintain/replete the patient's nutritional status in order to prevent malnutrition [11]. Initially, conservative management involves dietary restrictions such as a high-protein,

low-fat, and Medium-Chain-Triglyceride (MCT) diet. MCTs are absorbed directly across the intestinal mucosa and into the portal circulation, thus bypassing lymphatics and decreasing lymphatic flow. If modified enteral feeding is unsuccessful in closure of a chyle leak, patients should then have nothing per os and be initiated on total parenteral nutrition for 2-6 weeks [12]. Though effective for the majority of patients, conservative management using dietary interventions can take weeks to months to resolve a chyle leak and require a patient to be continued on a low-fat, high protein, MCT diet post-operatively for several weeks [13]. When necessary, conservative nutritional management can be complemented by drainage of chylous collections followed by physiological and pharmacologic slowing of lymph production using somatostatin analogues [14]. When this conservative approach fails, more invasive strategies including serial paracentesis, embolization via interventional radiology, placement of a peritoneovenous shunt or reoperation can be employed [15,16]. In terms of operative intervention, laparoscopy can be used to drain ascites, localize a chyle leak and ligate, laser or shunt the affected lymphatics [17].

In conclusion, chyle leak is an unusual complication associated with pancreaticoduodenectomy of which all pancreatic surgeons should be aware. This case illustrates accurate diagnosis and successful management of this problem using modern approaches.

References

1. Seow C, Murray L, McKee RF. Surgical pathology is a predictor of outcome in post-operative lymph leakage. *Int J Surg.* 2010; 8: 636-638.
2. Assumpcao L, Cameron JL, Wolfgang CL, Edil B, Choti MA, Herman JM, et al. Incidence and Management of Chyle Leaks Following Pancreatic Resection: A High Volume Single-Center Institutional Experience. *J Gastrointest Surg.* 2008; 12: 1915-1923.
3. Ibid.
4. Abu Hilal M, Layfield DM, Di Fabio F, Arregui-Fresneda I, Panagiotopoulou IG, Armstrong TH, et al. Postoperative Chyle Leak after Major Pancreatic Resections in Patients who Receive Enteral Feed: Risk Factors and Management Options. *World Journal of Surgery.* 2013; 37: 2918-26

5. Verhaar AC, Haverkort EB, Busch OR, van Gulik TM, Gouma DJ, van der Gaag NA. Chylous Ascites after Pancreaticoduodenectomy: Introduction of a Grading System. *Journal of the American College of Surgeons*. 2008; 207: 751-757.
6. Malik HZ, Crozier J, Murray L, Carter R. Chyle leakage and early enteral feeding following pancreaticoduodenectomy: management options. *Dig Surg*. 2007; 24: 418-422.
7. Mittleider D, Dykes TA, Cicuto KP, Amberson SM, Leusner CR. Retrograde Cannulation of the Thoracic Duct and Embolization of the Cisterna Chyli in the Treatment of Chylous Ascites. *Journal of Vascular and Interventional Radiology*. 2008; 19: 285-290.
8. Burgin A, Bakalis C, Kolicaj N, Schwartz S. Review of Techniques for Percutaneous Lymphangiography and Thoracic Duct Cannulation for Treatment of Chylothorax. *Journal of Vascular and Interventional Radiology*. 2015; 26: S169-S169.
9. Matsumoto T, Yamagami T, Kato T, Hirota T, Yoshimatsu R, Masunami T, et al. The effectiveness of lymphangiography as a treatment method for various chyle leakages. *Br J Radiol*. 2009; 82: 286-290.
10. Aalami OO, Allen DB, Organ CH Jr. Chylous ascites: a collective review. *Surgery*. 2000; 128: 761-778.
11. Stacey M, Parrish RC. Nutritional Issues in Gastroenterology. *Practical Gastroenterology*. 2004; 17: 60-76.
12. Link RE, Amin N, Kavoussi LR. Chylous Ascites Following Retroperitoneal Lymphadenectomy for Testes Cancer. *Nature: Clinical Practice of Urology*. 2006; 3: 226-232.
13. Ibid.
14. Saziye K, Gino G, Afksendiyos K. Somatostatin Treatment of a Persistent Chyloperitoneum Following Abdominal Aortic Surgery. *Journal of Vascular Surgery*. 2012; 56: 1409-1412.
15. Chalret du Rieu M, Baulieux J, Rode A, Mabrut JY. Management of postoperative chylothorax. *J Visc Surg*. 2011; 148: e346-352.
16. Senaati A, Braun A. Role of the Interventional Radiologist in the Diagnosis and Management of Chylothorax: a review of Traditional and Novel Methods. *Journal of Vascular and Interventional Radiology*. 2015; 26: S226-S226.
17. Campisi C, Bellini C, Eretta C, Zilli A, da Rin E, Davini D, et al. Diagnosis and management of primary chylous ascites. *J Vasc Surg*. 2006; 43: 1244-1248.