

## Special Article - Surgical Case Reports

# Successful Resection of an Occluded Inferior Vena Cava Caused by Locally Advanced Renal Cell Carcinoma of the Right Kidney

Katharina Marsoner<sup>1,2\*</sup>, Peter Kornprat<sup>1</sup>, Richard Zigeuner<sup>3</sup>, Wolfgang Marte<sup>4</sup>, Drago Dacar<sup>2</sup> and Hans Jörg Mischinger<sup>1</sup>

<sup>1</sup>Department of General Surgery, Medical University of Graz, Austria

<sup>2</sup>Department of Cardiac Surgery, Medical University of Graz, Austria

<sup>3</sup>Department of Urology, Medical University of Graz, Austria

<sup>4</sup>Department of Anesthesiology, Medical University of Graz, Austria

\*Corresponding author: Katharina Marsoner, Department of General Surgery, Medical University of Graz, Auenbruggerplatz 29, 8036 Graz, Austria, Tel: 0043 316 12755; Fax: 0043 316 385 14672; Email: katharina.marsoner@medunigraz.at

Received: February 26, 2015; Accepted: June 02, 2015; Published: June 10, 2015

## Abstract

**Case Report:** Complete thrombotic occlusion of the IVC (Inferior Vena Cava) can be life-threatening in locally advanced Renal Cell Carcinoma (RCC).

We present a case of a young male patient, who first admitted with macrohematuria caused by a T4-RCC of the right kidney with complete thrombotic occlusion of the IVC. Primarily, the tumor was considered unresectable. After extensive multidisciplinary discussion, the patient was then scheduled for multi-visceral resection. Successful complete resection of the tumor could be performed; the IVC was resected without graft interposition. After an uneventful postoperative course, the patient could be discharged home in an excellent functional state.

**Conclusion:** Our case clearly demonstrates that in young patients with locally advanced RCC, multi-visceral resection can be performed successfully with after meticulous evaluation and risk-calculation.

**Keywords:** Locally advanced renal cell carcinoma; Thrombotic occlusion of the inferior vena cava; Multi-visceral resection

## Introduction

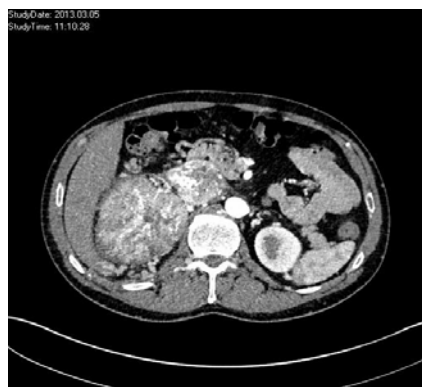Total thrombotic occlusion of the IVC by an invading RCC represents a potentially life-threatening event. Complete resection including resection of the IVC with or without vascular reconstruction is associated with a high preoperative risk; mainly caused by the danger of severe venous bleeding from collateral circulations and the extent of the surgical intervention itself [1]. We present a case of a 41-year old male patient with complete thrombotic occlusion of the IVC caused by a T-4 renal cell cancer of the right kidney, where complete resection of the tumor including the IVC could be accomplished successfully.

## Case Report

A 41-year old male patient primarily admitted with macrohematuria. Sonographic and radiologic evaluation revealed a giant T4-RCC of the right kidney with total thrombotic occlusion of the IVC at the level III (retro hepatic) according to the classification of Neves and Zincke [2], with a consecutive hindered flow in the right hepatic vein and a subsequent thrombotic occlusion of the pelvic and lower extremity veins (Figure 1). A portography showed a thrombotic formation in the right hepatic vein (Figure 2). Preoperative diagnostic imaging proved absence of metastasis formation.

Primarily, the patient was classified as unresectable; after extensive discussion in the multidisciplinary tumor board considering the young patient's age as well as his good functional state, and an excellent long-term survival in case of R0-tumor-resection, the patient was scheduled for multi-visceral resection. Surgery was performed by a surgical team consisting of urologists, visceral and cardiac surgeons.

Surgical approach was performed via right subcostal incision with chevron bilateral subcostal laparotomy and median sternotomy to provide adequate exposure. The resection included a radical right nephrectomy as well as a cholecystectomy, the lobus caudate had to be resected to facilitate liver mobilization and subsequent freeing of the retrohepatic IVC. The IVC was closed by means of a tourniquet at the niveau of the right atrium; the hepatic veins were cross clamped, and the IVC was primarily opened, the tumor thrombus reached the niveau of the hepatic veins. Subsequently, the IVC was resected distally at the niveau of the renal vein up to the confluent of the hepatic vein with the IVC with a vascular stapler (Figure 3), a big spermatic vein with drainage from the tumor was also resected. The tumor infiltrating the anterior surface of the psoas muscle was mobilized in a meticulous fashion; finally, a macroscopically complete resection



**Figure 1:** Preoperative computed tomography demonstrating the T4 RCC with thrombotic occlusion of the vena cava inferior.

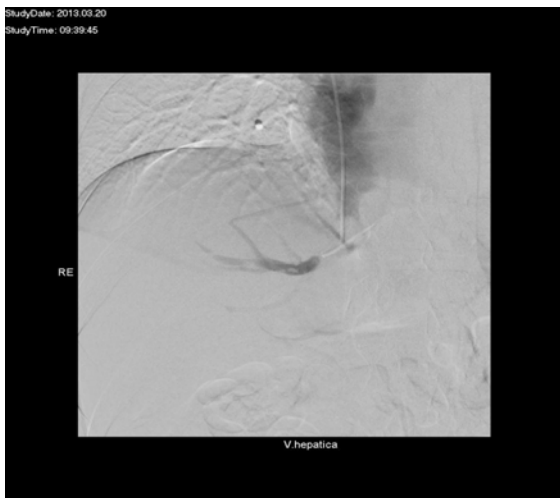


Figure 2: Portography showing thrombotic formation in the right hepatic vein.

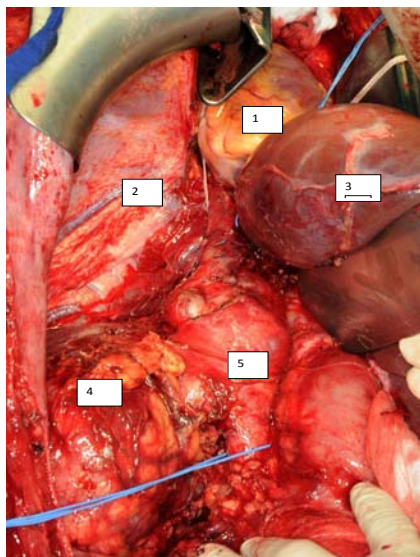


Figure 3: Intraoperative view.  
1: Right ventricle; 2: Right lung; 3: Right liver lobe; 4: Right kidney with T4-tumor; 5: Occluded inferior caval vein

could be performed. The rejected tumor is displayed in (Figure 4). After resection of the IVC, the surgical team observed intraoperative liver swelling caused by hepatic venous congestion; the problem could be successfully solved with connection of an extra-anatomic bypass by means of a gore-tex tube graft between the right hepatic vein and the right auricula to ensure sufficient hepatic venous drainage. After flushing and perfusion of the extra-anatomic graft, the liver swelling decreased immediately (Figure 5). The IVC itself was not reconnected or reconstructed via graft interposition because of sufficient venous collateralization beside from the right hepatic vein.

The whole procedure was performed under continuous Trans-Esophageal Echocardiography (TEE) surveillance by an extensively trained cardiac anesthesiologist (Figure 6). The installation of an Extracorporeal Circulation (ECC) was not necessary though ECC standby.

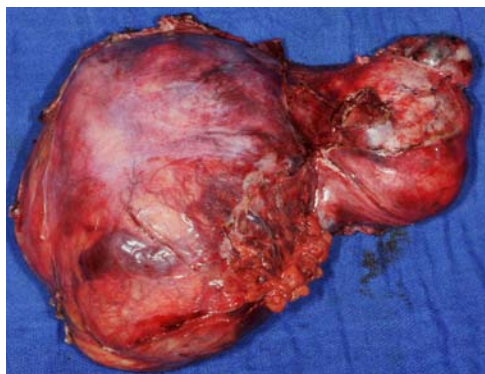


Figure 4: Resected tumor.

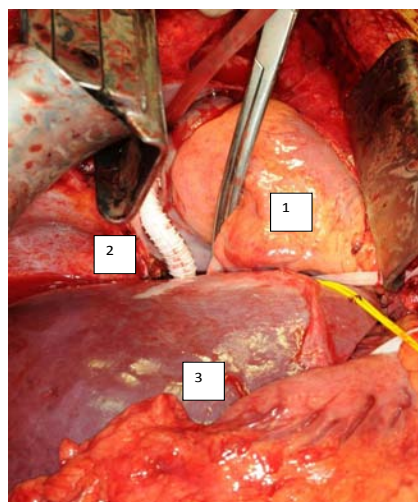


Figure 5: Extra-anatomic bypass by means of a vascular prosthesis between the right hepatic vein and the right auricula.  
1: Right ventricle; 2: Extra-anatomic gore bypass between right hepatic vein and right auricula; 3: Liver

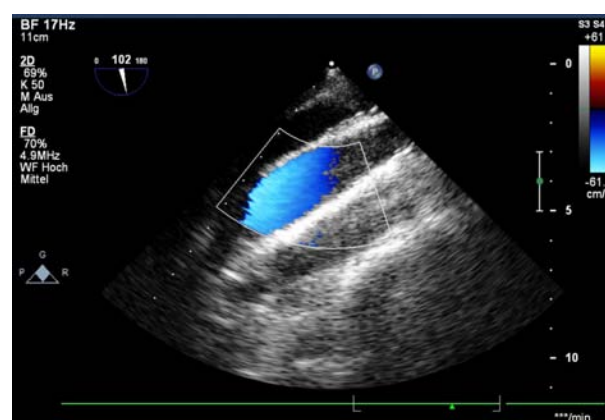


Figure 6: Transesophageal echocardiography before resection.

Intraoperative histopathological rapid section examining specimen of the rejected renal vein and artery, the right ureter, the right spermatic vein, the rejected part of the psoas muscle and the vena cava itself as well as the definitive histopathological examination of the whole tumor demonstrating the tumor invading the Gerota's

fascia but with free margins, UICC 2009 stage G2, pT4. The rejected gallbladder, lymph nodes as well as the liver specimen (lobus caudatus) were proven to be free of tumor.

The postoperative course was uneventful, the patient could be extubated two hours postoperatively, and was monitored on our intensive-care unit for three days. Postoperative renal function was excellent, with an unimpaired glomerular filtration rate. A postoperative transthoracic echocardiogram demonstrated normal biventricular function as well as absence of tricuspid regurgitation, other valvular pathologies and hemodynamically significant pericardial effusion. The patient could be discharged home on postoperative day twenty after full clinical recovery and normal exercise capacity. He received permanent war far in treatment for one year with an INR of 2.5 – 3.0 and is currently under closed multidisciplinary follow-up by all involved disciplines.

The induction of postoperative adjuvant chemotherapy was not necessary because of complete tumor resection with negative margins. At this point, the clinical as well as the radiological follow-up showed no evidence of disease; the patient can pursue his professional activity without any limitations.

### Comment

Complete surgical resection with negative margins at initial surgery clearly improves prognosis in patients with locally advanced renal cell cancer with tumorous thrombotic occlusion of the IVC, and is the only potentially curative approach in this tumor entity caused by limited response to chemotherapy regimen [2-4]. The tumor in our patient was primarily considered to be unrespectable by the multidisciplinary tumor board. As presented in our case, thrombotic occlusion of the IVC with subsequent occlusion of the pelvic and lower extremity veins represents a tumor-associated life-threatening event requiring fast decision making in therapy schedule. Total occlusion of the IVC can only be survived by patients with slow development of tumor thrombus, allowing the patient's circulation to adapt to the change in hemodynamics by formation of sufficient venous collateral circulation; nevertheless, this fact is associated with significant danger of severe venous bleeding during surgical intervention. IVC resection is well tolerated in those patients because of slow establishment of venous collaterals due to pre-existing caval obstruction [3].

If the IVC occlusion occurs at level IV, tumor resection and IVC resection often requires establishment of Extracorporeal Circulation (ECC); if ECC is not established primarily it is mandatory to perform the whole procedure under ECC-standby and presence of a cardiac surgical team, as performed in the presented case [5].

Surgical resection of locally advanced renal cell cancer involving anatomic structures in the neighborhood as IVC, right atrium, liver, psoas muscle, etc can be performed with fairly low preoperative mortality and acceptable tumor-free survival justifying this invasive high-risk procedure in well selected patients [2,4,5]. Nevertheless, only small, heterogenic case series with limited patient numbers were published of this rare disease pattern [6-7]. Meticulous preoperative evaluation and surgical stratification is mandatory in these patients primarily often considered as unrespectable,

As we performed in our patient, the conduction of the whole procedure under permanent TEE surveillance allows intra-operative

real-time monitoring which provides accurate information regarding the presence and the extent of IVC involvement, cardiac filling volumes as well as guidance for vascular clamping and confirmation of complete removal of the tumor thrombus [8].

The connection of an extra-anatomic bypass between the right hepatic vein and the right auricula was performed because of intra-operatively diagnosed liver swelling caused by hepatic venous congestion to ensure sufficient hepatic venous drainage; this intervention does not represent an established surgical technique rather than an intraoperative bailout strategy. The reconstruction of the IVC continuity by means of graft interposition was not necessary because of sufficient collateral venous drainage because of adapted hemodynamic, only the liver venous congestion had to be corrected immediately.

The most frequent complication during the early postoperative period are renal failure depending upon dialysis and venous congestion of the lower extremity veins; but these complications are mostly temporary and can be treated successfully [4,5,7]. Fortunately, our patient exhibited none of these either other adverse event during the postoperative period.

### Conclusion

Our case clearly demonstrates that in selected young patients with locally advanced renal cell cancer, complete tumor resection including extended multi-visceral resection can be performed successfully, but requires closed multidisciplinary treatment during follow-up. The high preoperative risk must be explained clearly to the patient during preoperative consent, and intraoperative bailout strategies should be always kept in mind.

### References

1. Lawindy SM, Kurian T, Kim T, Mangar D, Armstrong PA, Alsina AE, et al. Important surgical considerations in the management of renal cell carcinoma (RCC) with inferior vena cava (IVC) tumour thrombus. *BJU Int.* 2012; 110: 926-939.
2. Haferkamp A, Bastian PJ, Jakobi H, Pritsch M, Pfitzenmaier J, Albers P, et al. Renal cell carcinoma with tumor thrombus extension into the vena cava: prospective long-term followup. *J Urol.* 2007; 177: 1703-1708.
3. Duty B, Daneshmand S. Resection of the inferior vena cava without reconstruction for urologic malignancies. *Urology.* 2009; 74: 1257-1262.
4. Vergho DC, Loeser A, Kocot A, Spahn M, Riedmiller H. Tumor thrombus of inferior vena cava in patients with renal cell carcinoma - clinical and oncological outcome of 50 patients after surgery. *BMC Res Notes.* 2012; 5: 5.
5. Casey RG, Raheem OA, Elmusharaf E, Madhavan P, Tolan M, Lynch TH. Renal cell carcinoma with IVC and atrial thrombus: a single centre's 10 year surgical experience. *Surgeon.* 2013; 11: 295-299.
6. Spiess PE, Kurian T, Lin HY, Rawal B, Kim T, Sexton WJ, et al. Preoperative metastatic status, level of thrombus and body mass index predicts overall survival in patients undergoing nephrectomy and inferior vena cava thrombectomy. *BJU Int.* 2012; 110: 470-474.
7. Ayyathurai R, Garcia-Roig M, Gorin MA, González J, Manoharan M, Kava BR, et al. Bland thrombus association with tumour thrombus in renal cell carcinoma: analysis of surgical significance and role of inferior vena caval interruption. *BJU Int.* 2012; 110: E449-455.
8. Oikawa T, Shimazui T, Johraku A, Kihara S, Tsukamoto S, Miyayama N, et al. Intraoperative transesophageal echocardiography for inferior vena caval tumor thrombus in renal cell carcinoma. *Int J Urol.* 2004; 11: 189-192.