

## Special Article - Surgical Case Reports

# Ischaemic Colitis Immediately Following Reversal of Leostomy: An Unusual Case

Cadoux-Hudson D\*, Chand M and Miles AJG  
Royal Hampshire County Hospital, UK

\*Corresponding author: Daniel Cadoux-Hudson,  
Royal Hampshire County Hospital, Winchester UK &  
Royal Marsden Hospital, UK, Email: cadoux@me.com

Received: December 26, 2014; Accepted: May 21,  
2015; Published: June 10, 2015

## Abstract

A 71-year-old gentleman presented to our care for a reversal of a defunctioning loop ileostomy following an anterior resection for a rectal carcinoma 10 months previously. Post-operatively he developed ileus with worsening pain. Ischaemic colitis was confirmed on flexible sigmoidoscopy. He was discharged 7 days later. There are no reported cases of ischaemic colitis following reversal of ileostomy in the literature, though there are reports of cases occurring after primary resection.

Ischaemic colitis is a rare complication of reversal of defunctioning ileostomy. There is no obvious cause in this case with no significant risk factors for de novo development of disease, or any evidence of compromised perfusion at either procedure. This may have been precipitated by vascular compromise at the initial operation that developed into sub clinical ischaemia whilst the metabolic demands on the colon were minimal. Only once the bowel's continuity was restored did this become apparent.

**Keywords:** Ischaemic colitis; Reversal of ileostomy; Anterior resection

## Case Presentation

A 71-year-old man was admitted for an elective reversal of loop ileostomy. He had previously had a laparoscopic anterior resection with a stapled colorectal anastomosis 10 months earlier for a rectal carcinoma and was left with a defunctioning loop ileostomy. He had subsequently had a three-month course of chemotherapy as 3 lymph nodes were found to be positive in the specimen from the original procedure. He was also found to have a small anastomotic leak during his original admission on Computed Tomography (CT) imaging. This was managed conservatively as he was clinically stable and improved.

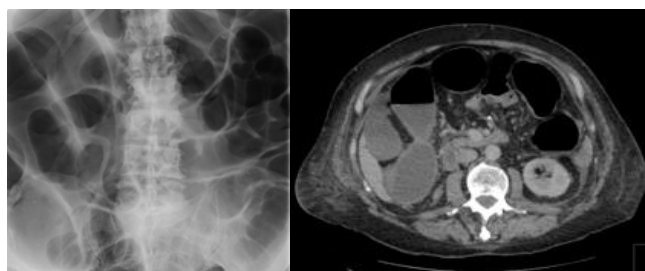
At closure of ileostomy it was noted that he had a large parastomal hernia containing 15-20 cm of small bowel necessitating a resection of 8 cm of small bowel with a hand sown end-to-end anastomosis. He had no other significant medical problems other than requiring a Trans Urethral Resection of Prostate (TURP) in the period between his colorectal procedures secondary to benign prostatic hypertrophy.

Post operatively he developed abdominal pain and ileus that was managed with analgesia and insertion of a large bore nasogastric tube.

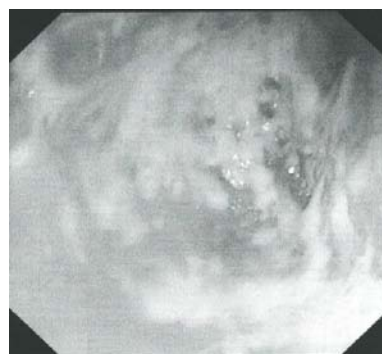
This however did not resolve, and he was started on total parenteral nutrition. An abdominal film showed dilated small and large bowel, though CT did not reveal a transition point. A flexible sigmoidoscopy was ordered for the following day in order to rule out an anastomotic stricture. At endoscopy an area of ulceration consistent with ischaemia was seen in his colon 50cm from the anal verge. There was no evidence of recurrence or an anastomotic stricture. He remained in hospital for a further 7 days with symptoms of ongoing cramping abdominal pain and increased frequency of bowel habit. He has since been seen in follow up and continues to have a more frequent bowel habit, though the pain is significantly improved (Figures 1 & 2).

## Discussion

There are no documented cases of bowel ischaemia presenting after restoring bowel continuity in the literature at present. There are several reports of ischaemia presenting in the immediate post operative period on average presenting 5 days post operatively [1]. The cause of the bowel ischaemia in this case is debatable. There



**Figure 1:** Abdominal film showing dilated large and small bowel and CT showing normal left side colon.



**Figure 2:** Endoscopic image showing ischaemic colitis.

is the possibility that at the original operation a colonic artery was inadvertently obstructed causing ischaemia—if that were the case you would expect there to have been a major post operative complication such as rectal necrosis as reported by Hudler et al. [2] or ischaemic structuring [3]. Furthermore at the time of the operation there was a good blood supply to the cut end of the colon and there was no suspicion of unintended arterial damage. In the intervening period between his original operation and reversal he did not report any symptoms of pain suggesting that there was no ischaemia during that period, though there may well have been a relative ischaemia, but as the colon was not in continuity there were no symptoms, this only became apparent when the metabolic demand increased post operatively. In addition he has no risk factors (known cardiovascular disease, female sex and advanced age) for a de novo ischaemic colitis [4], that said some form of ischaemic event within the inferior mesenteric artery (thrombotic or embolic) cannot be excluded though we have no clinical or radiological evidence for this.

Another possibility is that the reversal procedure led to ischaemia through some mechanism. This is unlikely given the site of reversal was proximal to the site of ischaemia and the blood supply to them are anatomically separate, the superior mesenteric artery proximally and the inferior mesenteric artery distally, though not impossible. There have been no reported cases of this phenomenon in any patients who have had their ileostomy reversed. Neither is there any evidence that chemotherapeutic agents can cause ischaemic colitis in the literature.

This case describes an unusual presentation of ischaemic colitis immediately after a procedure of the small bowel. The most likely cause being either secondary to an incidental episode of ischaemia that only became symptomatic when the metabolic requirement of the colon increased, or there was a degree of ischemia initiated at the time of the original procedure which only became apparent later. Though this is a rare occurrence it is worth considering in cases of unexplained symptoms after restoration of the continuity of the bowel.

## References

1. Park MG, Hur H, Min BS, Lee KY, Kim NK. Colonic ischemia following surgery for sigmoid colon and rectal cancer: a study of 10 cases and a review of the literature. *Int J Colorectal Dis.* 2012; 27: 671-675.
2. Hubler M, Isbister WH. Rectal necrosis following anterior resection of the rectum. *Aust NZJ Surg.* 1995; 65: 614-616.
3. Yamazaki T, Shirai Y, Sakai Y, Hatakeyama K. Ischemic stricture of the rectosigmoid colon caused by division of the superior rectal artery below Sudeck's point during sigmoidectomy: report of a case. *Surg Today.* 1997; 27: 254-256.
4. Sherid M, Sifuentes H, Samo S, Sulaiman S, Husein H, Tupper R, et al. Ischemic colitis: A forgotten entity. Results of a retrospective study in 118 patients. *J Dig Dis.* 2014; 15: 606-613.