

Clinical Image

Intraneural Muroid Cysts of Sciatic and Common Fibular Nerve: A Case Report

Zaizi A^{1*}, Andour H², Achehbar O² and Boussouga M¹

¹Department of Orthopaedic Surgery & Traumatology II, Mohamed V Military Hospital, Faculty of Medicine and Pharmacy, Mohamed V University, Morocco

²Department of Radiology, Mohamed V Military Hospital, Faculty of Medicine and Pharmacy, Mohamed V University, Morocco

*Corresponding author: Abderrahim Zaizi, Doctor at Department of Orthopaedic Surgery & Traumatology II, Mohamed V Military Hospital, Faculty of Medicine and Pharmacy, Mohamed V University, Rabat 10100, Morocco

Received: October 08, 2022; Accepted: November 02, 2022; Published: November 09, 2022

Clinical Image

Intraneural muroid cyst is uncommon and benign condition, it can result in nerve compression at late stages. However, it is a reversible mono-neuropathy disease if diagnosed early and surgically treated [1]. There are numerous hypotheses of pathogenesis such as recurrent trauma, intra-neural hemorrhage, muroid degeneration and the more recent unified articular theory suggesting that intraneural cysts originate from adjacent joint and dissect along the articular branch into the principal nerve [2].

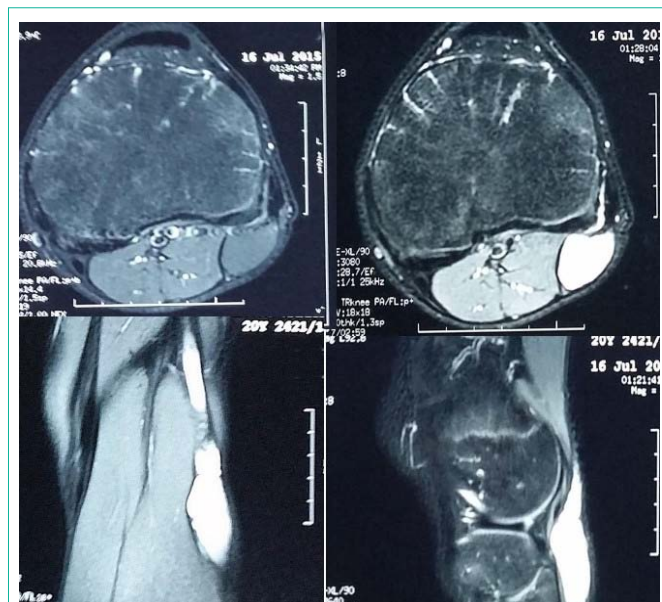


Figure 1: MRI showing a longitudinally oriented cystic lesion in the sciatic and common fibular nerve with extension towards the tibio-fibular joint.

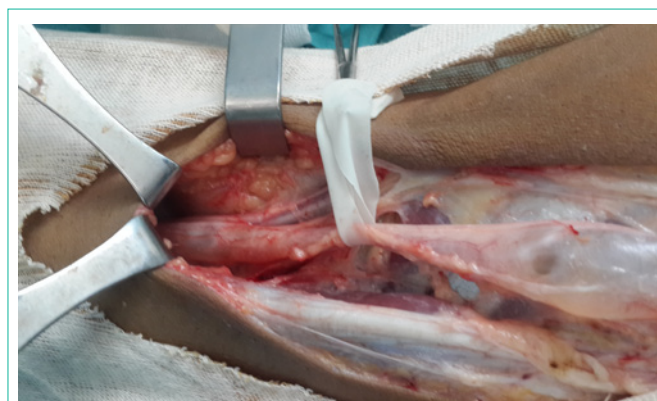

Figure 2: Intraoperative image showing mucinous cyst within the sciatic and common fibular nerve.

We report the case of a 20-year-old man who suffered during a long time from pain and paresthesia in the territory of the common fibular nerve. MRI revealed a presence of a cystic formation, finely septate along the course of the sciatic nerve lower third and common fibular nerve with extension towards the tibio-fibular joint. This formation extends for about 18 cm and is 20 cm thick without enhancement after injection of the contrast and any bone signal abnormality. The cyst was surgically excised through a posterior approach it was within the epineurium and compress adjacent nerve fascicles, we performed ligation of the neck of the cyst preventing further recurrence. The complete nerve decompression results in progressive functional recovery after 6-month follow-up.

Conflict of Interest

The authors declare that they have no competing interests.

References

1. Van den Veyver, Simon Lecouvet, Frédéric Barbier, Olivier. Kyste mucoïde intraneural du nerf fibulaire commun: À propos d'un cas et revue de la littérature. *Louvain medical*. 2013; 132: 88-92.
2. Panwar J, Mathew A, Thomas BP. Cystic lesions of peripheral nerves: Are we missing the diagnosis of the intraneural ganglion cyst?. *World J Radiol*. 2017; 9: 230-244.