

Special Article - Somatic Nuclear Transfer

A Case of Complete Resealing of Patent Foramen Ovale in a Cloned Red Angus Calf

Cofré S¹, Muñoz M², Velásquez AE², Torres A², Cabezas J², Cox JF², Castro FO² and Rodríguez-Alvarez LL^{2*}

¹Department of Clinical Sciences, Faculty of Veterinary Sciences, Universidad de Concepción, Avenida Vicente Méndez 595, Chile

²Department of Animal Science, Faculty of Veterinary Sciences, Universidad de Concepción, Avenida Vicente Méndez 595, Chile

*Corresponding author: Rodríguez-Alvarez LL, Department of Animal Science, Faculty of Veterinary Sciences, Universidad de Concepción, Avenida Vicente Méndez 595, Chillán 3780000, Chile

Received: May 02, 2017; Accepted: May 29, 2017;

Published: June 05, 2017

Abstract

Case Description: A 56kg (123,2lbs) one-day-old newborn purebred red Angus calf was evaluated because of a cardiac condition.

Clinical Findings: Radiography and ultrasonography revealed a loss of continuity of 18mm in the mid intra auricular area, in the region of the oval trench and it was diagnosed as patent foramen ovale. The right auricle was notably distended, with marked volume overload. There were eco dense structures floating inside the left auricle. Treatment and Outcome: Pharmacological treatment aimed to avoid overload of liquid flow in both the lung and the heart. Drugs administered were: furosemide (1mg/Kg every 12h), enalapril (0,5mg/kg every 12h) and sildenafil (0,5mg/kg every 12h). The goal of using sildenafil was to reduce the preload of the right ventricle and to diminish the risk of right cardiac failure and thus of acute respiratory crisis.

Clinical Relevance: Patent foramen ovale is common in newborn cloned calves and probably is under diagnosed in otherwise healthy looking newborn calves. The results of this paper show that foramen ovale can be pharmacologically treated in calves and that euthanasia of newborn animals carrying such pathology must be the last option, only when pharmacological approaches proved non-effective.

Keywords: Foramen ovale; Bovine clones; Respiratory frequency

Case Presentation

A female cloned calf weighting 56kg (123.2lbs) was produced. A possible heart failure of the cloned fetus was anticipated at day 265 by trans abdominal ultrasonography, detected as low fetal activity, low cardiac frequency and weak contraction movement of the heart during the ultrasound and examination of the recipient cow. However it was difficult to visualize the heart structures due to the big size of the fetus. Parturition was induced by the intramuscular administration of 25mg of dexamethasone phosphate, 36h before the programmed time for the cesarean. Caesarian section was performed at day 278, with the animal lying in right lateral decubitus position, under local anesthesia. Cloned calf was received after dissection of the umbilical cord and immediately checked for physiological constants (cardiac and respiratory frequencies and temperature (CF, RF, T°)). Nasal and pharyngeal secretions were removed by suction, and cold water was applied to the neck and the animal was vigorously rubbed to stimulate breathing. Oxygen therapy was provided by means of 8 liters of humidified oxygen/min. Forty mg of respiratory stimulants [a] was intravenously administrated, together with 2ml of 2.5% cefalosporin [b], 1ml of 1% clorfenamina maleato [c] and 1ml of 10mg/ml ketoprofen [d]. Once stabilized and within the first 30 minutes of life, 1000ml of freshly rehydrated hyper immune colostrum [e] was offered, and the dose repeated three times more up to the completion of 4liters during the first four hours of life. After the first inspection, there were found enlarged umbilical structures. Hematologic parameters were altered the first 24hours, and then became normal during the first week except for total protein that remained low (44g/L)

at the expense of low levels of immunoglobulins. Glucose was low at birth 0,8mmol/L, but normalized after administration of colostrum (2.6mmol/L 1h after birth) and remained normal thereafter (range between 3.9 and 4.1 mmol/L). Body temperature at birth was normal: 38.8°C (101.84F), however it declined to 37.5°C (99.5F) within the first hour after birth. Temperature reached the normal range 12hours after birth and after that, non-significant changes were observed on this parameter.

At birth, thoracic wall movements were superficial and the calf was considered to be in respiratory distress with persistent taquipnea (respiratory rate 120 breaths per minute and cardiac rate 110 beats per minute), and a compensatory tachycardia. This led to mechanical ventilation with intranasal oxygen, which was well tolerated, by the patient, and responded with decreased respiratory frequency (44 breaths per minute) and deepness of breathing. However twelve hours after birth, the respiratory frequency increased again over 100 breaths per minute, and remained so during the next 48hours. Auscultation yielded a holo-systolic ejection murmur heard loudest over the left heart base and with pulmonary creep due to a relative pulmonic stenosis caused by volume overload through the right side of the heart. At the electrocardiograph evaluation, deep S waves were found for DI, DII and DIII, indicating changes associated with right atrial overload. Thorax X-ray showed cardiomegaly with right predominance and a vascular arterial pattern (not shown).

In order to gain insight into the chamber structure of the heart, an echocardiogram was performed 72hours after birth, through the right Parasternal window using 3.5MHz sector probed [f]. The

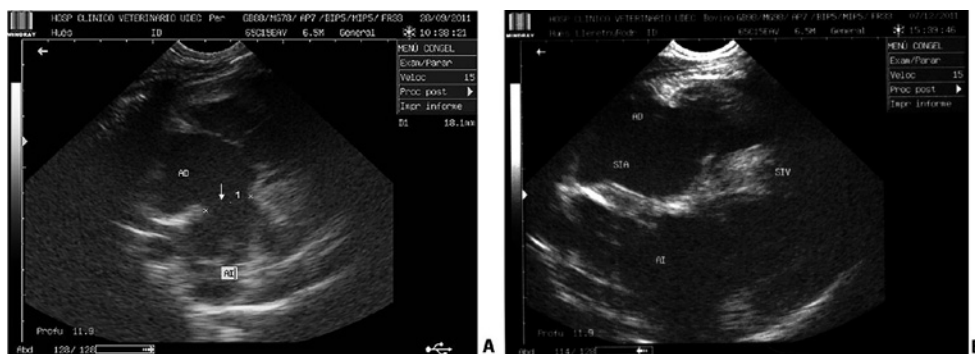


Figure 1: Bi-dimensional echocardiography of the four chambers from cloned calf. Right parasternal view. A: First echocardiography performed at third day of live. The lack of continuity in the interatrial septum in the oval trench is indicated by white arrow. B: Last echocardiography (approximately 3 months of age) showing a complete closing of the septum. AD= right atrium; AI= left atrium.

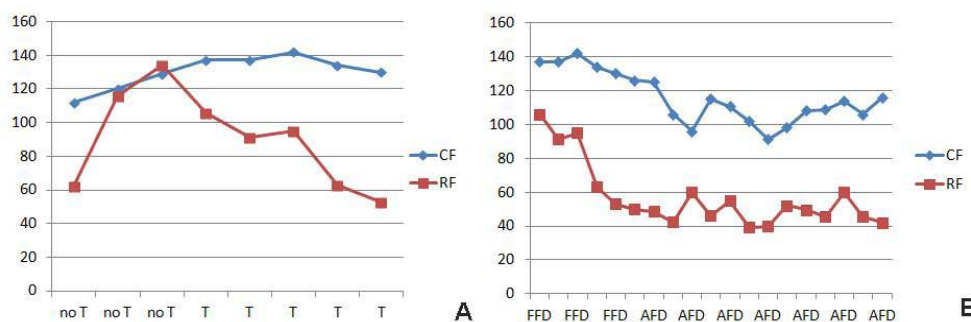


Figure 2: Respiratory and cardiac frequencies in cloned calf with patent foramen ovale. A: Respiratory and cardiac frequencies during the first week of live; no T: days without treatment; T: days with treatment. B: Respiratory and cardiac frequencies during the period of treatment until the diagnostic of a significant reduction of the foramen; FFD: first five days of treatment; AFD: after five days of treatment. Statistical analysis of the respiratory and cardiac frequencies was done by non-parametric Wilcoxon test using Info Stat program (Buenos Aires Argentina).

results confirmed an augmentation of the right ventricle, due to volume overload and a normal left ventricle. At the global view, it was found a conserved architecture of the mitral apparatus, with good aspect of the veils of the mitral valve. The tricuspid apparatus was well conserved, with appropriate definition of valve structures. The atrium section displayed a loss of continuity of 18mm in the mid intra atricular area, in the region of the oval trench and it was diagnosed as patent foramen ovale. The right auricle was notably distended, with marked volume overload. There were eco dense structures floating inside the left auricle.

In the long axis view of the four chambers, the outflow charts of both the left and right ventricle appeared normal, with a diameter of the aortic bulb of 24.5mm. As a resume, the patient showed an interauricular communication (foramen ovale) of 18mm, an enlargement of the right atrium and was classified as having type II cardiomyopathy. These kinds of patients normally develop severe congestive and hypertensive pulmonary symptoms and surgical approach is the most indicated procedure in these cases, but this is a rather invasive and risky treatment that implies high costs as well. For that reason we decided to follow a pharmacological treatment aimed to avoid overload of liquid flow in both the lung and the heart.

An inductive approach was undertaken in order to evaluate patient's response to the drugs. Firstly furosemide (1mg/Kg every 12h) was administered. The patient improved the frequency and depth

of the respiratory pattern, and tolerated it very well. After, enalapril (0.5mg/kg every 12h) was given to the calf and lastly sildenafil (0.5mg/kg every 12h) was added to the treatment. The goal of using sildenafil was to reduce the preload of the right ventricle and to diminish the risk of right cardiac failure and thus of acute respiratory crisis (Figure 1A,1B).

During the first five days after treatment there was a significant increase of the CF ($p=0.0357$) while there was a trend of the RF to decrease (Figure 2A). After five days of treatment there was a significant reduction of both the respiratory and the cardiac frequencies ($p=0.001$ and $p=0.0002$ respectively) (Figure 2B) and both frequencies remained constant and within the range for a bovine calf. Also an acceptable improvement of the clinical condition and of the well being of the patient was observed coincident with a gradual reduction of the foramen ovale diameter (15mm at day five). After one month of treatment the foramen was completely closed and medication was withdrawn stepwise to avoid decompensating of the patient.

Discussion

Atrial septal defect and persistence of an open foramen ovale are relatively common congenital defects of calves [1,2]. These defects provide direct openings between the left and right atrium. A patent foramen ovale is commonly partially covered by a membrane. Normally the opening is closed after birth; however in some patients

the foramen does not close at all or it closes during a long time window. If the foramen ovale does not close in a timely appropriate fashion, the cardio-respiratory pathologies associated to it, can lead to death of the newborn calf in the first days or weeks of life. This condition is often observed in cloned animals, especially if they show overweight at birth, also known as large offspring syndrome, a common anomaly in cloned calves [3-7]. Although its precise causes are not clear, it is responsible of several complications of cloned newborn calves, this includes among others, respiratory and cardiac distress and higher neonatal mortality in the clones [8-10]. Considering that usually bovine clones are born with a cardiac and respiratory distress we used a pharmacological treatment to induce a spontaneous closure of the foramen by decreasing the pulmonary hypertension and the cardiovascular overloading. Alternative surgical procedures to those described here imply either implantation of a catheter or prosthesis in the discontinuous atrial zone. These are rather invasive and risky treatments that imply high costs as well; normally such patients are euthanized, instead in this work we hypothesized that it is possible to treat the foramen ovale in newborn cloned calves using a non-invasive protocol.

Most of the patent foramen ovale in humans closes within three months after birth. The rate of closing is inversely proportional to the wide of the opening [11]. In this way openings between 3-5mm close in 87% of the cases, between 5-8 mm in 80% and bigger than 8mm do not close at all. We are not aware of similar measurements in cattle. In this case foramen closed within a month. The patient is at the moment of writing of this manuscript more than one year old, completely healthy and without any signs of cardiac miss function. Another cloned calf produced from the same cell line did not show this kind of pathology, thus it is not likely to be a cell-dependent event, but rather an epigenetic effect of nuclear transfer. Here we report a case of foramen ovale sealing in type II cardiopat Red Angus female cloned cattle. The results of this paper show that foramen ovale can be treated in cloned calves and that euthanasia of newborn animals carrying such pathology must be the last option, only when pharmacological approaches proved non effective.

Footnotes

- a. doxapram hydrochloride; Cobilux, Montevideo, Uruguay
- b. Cobactan® 2.5%; Intervet, Boxmeer, The Netherlands
- c. Histamil 1%; Troy Laboratories, Sydney, Australia

- d. Ket-10® 10 mg/ml; Drag Pharma, Santiago de Chile, Chile
- e. Calf's Choice Total™ Silver Colostrum; The Saskatoon Colostrum Company Ltd. Saskatoon, Canada
- f. MINDRAY DP-6600 Vet Transducer 5-8.5 MHz; National Ultrasound, Duluth, Georgia, United States Supported in part by INNOVA BIO BIO Grant No. 08 PCS5-352F10.

References

1. Buczinski G, Fecteau G, Comeau G, Boysen SR, Lefebvre RC, Smith LC. Ultrasonographic fetal well-being assessment, neonatal and postpartum findings of cloned pregnancies in cattle: a preliminary study on 10 fetuses and calves. *Can Vet J.* 2009; 50: 261-269.
2. Buczinski S, Fecteau G, Lefebvre RC, Smith LC. Fetal well-being assessment in bovine near-term gestations: Current knowledge and future perspectives arising from comparative medicine. *Can Vet J.* 2007; 48: 178-183.
3. Chavatte-Palmer P, Heyman Y, Renard JP. Clonage et pathologie de la gestation associées. *Gynecol Obstet Fertil.* 2000; 28: 633-642.
4. Williamson M, Tecirlioglu R, French A, et al. Anatomical abnormalities in calves produced by nuclear transfer. *Reprod Fertil Dev.* 2005; 17: 187.
5. Wilson JM, Williams JD, Bondioli KR, Looney CR, Westhusin ME, McCalla DF. Comparison of birth weight and growth characteristics of bovine calves produced by nuclear transfer (cloning) embryo transfer and natural mating. *Anim Reprod Sci.* 1995; 38: 73-83.
6. Garry FB, Adams R, McCann JP, Odde KG. Postnatal characteristics of calves produced by nuclear transfer cloning. *Theriogenology.* 1996; 45: 141-152.
7. Heyman Y, Chavatte-Palmer P, LeBourhis D, Camous S, Vignon X, Renard JP. Frequency and occurrence of late gestation losses from cattle cloned embryos. *Biol Reprod.* 2002; 66: 6-13.
8. Hill JR, Burghardt RC, Jones K, Long CR, Looney CR, Shin T. Evidence for placental abnormality as the major cause of mortality in first-trimester somatic cell cloned bovine fetuses. *Biol Reprod.* 2000; 63: 1787-1794.
9. Hill JR, Roussel AJ, Cibelli JB, Edwards JF, Hooper NL, Miller MW. Clinical and pathologic features of cloned transgenic calves and fetuses (13 cases studies). *Theriogenology.* 1999; 51: 1451-1465.
10. Li S, Li Y, Du W, Zhang L, Yu S, Dai Y, et al. Aberrant gene expression in organs of bovine clones that die within two days after birth. *Biol Reprod.* 2005; 72: 258-265.
11. Radzik D, Davignon A, van Doesburg N, Fournier A, Marchand T, Ducharme G. Predictive factors for spontaneous closure of atrial septal defects diagnosed in the first 3 months of life. *J Am Coll Cardiol.* 1993; 22: 851-853.