

Case Report

Clinical and Radiological Complete Response with Gemcitabine in a Locally Advanced Angiosarcoma

Vincenzi B^{1*}, Tonini G², Dei tos AP³, Luppi G⁴ and Marrucci E⁵

¹Department of Oncology, University Campus Bio-Medico Rome, Italy

²Director of Department of Oncology, University Campus Bio-Medico Rome, Italy

³Director of Department of Pathology, General Hospital of Treviso, Treviso, Italy

⁴Department of Radiology, University Campus Bio-Medico Rome, Italy.

⁵Department of Oncology, University Campus Bio-Medico Rome, Italy

*Corresponding author: Vincenzi Bruno, Medical Oncology, Department of Oncology, University Campus Bio-Medico, Rome, Italy

Received: May 14, 2017; Accepted: June 13, 2017;

Published: June 20, 2017

Abbreviations

AS: Angiosarcomas; STS: Soft Tissue Sarcoma; PFS: Progression-Free Survival; OS: Overall Survival

Introduction

Angiosarcomas (AS) are rare vascular malignancies, accounting for 1-2% of all soft tissue sarcomas. Tumors can occur in any location of the body (two-thirds are cutaneous, mainly in head and neck area, one-fourth arise in soft tissue) [1].

Angiosarcomas show large spectrum of clinical (skin and scalp angiosarcoma, angiosarcoma arising in irradiated fields, liver angiosarcoma associated with some occupational exposures, Stewart-Treves syndrome, etc) and histological (epithelioid forms, low-grade angiosarcoma mimicking benign vascular lesions) forms [2].

For curative intent of localized forms, large resection is the cornerstone treatment [2,3], but when achieving negative margin is difficult, AS can be treated by multimodality approach including radiotherapy [4].

There is no consistent data supporting adjuvant chemotherapy, despite the up to 50% of AS will develop distant metastasis [1]. The prognosis of advanced angiosarcoma remains dismal [2]. In a large review [5] it has been showed that cytotoxic chemotherapy was associated with a clinical benefit (objective response plus stable disease > 6 months) in approximately 60% of patients, proving the relatively high chemosensitivity of this sarcoma subtype.

Doxorubicin-based chemotherapy is the first-line standard treatment of metastatic or unresectable AS. It derived from analogy with other histological subtypes of STS and retrospective studies [6]. Doxorubicin-based chemotherapy provides a progression-free survival of 3.7–5.4 months and response rate between 40% and 65% [3].

Abstract

Angiosarcoma (AS) is a rare malignant mesenchymal tumor arising from endothelial cells of body vessels. This article reports a case of a locally advanced angiosarcoma of the face in a 64-year-old female diagnosed in April 2015 that showed complete clinical and radiological response after weekly gemcitabine therapy. At 23 months from the beginning of the treatment the patients is still free of relapse. This case suggests that gemcitabine is a well tolerate ad useful drug in locally advanced angiosarcoma.

Keywords: Locally advanced Angiosarcoma; Gemcitabine

Given the effectiveness of taxanes in patients affected by vascular-derived tumors, such as Kaposi sarcoma they were tested also in Angiosarcoma [6-9]. The phase II trial Angiotax study [10] assessed the efficacy of weekly paclitaxel in advanced or metastatic AS. This study showed a best objective response rate of 18%, a median Progression-Free Survival (PFS) and a median Overall Survival (OS) time of 3.8 and 8.3 months, respectively. Retrospective series have suggested a higher sensitivity to paclitaxel for cutaneous AS [3,8].

Given the crucial role of proangiogenic growth factors and their receptors in angiosarcoma several antiangiogenic agents has been tested in AS. In a single-arm phase II trial [11], bevacizumab seemed to show some kind of activity but the following phase II trial by Ray-Coquard [12] and colleagues didn't prove a great difference in adding bevacizumab to paclitaxel with 6-month PFS rates of 54% in paclitaxel arm (arm A) and 57% in paclitaxel-bevacizumab arm (arm B). The median overall survival rates were 19.5 months in arm A and 15.9 months in arm B.

The multi kinase inhibitor sorafenib demonstrated limited activity in a phase II trial and only in pretreated patients, with a 23% response rate and a median PFS of 2.0 months [13].

More recent data have supported the role and efficacy of gemcitabine in advanced disease. Stacchiotti et al. [14] conducted a retrospective series of 25 patients with locally advanced or metastatic angiosarcoma that underwent to treatment with gemcitabine as a single agent. They observed 68% RECIST responses and a median PFS of 7 months, with some long-lasting responses (one patient still responsive after 40 months).

Here, we report a case of a patient affected by locally advanced angiosarcoma that was admitted in our institution in April 2015. Considered the evidence of effectiveness of gemcitabine as a single agent and a more favourable toxicity profile respect to the

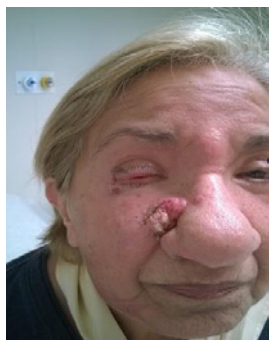

Figure 1: C.G. Clinical presentation at the time of the diagnosis.

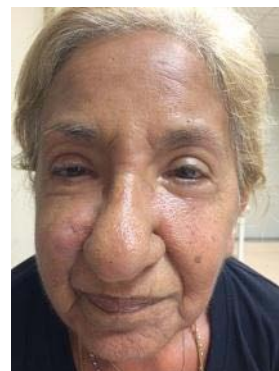

Figure 3: C.G. Clinical presentation after three cycles of weekly gemcitabine.

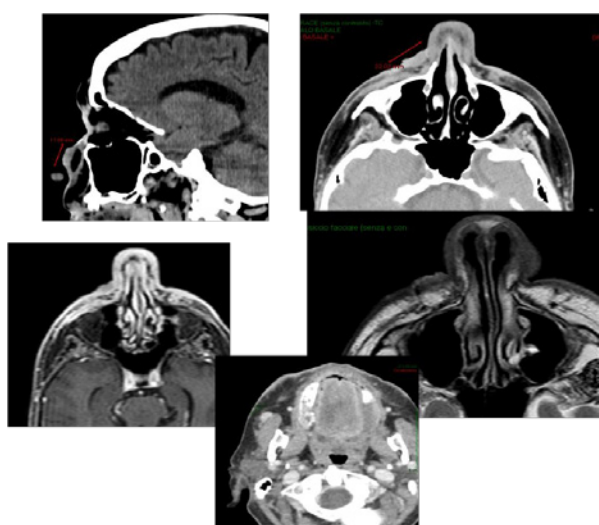


Figure 2: TC and RMN on April 2015. There is a thickening of the skin plans of the right naso-labial fold of about 23mm with shoots of infiltration in the subcutaneous adipose tissue, in the ala of the nose muscle with involvement of the angular artery of the nose, with no signs of erosion of bone surfaces. It is also showed a diffuse thickening of the dermis of the zygomatic-orbital area adjacent to the lesion, partially infiltrative.

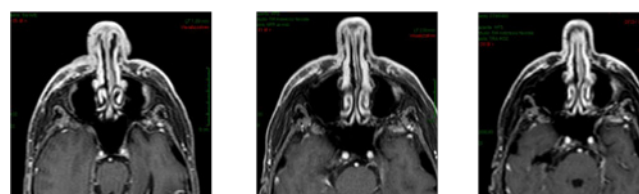


Figure 4: The comparison between RMN axial T1 fat sat acquisitions after contrast enhancement in June, July and October 2015 showed complete response.

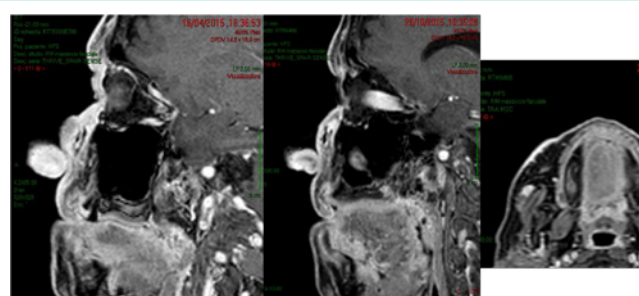


Figure 5: The comparison between RMN sagittal T1 fat sat acquisitions after contrast enhancement in April and October 2015 showed complete response.

combination with taxanes [15] or the cardiotoxicity of anthracyclines [16] we decided to treat our patient with single agent gemcitabine.

Case Presentation

C.G. was a retired teacher, 65-year-old female, smoker of 7-8 cigarettes per day from adolescence that reported the appearance, from February 2014, of a painless bulge at the level of the right cheek. On February 2015 it appeared an indolent exophytic lesion at the right naso labial fold, gradually enlarged. Furthermore the patient reported a gradual swelling of the ipsilateral eyelid with progressive impairment of ipsilateral view. She was admitted to the Department of Oncology of the Campus Biomedico of Rome in April 2015. At the time of the visit the patient presented an exophytic, soft and red lesion with irregular borders at the level of right nasolabial fold. She also presented right ptosis (Figure 1).

A percutaneous biopsy of the lesion demonstrated infiltration of epithelioid angiosarcoma. A review by dedicated STS pathologist confirmed the diagnosis. The neoplastic proliferation was characterized by nests of atypical, round to spindle-shaped epithelioid

cells showed positive immunostaining for CD31, CD34 and ERG.

TC total body and head and neck RMN with contrast enhancement were performed on 14.4.2015 and on 16.4.2015. The radiological exams showed a thickening of the skin plans of the right naso-labial fold of about 23mm with shoots of infiltration in the subcutaneous adipose tissue, in the ala of the nose muscle with involvement of the angular artery of the nose, with no signs of erosion of bone surfaces. TC and RMN also showed a diffuse thickening of the dermis of the zygomatic-orbital area adjacent to the lesion, partially infiltrative. It was also a lymph node of approximately 9mm superficially to the masseter muscle at the anterior pole of the parotid. Distant metastases were excluded (Figure 2).

Considered the extent of local invasion and the biological aggressiveness of the disease, patient was brought to systemic chemotherapy with weekly gemcitabine 1000mg/m² on 24.4.2015.

After three cycles C.G. showed a notable clinical response (Figure 3).

TC total body scan and head and neck RMN on July 2015 demonstrated an almost complete regression of the tumor. Patient continued weekly gemcitabine for other three months. Re-evaluation on October 2015 confirmed complete response. The comparison between the axial T1 fat sat acquisitions after contrast enhancement (04/06/15 - 16/07/15 - 29/10/15) showed lesion complete response with restoring the symmetry of the soft tissues of the zygomatic-nasal region (Figure 4).

The comparison between the sagittal T1 fat sat acquisitions after contrast enhancement (16/04/15 -29/10/15) showed response of the lesion with restoration of symmetry of the soft tissues of the zygomatic-nasal region. Unmodified the superficial lymph node on the right masseter (Figure 5).

For this reason patient keep on the same cytotoxic treatment for other three months. At January, 2016 patient was still in clinical response with regression of all symptoms; a new TC scan and RMN confirmed radiological stability, so treatment was continued.

Radiologic re-evaluation on April, July and November 2016 confirmed stable disease. Treatment was well tolerated without reduction of dose or delays in the administration of cycles for 20 months, until December 2016, when drug was reduced for thrombocytopenia and fatigue.

On March 2017 radiologic re-evaluation confirmed complete response of disease but for persistent thrombocytopenia and fatigue gemcitabine was discontinued and patient was brought to follow-up.

Discussion

The prognosis of angiosarcoma patients remains very poor. Fifteen percent of patients present with metastasis at the time of diagnosis. The 5-year overall survival rate for nonmetastatic cases is only 30%–40% because of the high incidence of metastatic spread [13]. The median OS duration at the metastatic stage is about 8 months [13]. Data derived from retrospective analyses or case reports suggest that among soft tissue sarcomas, angiosarcoma seems to be more sensitive to cytotoxic chemotherapy [17].

The rational basis for the use of gemcitabine in angiosarcomas derived from evidence of selective activity of this nucleoside analogue in some sarcoma subgroups both as a single agent [18,19], in association with docetaxel [15,20,21] or vinorelbine [22].

Stacchiotti et al. observed an interesting response rate in patients with progressing advanced angiosarcoma treated with gemcitabine [14] and if it is true that Maki et al in a randomized phase II clinical study suggested the superiority of the combination of gemcitabine + docetaxel versus gemcitabine alone [15], a pooled analysis of this study [23] would indicate that gemcitabine in monotherapy is not inferior to gemcitabine-docetaxel in leiomyosarcoma.

Furthermore it should be considered that gemcitabine as single agent is more tolerated respect the combination with docetaxel, given the significant incidence of thrombocytopenia and fatigue in the two-drug regimen [15].

Angiosarcoma is a rare disease and practical considerations derived from non-randomized phase II trials, non-comparative randomized phase II trials or retrospective cohort studies.

For the next future it will be desirable to assess the activity of this drug by well-designed phase III trials and it will be diderable to indentify which patients may benefit of gemcitabine treatment. In fact recent evidence seems to indicate a predictive role for HENT1 expression. Human equilibrative nucleoside transporter 1 is the major gemcitabine transporter into cells. An Italian retrospective study [24] determined the expression levels of hENT1 in samples derived from leiomyosarcoma and angiosarcoma patients. AS patients that exhibited high hENT1 expression showed a longer TTP (9.3 vs. 4.5 months;) and an improvement in OS (20.6 vs. 10.8 months).

Of note C.G. tissue sample was included for this study; it revealed high expression of HENT1.

Conclusion

The importance of this case report is to attest the effectiveness of gemcitabine in non operable, advanced angiosarcoma. This case also suggests that that gemcitabine is a manageable drug that can lead to notable and durable response.

Consent for Publication

Oral informed consent was obtained from the patient for publication of this Case Report and any accompanying images.

References

1. Nicolas Penel. Angiosarcoma: State of the art and perspectives. *Oncology Hematology*. 2011; 80: 257-263.
2. Fayette J, Martin E, Piperno-Neumann S, Le Cesne A, Robert C, Bonvalot S, et al. Angiosarcomas, a heterogeneous group of sarcomas with specific behavior depending on primary site: A retrospective study of 161 cases. *Ann Oncol*. 2007; 18: 2030-2036.
3. Fury MG, Antonescu CR, Van Zee KJ, Brennan MF, Maki RG. A 14-year retrospective review of angiosarcoma: clinical characteristics, prognostic factors, and treatment outcomes with surgery and chemotherapy. *Cancer J*. 2005; 11: 241-247.
4. Pawlik TM, Paulino AF, McGinn CJ, Baker LH, Cohen DS, Morris JS, et al. Cutaneous angiosarcoma of the scalp: a multidisciplinary approach. *Cancer*. 2003; 98: 1716-1726.
5. Italiano A, Cioffi A, Penel N, Levra MG, Delcambre C, Kalbacher E, et al. Comparison of doxorubicin and weekly paclitaxel efficacy in metastatic angiosarcomas. *Cancer*. 2012; 118: 3330-3336.
6. Penel N, Italiano A, Ray-Coquard I, Chaigneau L, Delcambre C, Robin YM, et al. Metastatic angiosarcomas: doxorubicin-based regimens, weekly paclitaxel and metastasectomy significantly improve the outcome. *Ann Oncol*. 2012; 23: 517-523.
7. Fata F, O'Reilly E, Ilson D, Pfister D, Leffel D, Kelsen DP, et al. Paclitaxel in the treatment of patients with angiosarcoma of the scalp or face. *Cancer*. 1999; 86: 2034-2037.
8. Skubitz KM, Haddad PA. Paclitaxel and pegylated-liposomal doxorubicin are both active in angiosarcoma. *Cancer*. 2005; 104: 361-366.
9. Schlemmer M, Reichardt P, Verweij J, Hartmann JT, Judson I, Thyss A, et al. Paclitaxel in patients with advanced angiosarcomas of soft tissue: a retrospective study of the EORTC soft tissue and bone sarcoma group. *Eur J Cancer*. 2008; 44: 2433-2436.
10. Penel N, Bui BN, Bay JO, Cupissol D, Ray-Coquard I, Piperno-Neumann S, et al. Phase II trial of weekly paclitaxel for unresectable angiosarcoma: The ANGIOTAX study. *J Clin Oncol*. 2008; 26: 5269-5274.
11. Agulnik M, Yarber JL, Okuno SH, von Mehren M, Jovanovic BD, Brockstein BE, et al. An open-label, multicenter, phase II study of bevacizumab for the treatment of angiosarcoma and epithelioid hemangioendotheliomas. *Ann Oncol*. 2013; 24: 257-263.

12. Ray-Coquard, Domont J, Tresch-Bruneel E, Bompas E, Cassier PA, Mir O, et al. Paclitaxel Given Once Per Week With or Without Bevacizumab in Patients With Advanced Angiosarcoma: A Randomized Phase II Trial. *J Clin Oncol*. 2015; 33: 2797-2802.
13. Isabelle Ray-Coquard, Italiano A, Bompas E, Le Cesne A, Robin YM, Chevreau C, et al. Sorafenib for Patients with Advanced Angiosarcoma: A Phase II Trial from the French Sarcoma Group (GSF/GETO). *Oncologist*. 2012; 17: 260-266.
14. Stacchiotti S, Palassini E, Sanfilippo R, Vincenzi B, Arena MG, Bochicchio AM, et al. Gemcitabine in advanced angiosarcoma: a retrospective case series analysis from the Italian Rare Cancer Network. *Ann Oncol*. 2012; 23: 501-508.
15. Maki RG, Wathen JK, Patel SR, Priebat DA, Okuno SH, Samuels B, et al. for SARC, the Sarcoma Alliance for Research through Collaboration. Randomized phase II study of gemcitabine and docetaxel versus gemcitabine alone in patients with metastatic soft-tissue sarcomas: results of sarcoma alliance for research through collaboration study 002. *J Clin Oncol* 2007; 25: 2755-2763.
16. Valcovici. Cardiotoxicity of anthracycline therapy: current perspectives. *Arch Med Sci*. 2016; 12: 428-435.
17. Young RJ, Brown NJ, Reed MW, Hughes D, Woll PJ, et al. Angiosarcoma. *Lancet*. 2010; 11: 983-991.
18. Patel SR, Gandhi V, Jenkins J, Papadopolous N, Burgess MA, Plager C, et al. Phase II clinical investigation of gemcitabine in advanced soft tissue sarcomas and window evaluation of dose rate on gemcitabine triphosphate accumulation. *J Clin Oncol*. 2001; 19: 3483-3489.
19. Okuno, Edmonson J, Mahoney M, Buckner JC, Frytak S, Galanis E. Phase II trial of gemcitabine in patients with advanced sarcomas. *Cancer*. 2003.
20. Leu KM. Laboratory and clinical evidence of synergistic cytotoxicity of sequential treatment with gemcitabine followed by docetaxel in the treatment of sarcoma. *J Clin Oncol*. 2004.
21. Bay JO, Ray-Coquard I, Fayette J, Leyvraz S, Cherix S, Piperno-Neumann S, et al. Docetaxel and gemcitabine combination in 133 advanced soft-tissue sarcomas: a retrospective analysis. *Int J Cancer*. 2006; 119: 706-711.
22. Dileo P, Morgan JA, Zahrieh D, Desai J, Salesi JM, Harmon DC, et al. Gemcitabine and vinorelbine combination chemotherapy for patients with advanced soft tissue sarcomas. *Cancer*. 2007; 109: 1863-1869.
23. Duffaud F, P Pautier, B Bui, ML Hensley, A Rey, N Penel, et al. A pooled analysis of the final results of the two randomized phase II studies comparing gemcitabine vs. gemcitabine + docetaxel in patients with metastatic/relapsed leiomyosarcoma. *Ann Oncol*. 2010.
24. Vincenzi. Human equilibrative nucleoside transporter 1 as a predictor of efficacy to gemcitabine in angiosarcoma and leiomyosarcoma. *Journal of Clinical Oncology*, 2016 ASCO Annual Meeting (June 3-7, 2016) ASCO Annual Meeting Poster. 2016.