

Review Article

Management of Toxicities with Pazopanib in Advanced Soft Tissue Sarcoma

Sankhala KK*, Chawla NS, Syed I and Chawla SP
Sarcoma Oncology Center and Cancer Center of California, USA

*Corresponding author: K Kumar Sankhala, Sarcoma Oncology Center and Cancer Center of California, USA

Received: March 17, 2016; Accepted: August 11, 2016;

Published: August 16, 2016

Abstract

Advanced Soft Tissue Sarcoma (aSTS) is a rare, heterogeneous disease with poor prognosis. Management is challenging, and treatment options are limited. Chemotherapy (single agents or combination regimens) is the standard of care for first-line treatment but is associated with low response rates and numerous safety concerns. Pazopanib, a small-molecule receptor tyrosine kinase inhibitor that targets vascular endothelial growth factor and platelet-derived growth factor receptors, is approved for the treatment of aSTS after prior chemotherapy (based on results from the double-blind, randomized phase 3 PALETTE study). Pazopanib is an effective and potentially safer alternative for second-line treatment after chemotherapy in most aSTS types; exceptions include adipocytic STS and gastrointestinal stromal tumors, for which it is not indicated. This agent is generally tolerated (severity of most adverse events is grade 1 to 2) and seems to have a favorable toxicity profile with respect to myelosuppression relative to the commonly prescribed chemotherapies. However, use of pazopanib is associated with important safety risks, of which health care providers should be aware, including diarrhea, hepatic toxicity, hypertension/cardiac toxicity, hemorrhagic and thromboembolic events, gastrointestinal perforation, neurological disorders, acute pancreatitis, pneumothorax, and metabolic disturbances. Patients receiving pazopanib should be proactively educated about the risks and be taught to recognize and report signs and symptoms in a timely manner. Most pazopanib-associated adverse events can be safely managed with dose modification. Diligent monitoring for and proactive management of adverse events is critical with use of pazopanib. This article reviews key safety concerns associated with pazopanib and provides management recommendations.

Keywords: Adverse event; Patient management; Pazopanib; Soft tissue sarcoma; Toxicity

Abbreviations

ACE: Angiotensin-Converting Enzyme; AE: Adverse Event; ALT: Alanine Transaminase; AST: Aspartate Transaminase; aSTS: advanced Soft Tissue Sarcoma; CI: Confidence Interval; HR: Hazard Ratio; LVEF: Left-Ventricular Ejection Fraction; OS: Overall Survival; PALETTE: Pazopanib Explored in Soft-Tissue Sarcoma—A Phase 3 Study; PDGFR: Platelet-Derived Growth Factor Receptor; PFS: Progression-Free Survival; RCC: Renal Cell Carcinoma; RPLS: Reversible Posterior Leukoencephalopathy Syndrome; RR: Relative Risk; T4: Thyroxine; TKI: Tyrosine Kinase Inhibitor; TMA: Thrombotic Microangiopathy; TSH: Thyroid-Stimulating Hormone; ULN: Upper Limit Of Normal; FDA: US Food And Drug Administration; VEGFR: Vascular Endothelial Growth Factor Receptor; VTE: Venous Thromboembolic Event

Introduction

Advanced soft tissue sarcoma (aSTS) is a rare, markedly heterogeneous disease that is challenging to manage and that associated with poor prognosis [1-3]. STS is primarily treated with chemotherapy regimens; standard first-line treatment for patients with unresectable aSTS is single-agent chemotherapy (eg, doxorubicin, ifosfamide, epirubicin, gemcitabine, dacarbazine) or

anthracycline-based combination therapy (doxorubicin or epirubicin with ifosfamide and/or dacarbazine) [4-6]. However, overall response rates in the first-line setting are low (~25%) [7-9], and response rates decrease with each subsequent line of therapy [6]. In addition, serious toxicity (eg, myelosuppression, cardiotoxicity) is often a limiting factor, especially with combination regimens [5,10] and some histologic subtypes (eg, alveolar soft-part sarcoma, extraskeletal myxoid chondrosarcoma, solitary fibrous tumors) are generally insensitive to chemotherapy [2].

Pazopanib, a small-molecule receptor tyrosine kinase inhibitor (TKI) that targets vascular endothelial growth factor receptor (VEGFR) and platelet-derived growth factor (PDGFR) receptors (thereby inhibiting angiogenesis), is approved for the management of advanced renal cell carcinoma and aSTS after prior chemotherapy [11]. US Food and Drug Administration (FDA) and European Medicines Agency approval of pazopanib in aSTS in 2012 (for subtypes other than adipocytic STS and gastrointestinal stromal tumors [United States] and for subtypes included in the phase 3 trial [Europe]) was based on results from the PALETTE study (Pazopanib Explored in Soft-Tissue Sarcoma—A Phase 3 Study) [12,13]. This study was a multicenter, randomized, double-blind, placebo-controlled, phase 3 trial in patients with aSTS whose disease

Table 1: Frequently Reported Adverse Events in Patients with Advanced Soft Tissue Sarcoma Treated with Pazopanib (All-Grade Incidence $\geq 20\%$) [11].

Adverse Event, %	Pazopanib (n = 240)	
	All Grades	Grade 3-4
Fatigue	65	14
Diarrhea	59	5
Nausea	56	3
Weight decrease	48	4
Hypertension	42	7
Appetite decrease	40	6
Hair color changes	39	0
Vomiting	33	3
Tumor pain	29	8
Dysgeusia	28	0
Headache	23	1
Musculoskeletal pain	23	2
Myalgia	23	2
Gastrointestinal pain	23	3
Dyspnea	20	5

had progressed after one to four lines of prior chemotherapy [14]. Pazopanib significantly prolonged progression-free survival (PFS), the primary end point, compared with placebo (median 4.6 vs. 1.6 months; hazard ratio [HR], 0.31; 95% confidence interval [CI], 0.24-0.40; $P < 0.0001$) but did not significantly prolong overall survival (OS; median 12.5 vs. 10.7 months; HR, 0.86; 95% CI, 0.67-1.11; $P = 0.2514$) [14]. Pazopanib also demonstrated benefit in a retrospective analysis of 47 Japanese patients with aSTS, nine of whom were ineligible for the PALETTE study because of tumor histology (ie, liposarcoma, dermatofibrosarcoma, or inflammatory myofibroblastic tumor). Based on a median duration of follow-up of 7.5 months (range, 1.4-20.3 months), objective response was 11% ($n = 5$, one of whom had dedifferentiated liposarcoma). Although durations of median PFS and OS were longer in patients with eligible histology, differences were not significant ($P = 0.15$ and $P = 0.55$, respectively) [15].

Pazopanib offers an effective and potentially safer alternative for second-line treatment following chemotherapy [11]. The toxicity profile of pazopanib seems to be favorable with respect to myelosuppression relative to the commonly prescribed chemotherapies, including doxorubicin, ifosfamide, and gemcitabine [16,17]; occurrence of severe myelosuppression is rare with the use of pazopanib [11]. In the PALETTE study, overall quality of life was not significantly worse for patients receiving pazopanib than for those receiving placebo (global health and quality-of-life scores did not differ significantly between treatment arms) [14]. Nonetheless, pazopanib is associated with important safety considerations; therefore, there is a need for health care providers to understand potential issues, vigilantly monitor for toxicity, and proactively manage adverse events (AEs) in a timely manner to ensure optimal patient outcomes.

Frequently Reported AEs with Pazopanib

Pazopanib has demonstrated manageable tolerability in patients

Table 2: Incidence of Selected Laboratory Abnormalities Occurring in $>10\%$ of Patients With Soft Tissue Sarcoma Treated With Pazopanib [11].

	Pazopanib (n = 240)	
	All Grades	Grade 3-4
Hematologic, %		
Leukopenia	44	1
Lymphocytopenia	43	10
Thrombocytopenia	36	4
Neutropenia	33	4
Chemistry, %		
AST increased	51	8
ALT increased	46	10
Glucose increased	45	<1
Albumin decreased	34	1
Alkaline phosphatase increased	32	3
Sodium decreased	31	4
Total bilirubin increased	29	1
Potassium increased	16	1

with aSTS, regardless of histology [11,14,15]. In the PALETTE study [11,14] with a median duration of treatment of 4.5 months (range, 0-24 months), dose interruptions and reductions were required in 58% and 38% of pazopanib recipients, respectively, and 17% of patients discontinued therapy because of AEs [11]. Frequently reported AEs with pazopanib in patients with aSTS enrolled in the PALETTE study are shown in Table 1, and select laboratory abnormalities occurring in $>10\%$ of patients are shown in Table 2. Commonly reported all-grade AEs included fatigue (65%), diarrhea (59%), nausea (56%), weight decrease (48%), and hypertension (42%); common grade 3-4 AEs were fatigue (14%), tumor pain (8%), hypertension (7%), and appetite decrease (6%) [11]. Hypertension, fatigue, diarrhea, anorexia, nausea and vomiting, hand-foot syndrome, and elevated liver enzymes were also common reasons for dose reductions [14]. In the retrospective study of Japanese patients with aSTS, significant differences in the incidence of AEs in PALETTE-eligible compared with PALETTE-ineligible patients were not found; however, frequency of dose skipping or dose reduction was higher in patients with ineligible histology [15].

Severe and fatal hepatotoxicity has been observed in clinical trials of pazopanib, and the prescribing information carries a warning of such [11]. Hepatotoxicity manifested as increased serum transaminase level (alanine transaminase [ALT] and aspartate transaminase [AST]) and bilirubin, typically within the first 4-5 months of treatment. In the PALETTE study, levels of ALT >3 times and >8 times the upper limit of normal (ULN) were reported in 18% and 5% of patients treated with pazopanib, respectively, compared with 5% and 2% of patients receiving placebo, respectively. A total of 2% of pazopanib recipients reported concurrent elevation in ALT level (>3 times ULN) and bilirubin level (twice ULN) in the absence of significant alkaline phosphatase level (>3 times ULN), compared with $<1\%$ of placebo recipients. One death (0.4% of patients) occurred in the pazopanib arm as a result of hepatic failure.

AE Management

Key management strategies for pazopanib-associated AEs include dose modifications, vigilant monitoring, proactive patient education, and timely treatment, when necessary [11]. Management strategies for select pazopanib-associated AEs will be described in more detail herein.

Diarrhea

Diarrhea associated with the use of pazopanib is commonly mild to moderate [11]. Patients should be advised about how to manage mild diarrhea and instructed to notify their health care provider in the event of moderate to severe diarrhea so that appropriate management can be implemented to minimize its impact [11,18]. Grade 1 (mild) diarrhea is defined as an increase of <4 stools/day over pretreatment; grade 2 (moderate) is defined as an increase of 4-6 stools/day or nocturnal stools; grade 3 (severe) is defined as an increase of ≥ 7 stools/day, or incontinence, or the need for parenteral support for dehydration; and grade 4 (very severe) is defined as diarrhea with physiological consequences that require intensive care or as diarrhea with hemodynamic collapse [19]. Patients should be informed to contact their physician if they experience >4 stools compared with baseline (before initiating pazopanib) [18].

The management strategy for mild diarrhea includes avoidance of lactose-containing products and alcohol, drinking 8-10 large glasses of clear liquids (eg, sports drinks or broth) daily; eating small, frequent meals (eg, rice, pasta, toast); and monitoring the number of stools per day and reporting symptoms such as fever or dizziness upon standing. Administration of standard-dose loperamide is also recommended [19]. Management of acute diarrhea includes the use of antimotility medications (eg, loperamide) in patients with grade 1-2 diarrhea or antisecretory agents (eg, octreotide) in those with grade 3-4 diarrhea, oral antibiotics (eg, fluoroquinolone), and treatment of dehydration with oral or intravenous rehydration therapy and nutrition [18,19].

Hepatic toxicity

In clinical trials of pazopanib, hepatotoxicity manifested as an increase in serum transaminase (ALT, AST) and bilirubin levels. This hepatotoxicity could be severe and fatal.

Serum liver enzymes should be monitored before initiating pazopanib, and monitoring should be repeated at weeks 3, 5, 7, and 9; at months 3 and 4; and as clinically indicated. Periodic monitoring should be performed thereafter [11]. Concomitant use of pazopanib and simvastatin increases the risk for ALT level elevation and should be undertaken with caution and close monitoring. Data are insufficient to assess the risk for concomitant administration of pazopanib with alternative statins.

The clinical management strategy for hepatic toxicity is shown in Figure 1. Temporary dose interruption of pazopanib is recommended in the event of isolated ALT level elevations >8 times ULN, and pazopanib should be permanently discontinued in the event of ALT levels >3 times ULN plus bilirubin level elevation >2 times ULN [11]. In patients with preexisting moderate hepatic impairment, a reduced starting dose of pazopanib 200 mg/day can be given, and pazopanib is not recommended in those with preexisting severe hepatic impairment [11]. Although no initial dose adjustment is necessary

in elderly patients, those ≥ 65 years of age might be at greater risk for hepatic toxicity [11].

Hypertension

As a class effect of VEGF inhibitors [18,20], pazopanib is associated with hypertension, which must be monitored for and managed promptly using standard antihypertensive therapy and pazopanib dose modification [11,14]. In clinical trials of pazopanib, approximately 1% of patients required permanent discontinuation of pazopanib because of hypertension [11].

Before initiating pazopanib, patients should be screened for prehypertension or undiagnosed hypertension [18], and blood pressure should be well controlled [11,20]. Patients should be encouraged to monitor their blood pressure frequently at home, especially during the initial weeks of therapy [18]. Because hypertension occurs early in the course of treatment (40% of cases occurred by day 9, and 90% of cases occurred in the first 18 weeks), patients receiving pazopanib should be instructed to monitor their blood pressure within 1 week of starting pazopanib and frequently thereafter [11,18]. In patients with a history of hypertension, poor hypertensive control, or cardiovascular comorbidities, blood pressure should be monitored more frequently [18,20].

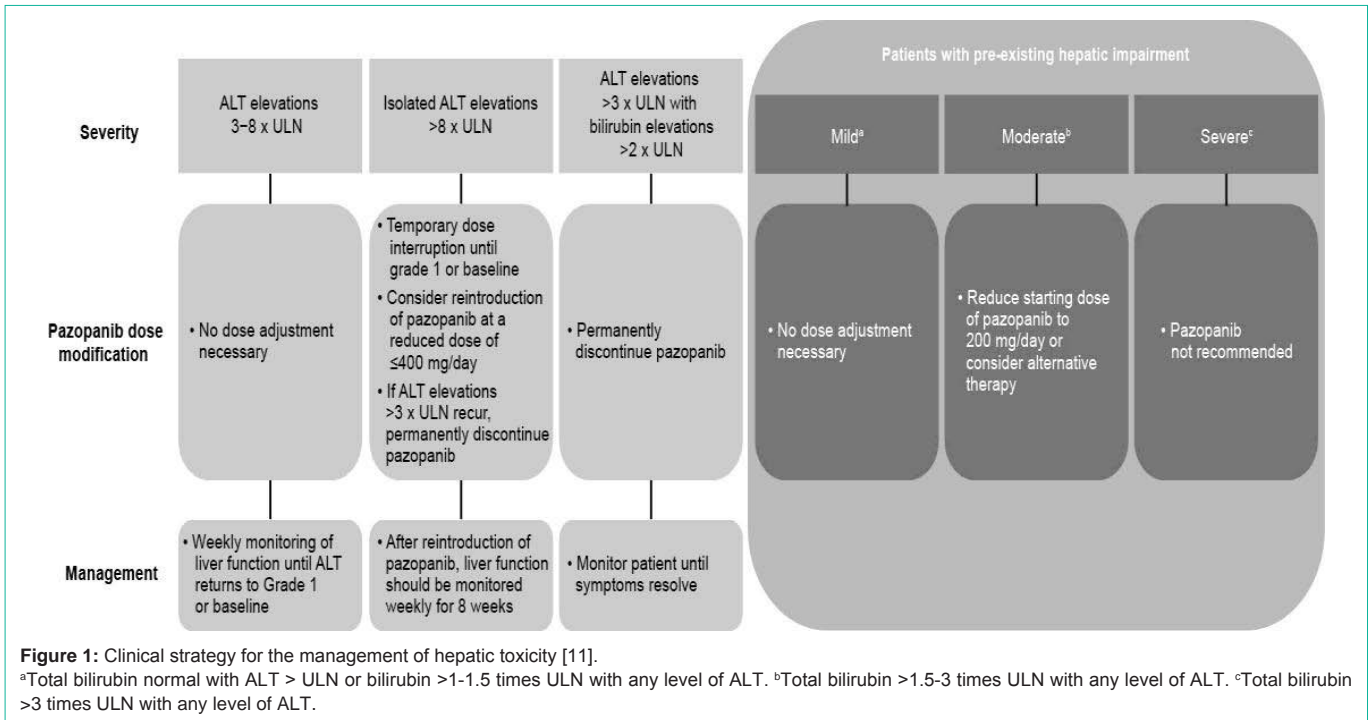
Medical intervention is necessary in cases of grade 3 hypertension, either by increasing the number of antihypertensive agents and/or by increasing doses of existing antihypertensives [18]. Angiotensin-converting enzyme (ACE) inhibitors, beta-blockers, diuretics, calcium channel blockers, and angiotensin 2 receptor antagonists have been used to treat TKI-induced hypertension, but there are no clear recommendations because of a lack of controlled studies [21]. It has been suggested that antihypertensives should be tailored to the individual [22], with ACE inhibitors preferred in patients with proteinuria, at risk for chronic kidney disease, or with metabolic syndrome [21].

Dose reduction of pazopanib should be considered when hypertension does not respond to medication. When there is evidence of hypertensive crisis or if hypertension is severe and persistent despite antihypertensive therapy and dose reduction, pazopanib should be discontinued [11]. Patients should be advised to seek immediate medical help if they experience symptoms of a severe increase in blood pressure, such as severe chest pain, severe headache, blurred vision, confusion, nausea and vomiting, severe anxiety, shortness of breath, or seizures, or if they pass out (become unconscious) [11].

Skin and hair color changes

Hair color changes and skin hypopigmentation are also common pazopanib-associated AEs. In the PALETTE study, 38% of patients in the pazopanib treatment arm experienced grade 1-2 skin hypopigmentation compared with 2% of patients in the placebo arm [14]; 39% of pazopanib-treated patients had hair color changes [11]. An increased incidence of hypopigmentation seems to be associated with prolonged duration of pazopanib therapy [3].

It has been speculated that skin and hair hypopigmentation is caused by the potent dual inhibition of c-Kit and PDGFR by pazopanib and that hypopigmentation may be a useful predictor of successful activity and/or clinical response [23]. Both c-Kit and



PDGF have been shown to be involved in melanocyte proliferation [24,25], and mutations in c-Kit are associated with skin and hair hypopigmentation syndromes [26-29].

Patients should be advised that depigmentation of the hair or skin might occur during treatment [11], leading to heightened sun sensitivity and increased risk for sunburn [23]. The use of sunscreen is advised.

Cardiac toxicity

In the PALETTE study, post baseline QT data were collected only if electrocardiographic abnormalities were reported as an AE. Post baseline values of 500-549 ms were reported in 0.4% of patients (1 of 240) treated with pazopanib and in zero placebo-treated patients [11]. No patients in the PALETTE study reported torsades de pointes, but this AE has been reported in <1% of patients (2 of 977) in pazopanib monotherapy trials. Although these events are rare, caution when initiating pazopanib is advised in patients with a history of QT interval prolongation, in patients taking antiarrhythmics or other medications that may prolong QT interval, and in those with relevant preexisting cardiac disease. Electrocardiography should be monitored at baseline and periodically thereafter, and electrolytes such as calcium, magnesium, and potassium should be maintained within normal ranges. Patients should be advised to inform their physicians of all concomitant medications they are taking [11]. Prediction of prolonged QT interval is not possible, but several risk factors have been identified for its development (Table 3) [30]. In the event of the occurrence of torsades de pointes, pazopanib should be immediately discontinued, electrolytes should be corrected, and a pacemaker (temporary or permanent) should be used to increase heart rate [30,31].

Cardiac dysfunction (eg, congestive heart failure, decreased left-ventricular ejection fraction [LVEF]) has been reported with

pazopanib [11]. In the PALETTE study, the rate of myocardial dysfunction with pazopanib compared with placebo was 11% (16 of 142) and 5% (2 of 40). Of the 16 pazopanib recipients in whom cardiac dysfunction developed, 14 had concurrent hypertension, which might have been a contributing factor, especially among patients at high risk such as those who had received prior anthracyclines [11]. In addition, congestive heart failure was reported in 1% of patients (3 of 240). Blood pressure should be monitored and hypertension should be managed promptly using a combination of antihypertension medications and dose modification of pazopanib [11,22]. Interruption of pazopanib with reinitiation at a reduced dose may be considered. Signs and symptoms of congestive heart failure should be carefully monitored. A thorough evaluation (including LVEF assessment) is recommended in patients who display evidence of congestive heart

Table 3: Risk Factors Associated With Development of Drug-Induced Torsade de Pointes.

Risk Factors
Female sex
Hypokalemia
Bradycardia
Recent conversion from atrial fibrillation
Congestive heart failure
Left ventricular hypertrophy
High drug concentration
Rapid rate of intravenous infusion with a QT-prolonging drug
Baseline QT prolongation
Subclinical long QT
Ion channel polymorphisms
Severe hypomagnesemia

Reproduced with permission from Kallergis et al. [30].

failure, and pazopanib should be discontinued [11,22]. Baseline and regular evaluation of LVEF is also recommended in patients at risk for cardiac dysfunction [11].

Hemorrhagic events

Hemorrhagic events, including epistaxis (8%) and mouth (3%) and anal hemorrhage (2%), were reported in the PALETTE study. Grade 4 hemorrhagic events (1% of patients) included intracranial, subarachnoid, and peritoneal hemorrhage. No fatal hemorrhaging events were reported, but they have occurred in other indications (0.9% of patients in RCC trials of pazopanib) [11].

Patients should be asked about a history of abnormal bleeding and advised to immediately call their health care provider if they experience unusual bleeding, bruising, or wounds that do not heal [11]. Pazopanib should not be used in patients with a history of hemoptysis or cerebral or clinically significant gastrointestinal hemorrhage in the preceding 6 months [11].

Arterial and venous thromboembolic events

Arterial thromboembolic events (myocardial infarction or ischemia and cerebrovascular accident) were observed in 2% of patients (4 of 240) in the PALETTE study; none were fatal. In addition, venous thromboembolic events (VTEs), including venous thrombosis and fatal pulmonary embolism (1% of patients [2 of 240]), were reported in 5% of patients [11]. Thrombotic microangiopathy (TMA), including thrombotic thrombocytopenic purpura and hemolytic uremic syndrome, has been reported in clinical trials of pazopanib in other indications. TMA was reversible with discontinuation of pazopanib and occurred within 90 days of initiating pazopanib [11].

Patients should be monitored for signs and symptoms of VTE and pulmonary embolism, and pazopanib should be used with caution in patients who are at increased risk for arterial thromboembolic events or who have a history of arterial thromboembolic events [11]. Pazopanib should not be used in any patient who had an arterial thromboembolic event within the previous 6 months. Patients should be monitored for signs and symptoms, and pazopanib should be permanently discontinued in the event of TMA. TMA should be managed as clinically indicated. Patients are advised to call their health care provider immediately if they experience new chest pain, trouble breathing, sudden shortness of breath, leg pain, swelling of the arms and hands or legs and feet, or a cool or pale arm or leg [11].

Gastrointestinal perforation and fistula

Gastrointestinal perforation or fistula was reported in 1% of STS patients (4 of 382) treated with pazopanib; these were fatal in 0.3% of patients (1 of 382) [11]. Pazopanib should be used with caution in patients with a history of intestinal bleeding or gastrointestinal perforation or fistula. Patients receiving pazopanib should be monitored for signs and symptoms, such as pain, swelling of the stomach area, vomiting blood, or black sticky stools [11].

Reversible posterior leukoencephalopathy syndrome

Reversible posterior leukoencephalopathy syndrome (RPLS), a potentially fatal neurologic disorder, has been reported in patients receiving pazopanib [11]. Patients should be informed of the signs and symptoms of RPLS (headache, seizure, lethargy, confusion, blindness, and other visual and neurologic disturbances; mild to severe hypertension may also be present) and advised to consult their

doctor if they have worsening of neurologic function consistent with RPLS. Magnetic resonance imaging is used to confirm its diagnosis, and pazopanib should be permanently discontinued [11].

Hypothyroidism

Hypothyroidism, defined as a simultaneous increase of thyroid-stimulating hormone (TSH) and decrease of thyroxine (T4) and characterized by symptoms of fatigue, dry skin, cold intolerance, muscle weakness, and constipation, is a common AE associated with VEGFR-TKIs [22,32]. Its precise mechanism is unknown. The incidence of hypothyroidism with pazopanib seems to be lower than with other VEGFR-TKIs [32]; in the PALETTE study, the incidence was 5% [11]. Proactive regular testing of thyroid function (TSH and T4 levels) is recommended [11], with management of hypothyroidism according to standard guidelines for levothyroxine replacement therapy [22,32].

Acute pancreatitis

The AE pancreatitis was recently shown to be associated with multitargeted VEGF-TKI agents, including pazopanib, in a meta-analysis. This analysis included 22 randomized phase 2 and phase 3 trials (one trial on pazopanib) and found a significant 1.95-fold increase in the risk for all grades of pancreatitis with use of VEGFR-TKIs ($P = 0.042$, 95% CI, 1.02-3.70) and found a non-significant trend of increased risk for severe (grade ≥ 3) pancreatitis (RR = 1.89, $P = 0.069$, 95% CI, 0.95-3.73) in patients receiving TKIs compared with control patients not receiving TKIs [33]. Pancreatitis was not reported in the PALETTE study [11]. However, pancreatitis did occur in the pazopanib trials for treatment of RCC, albeit with a low frequency of <1% (4 of 586), and pancreatitis was one of the adverse reactions identified in post-marketing experience [11]. Furthermore, two recent case reports documented acute pancreatitis in patients treated with pazopanib. In one case, a 68 year old woman with RCC who was treated with 800 mg pazopanib as first-line therapy developed elevated pancreatic enzyme levels that necessitated cessation of treatment after 6 months from the start of pazopanib treatment. The patient was able to continue treatment with 400 mg pazopanib after pancreatic enzyme levels normalized, a result of regular monitoring of pancreatic enzyme levels and occasional breaks in treatment to ensure normal enzyme levels [34]. In another case, an 82 year old woman with cutaneous angiosarcoma refractory to docetaxel treatment began therapy with pazopanib. Swelling of the pancreas occurred at 3 months, but she continued treatment until, after 5 months of treatment, nausea, appetite loss, and elevated serum amylase and lipase levels developed, along with pancreatic swelling that was evident by computed tomography, which did not resolve with cessation of treatment. A pancreatic pseudocyst developed, which was removed with endoscopic ultrasound-guided pseudocyst drainage using a flared-end fully covered self-expandable metallic stent, and symptoms resolved without recurrence [35].

Both case studies highlight the fact that patients might show early signs of pancreatic abnormalities before more severe symptoms develop. If a patient begins to develop signs of acute pancreatitis, including elevated serum amylase and lipase levels or pancreatic swelling, it is imperative that physicians closely monitor changes in signs and symptoms of pancreatitis and consider reducing or ceasing treatment with pazopanib, if necessary.

Pneumothorax

Pneumothorax occurred in 3% of the patients (8 of 240) treated with pazopanib, compared with zero patients in the placebo arm in the PALETTE study [11]. Therefore, pneumothorax was an uncommon AE in the PALETTE trial. However, it was more common in a retrospective analysis of 47 Japanese patients with aSTS in which 11% (5 of 47) and 4% (2 of 47) developed any-grade or grade 3-4 pneumothorax, respectively [15]. Additionally, a case series of 43 patients with locally advanced or metastatic non-liposarcoma STS reported an incidence of pneumothorax of 14% (6 of 43) [36]. All six patients who developed pneumothorax in this case series had subpleural pulmonary or pleural metastases at the start of treatment, suggesting a potential link between pulmonary metastases and pneumothorax. Therefore, pneumothorax is a possible AE that might occur with pazopanib treatment, particularly in patients with pulmonary metastases. Patients should be informed of this potential risk, and physicians should advise patients to report new onset of dyspnea and chest pain [11]. If pneumothorax develops, it may be treated by reducing or stopping treatment or by chest tube drainage [15].

Proteinuria

Proteinuria, including nephrotic syndrome in one patient, was reported in 1% of patients (2 of 240) treated with pazopanib in the PALETTE study, compared with zero patients who received placebo [11]. Urinalysis is recommended at baseline and periodically during treatment. Where clinically indicated, a follow-up measurement of 24-hour urine protein should be performed. If 24-hour urine protein ≥ 3 g is observed, pazopanib should be interrupted and the dose should be reduced. Discontinuation of pazopanib is advised for repeat episodes despite dose reductions [11].

Conclusion

aSTS is a complicated disease with limited treatment options. Pazopanib is a multitargeted, small-molecule receptor that is an effective alternative for second-line treatment after chemotherapy [11]. This agent is generally tolerated; severity of most AEs is grade 1 or 2, and use of this agent rarely results in the severe myelosuppression that commonly occurs with chemotherapy [16,17]. Nonetheless, pazopanib is associated with important AEs of which health care professionals and patients should be aware.

A small survey, conducted in April 2013, of nurses (n = 6) working in the outpatient sarcoma department of Memorial Sloan Kettering Cancer Center revealed inconsistencies with regard to the depth of patient education about pazopanib provided in the clinic. Findings reinforced the need for standardizing internal training programs designed to assist health care professionals in adequately educating patients and their caregivers regarding safe pazopanib use [18].

Patients should proactively be taught to recognize and report signs and symptoms of toxicity, and health care providers should implement management strategies in a timely manner. Most pazopanib-associated AEs can be safely managed with dose modification.

Because of the challenges patients face in coping with aSTS-associated symptoms, occurrence of treatment-related toxicity further compromises their daily experience and burden. Diligent

monitoring and proactive management of signs and symptoms of potential AEs are critical aspects of patient care with pazopanib, both to optimize the likelihood of safe use and to improve patients' daily experience with treatment.

Acknowledgment

Medical editorial/writing assistance was provided by ApotheCom (Yardley, PA) and was funded by Novartis Pharmaceuticals Corporation.

References

- American Cancer Society. Sarcoma: adult soft tissue cancer. American Association of Pharmaceutical Scientists. 2016.
- Grimer R, Judson I, Peake D, Seddon B. Guidelines for the management of soft tissue sarcomas. *Sarcoma*. 2010; 506182.
- Sleijfer S, Ray-Coquard I, Papai Z, Le Cesne A, Scurr M, Schöffski P, et al. Pazopanib, a multikinase angiogenesis inhibitor, in patients with relapsed or refractory advanced soft tissue sarcoma: a phase II study from the European organisation for research and treatment of cancer-soft tissue and bone sarcoma group (EORTC study 62043). *J Clin Oncol*. 2009; 27: 3126-3132.
- National Comprehensive Cancer Network, Inc. NCCN Clinical Practice Guidelines in Oncology. Soft Tissue Sarcoma. 2015.
- Linch M, Miah AB, Thway K, Judson IR, Benson C. Systemic treatment of soft-tissue sarcoma-gold standard and novel therapies. *Nat Rev Clin Oncol*. 2014; 11: 187-202.
- Wagner MJ, Amodu LI, Duh MS, Korves C, Solleza F, Manson SC, et al. A retrospective chart review of drug treatment patterns and clinical outcomes among patients with metastatic or recurrent soft tissue sarcoma refractory to one or more prior chemotherapy treatments. *BMC Cancer*. 2015; 15: 175.
- Santoro A, Tursz T, Mouridsen H, Verweij J, Steward W, Somers R, et al. Doxorubicin versus CYVADIC versus doxorubicin plus ifosfamide in first-line treatment of advanced soft tissue sarcomas: a randomized study of the European Organization for Research and Treatment of Cancer Soft Tissue and Bone Sarcoma Group. *J Clin Oncol*. 1995; 13: 1537-1545.
- Judson I, Verweij J, Gelderblom H, Hartmann JT, Schöffski P, Blay JY, et al. Doxorubicin alone versus intensified doxorubicin plus ifosfamide for first-line treatment of advanced or metastatic soft-tissue sarcoma: a randomised controlled phase 3 trial. *Lancet Oncol*. 2014; 15: 415-423.
- Antman K, Crowley J, Balcerzak SP, Rivkin SE, Weiss GR, Elias A, et al. An intergroup phase III randomized study of doxorubicin and dacarbazine with or without ifosfamide and mesna in advanced soft tissue and bone sarcomas. *J Clin Oncol*. 1993; 11: 1276-1285.
- Bramwell VH. Management of advanced adult soft tissue sarcoma. *Sarcoma*. 2003; 7: 43-55.
- GlaxoSmithKline. Votrient (pazopanib) [prescribing information]. Research Triangle Park. 2015.
- European Medicines Agency. Summary of opinion (post authorisation). Votrient. 2016.
- Wilky BA, Meyer CF, Trent JC. Pazopanib in sarcomas: expanding the PALETTE. *Curr Opin Oncol*. 2013; 25: 373-378.
- Graafvander WT, Blay JY, Chawla SP, Kim DW, Bui-Nguyen B, Casali PG, et al. Pazopanib for metastatic soft-tissue sarcoma (PALETTE): a randomised, double-blind, placebo-controlled phase 3 trial. *Lancet*. 2012; 379: 1879-1886.
- Nakano K, Motoi N, Inagaki L, Tomomatsu J, Gokita T, Ae K, et al. Differences in the responses to pazopanib and the prognoses of soft tissue sarcomas by their histological eligibility for the PALETTE study. *Jpn J Clin Oncol*. 2015; 45: 449-455.
- Lorigan P, Verweij J, Papai Z, Rodenhuis S, Le Cesne A, Leahy MG, et al. Phase III trial of two investigational schedules of ifosfamide compared with standard-dose doxorubicin in advanced or metastatic soft tissue sarcoma: a European Organisation for Research and Treatment of Cancer Soft Tissue and Bone Sarcoma Group Study. *J Clin Oncol*. 2007; 25: 3144-3150.

17. Maki RG, Wathen JK, Patel SR, Priebe DA, Okuno SH, Samuels B, et al. Randomized phase II study of gemcitabine and docetaxel compared with gemcitabine alone in patients with metastatic soft tissue sarcomas: results of sarcoma alliance for research through collaboration study 002 [corrected]. *J Clin Oncol*. 2007; 25: 2755-2763.
18. Holland J, Flaherty C. Nursing considerations for patients with sarcoma on pazopanib therapy. *Clin J Oncol Nurs*. 2015; 19: 59-62.
19. Benson AB 3rd, Ajani JA, Catalano RB, Engelking C, Kornblau SM, Martenson JA Jr, et al. Recommended guidelines for the treatment of cancer treatment-induced diarrhea. *J Clin Oncol*. 2004; 22: 2918-2926.
20. Escalante CP, Zalpour A. Vascular endothelial growth factor inhibitor-induced hypertension: basics for primary care providers. *Cardiol Res Pract*. 2011; 816897.
21. Izzedine H, Ederhy S, Goldwasser F, Soria JC, Milano G, Cohen A, et al. Management of hypertension in angiogenesis inhibitor-treated patients. *Ann Oncol*. 2009; 20: 807-815.
22. Cohen RB, Oudard S. Antiangiogenic therapy for advanced renal cell carcinoma: management of treatment-related toxicities. *Invest New Drugs*. 2012; 30: 2066-2079.
23. Sideras K, Menefee ME, Burton JK, Erlichman C, Bible KC, Ivy SP. Profound hair and skin hypopigmentation in an African American woman treated with the multi-targeted tyrosine kinase inhibitor pazopanib. *J Clin Oncol*. 2010; 28: 312-313.
24. Halaban R, Moellmann G. White mutants in mice shedding light on humans. *J Invest Dermatol*. 1993; 100: 176-185.
25. Lazar-Molnar E, Hegyesi H, Toth S, Falus A. Autocrine and paracrine regulation by cytokines and growth factors in melanoma. *Cytokine*. 2000; 12: 547-554.
26. Giebel LB, Spritz RA. Mutation of the KIT (mast/stem cell growth factor receptor) proto-oncogene in human piebaldism. *Proc Natl Acad Sci U S A*. 1991; 88: 8696-8699.
27. Richards KA, Fukai K, Oiso N, Paller AS. A novel KIT mutation results in piebaldism with progressive depigmentation. *J Am Acad Dermatol*. 2001; 44: 288-292.
28. Jia WX, Xiao XM, Wu JB, Ma YP, Ge YP, Li Q, et al. A novel missense KIT mutation causing piebaldism in one Chinese family associated with café-au-lait macules and intertriginous freckling [abstract]. *Ther Clin Risk Manag*. 2015; 11: 635-638.
29. Yin XY, Ren YQ, Yang S, Xu SX, Zhou FS, Du WH, et al. A novel KIT missense mutation in one Chinese family with piebaldism. *Arch Dermatol Res*. 2009; 301: 387-389.
30. Kallergis EM, Goudis CA, Simantirakis EN, Kochiadakis GE, Vardas PE. Mechanisms, risk factors, and management of acquired long QT syndrome: a comprehensive review. *ScientificWorldJournal*. 2012; 212178.
31. Nachimuthu S, Assar MD, Schussler JM. Drug-induced QT interval prolongation: mechanisms and clinical management. *Ther Adv Drug Saf*. 2012; 3: 241-253.
32. Bianchi L, Rossi L, Tomao F, Papa A, Zoratto F, Tomao S. Thyroid dysfunction and tyrosine kinase inhibitors in renal cell carcinoma. *Endocr Rel Cancer*. 2013; 20: 233-245.
33. Ghatalia P, Morgan CJ, Choueiri TK, Rocha P, Naik G, Sonpavde G. Pancreatitis with vascular endothelial growth factor receptor tyrosine kinase inhibitors. *Crit Rev Oncol Hematol*. 2015; 94: 136-145.
34. Russano M, Vincenzi B, Venditti O, D'Onofrio L, Ratta R, Guida FM, et al. Pazopanib and pancreatic toxicity: a case report. *BMC Res Notes*. 2015; 8: 196.
35. Kawakubo K, Hata H, Kawakami H, Kuwatani M, Kawahata S, Kubo K, et al. Pazopanib-Induced Severe Acute Pancreatitis. *Case Rep Oncol*. 2015; 8: 356-358.
36. Verschoor AJ, Gelderblom H. Pneumothorax as adverse event in patients with lung metastases of soft tissue sarcoma treated with pazopanib: a single reference centre case series. *Clin Sarcoma Res*. 2014; 4: 14.