

Case Report

Sarcomatoid Carcinoma of Tongue: A Rare Case and its Innovative Surgical Management

Sinha R¹, Singh RK^{1*}, Kumar S², Raghwendra KH², Singh A³ and Biswas NR⁴

¹Department of Otorhinolaryngology, Indira Gandhi Institute of Medical Sciences, Patna, India

²Department of Anesthesiology, Indira Gandhi Institute of Medical Sciences, Patna, India

³Department of Pathology, Indira Gandhi Institute of Medical Sciences, Patna, India

⁴Department of Clinical Pharmacology, Indira Gandhi Institute of Medical Sciences, Patna, India

*Corresponding author: Singh RK, Department of Otorhinolaryngology, Indira Gandhi Institute of Medical Sciences, Sheikhpura, Patna, India

Received: June 09, 2016; Accepted: June 23, 2016;

Published: June 27, 2016

Introduction

Sarcomatoid Carcinoma (also known as carcinosarcoma, spindle cell carcinoma, pleomorphic carcinoma, pseudo sarcoma, true malignant mixed tumour) is an extremely rare, aggressive biphasic tumour composed of epithelial and stromal components. In the head and neck region it is commonly seen in the larynx. Oral cavity and tongue is a rare site of origin. Miyajima Y et al in 2005 mentioned only six cases of carcinosarcoma involving tongue has been reported including his case. Although couple of theories have been propounded to explain the dual origin of this tumor however, alcohol consumption, smoking or previous irradiation are thought to be the precipitating factors. Suzuki H et al reported amplification of cyclin D1 gene amplification in a case of carcinosarcoma of tongue [1-6]. It occurs in elderly age group of 6th to 7th decade with male predilection [7]. Our purpose is to report a case of sarcomatoid carcinoma of tongue and discuss the innovative surgical management of this rare entity.

Case Presentation

A 49 year old male presented to the department of Otorhinolaryngology with an ulcer over right side of tongue since 3 months. He had history of chronic tobacco chewing. On examination there was a single approximately 2 x 1.5 x 1 cm irregular ulcer over right lateral border of tongue in posterior one-third with induration extending medially and towards base of approximately 3.5 x 2.5 x 1 cm. It bled on touch while, the tongue was mobile. There were no neck nodes palpable. The initial biopsy was inconclusive after which an incisional biopsy of the ulcer revealed tumour cells consistent with sarcomatoid carcinoma.

Radiological findings

Magnetic Resonance Imaging of the tongue was advised which revealed a 3.5 x 3 x 1.5 cm hyper intense lesion on T2 weighted imaging involving posterior one-third of right lateral border of tongue involving base with muscular invasion not crossing midline.

Abstract

Sarcomatoid Carcinoma is an extremely rare, aggressive biphasic tumour composed of epithelial and stromal components. In the head and neck region it is commonly seen in the larynx. Oral cavity and tongue is a rare site of origin. Only a handful of previously reported cases of carcinosarcoma of the tongue were found on searching the available English literature to the best of our knowledge. Our purpose is to report a rare case of sarcomatoid carcinoma of tongue and discuss the innovative surgical management of this rare entity.

Keywords: Carcinosarcoma; Tongue; Biphasic; Malignant

Management

A provisional diagnosis of Sarcomatoid Carcinoma was made on biopsy findings. Hematological workup was within normal limit. There was no history of any co-morbidities and systemic examination

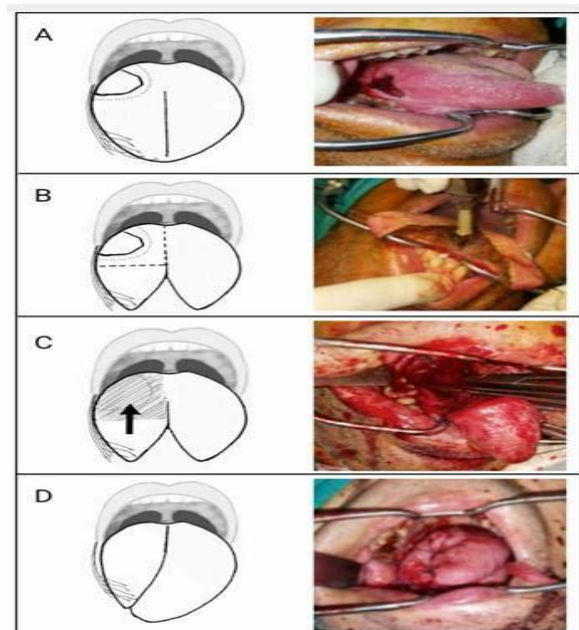


Figure 1: Diagrammatic representation with operative photographs of a newer technique for repair of large tongue defect with tongue transposition. (A) Showing ulcer of approximately 2 x 1.5 x 1 cm on posterior one-third of right lateral border of tongue extended towards base with indurate area of 3.5 x 3 x 1.5 cm (dotted area). (B) Midline tongue splitting incision and wide local excision of mass with preserved neurovascular structures. (C) Posterior right tongue defect with anterior healthy tongue graft (arrow showing direction of transposition of tongue graft). (D) Showing well vascularized posterior transposed tongue graft.

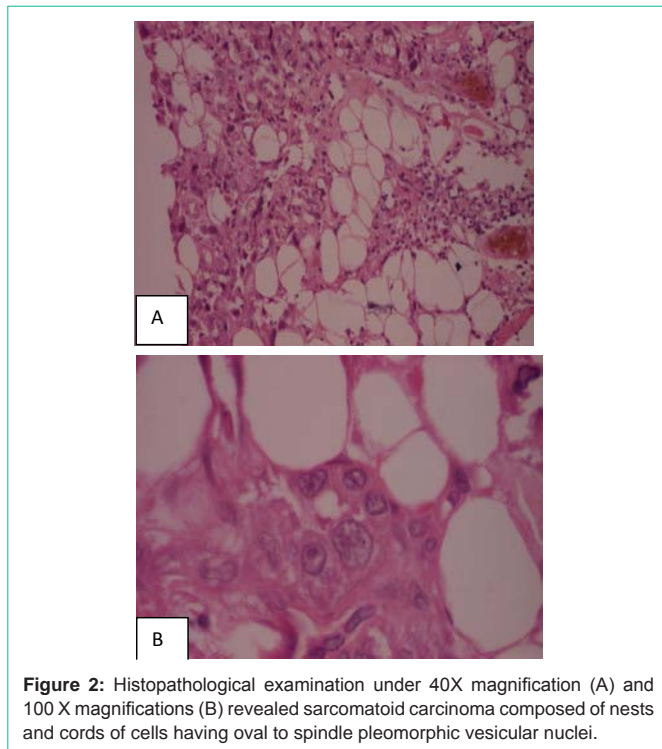


Figure 2: Histopathological examination under 40X magnification (A) and 100 X magnifications (B) revealed sarcomatoid carcinoma composed of nests and cords of cells having oval to spindle pleomorphic vesicular nuclei.

was unremarkable. We planned for surgical management followed by concurrent chemo radiation. Wide local excision of the mass including ipsilateral supra- omohyoid neck dissection with reconstruction was done by an innovative approach. First, a midline tongue splitting incision was made up to anterior two-third. The tumor mass on right side was meticulously dissected from the surrounding structures preserving the vascularity with wide healthy margins extending up to the base of tongue and midline. The entire tumour mass was resected along with tissue from midline of tongue. Next, the posterior defect of tongue on right side was reconstructed by carefully suturing the anterior right part to the base of tongue and tonsil lingual sulcus and with the left half of the tongue in midline using absorbable sutures (Figure 1A, 1B, 1C, 1D). The immediate postoperative period was uneventful. Patient was kept on nasogastric feeding for about a week followed by oral intake. Later, he underwent 2 cycles of concurrent chemotherapy and radiotherapy. The cisplatin in the dose of 100mg per m² and Adriamycin 50mg per m² in divided doses of two cycles at the interval of two weeks were given for the purpose of radiosensitization, locoregional tumor control and control of distance metastasis. The concurrent radiotherapy of total 70 Gy 5 days in week in 35 fractions was administered. Patient is on regular follow-up with no recurrence.

Histopathological findings

The gross specimen from the right lateral border of the tongue measured 4.5 x 3.5 x 2 cm. The microscopic examination revealed Sarcomatoid carcinoma composed of nests and cords of cells having oval to spindle pleomorphic vesicular nuclei (Figure 2A, 2B). All the resected margins were clear from the tumor. Sections from tissue from midline and base were free of tumor. Further, immunohistochemistry showed CK 4+ and p63 2+ score consistent with sarcomatoid carcinoma (Figure 3A, 3B).

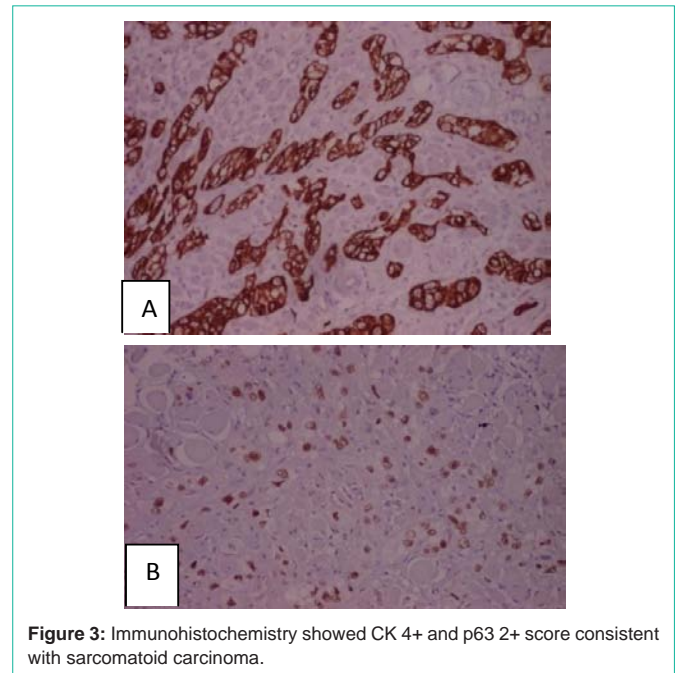


Figure 3: Immunohistochemistry showed CK 4+ and p63 2+ score consistent with sarcomatoid carcinoma.

Outcome

The graft was well taken with mobile and healthy looking tongue and no functional impairment.

Discussion

Sarcomatoid Carcinoma is defined as a malignant tumor that is a mixture of carcinoma (cancer of epithelial tissue, which is skin and tissue that lines or covers the internal organs) and sarcoma (cancer of connective tissue, such as bone, cartilage, and fat) (Source: National Cancer Institute, USA). It is an extremely rare tumour in Head-and-Neck sites originating particularly from aerodigestive tract, particularly larynx and hypo pharynx. Oral cavity is involved less than 2% of all oral cavity tumors, however only few cases of sarcomatoid Carcinoma of tongue have been reported in the English literature [1-6]. It occurs in elderly age group with male gender predilection. The condition is mostly idiopathic; however radiation and trauma have been implicated by some authors [7]. Accumulation of genetic mutations has also been suggested like the amplification of cyclin D1 gene plays a role in the molecular pathogenesis of sarcomatoid Carcinoma of the tongue, at least in some cases [5]. Grossly, the lesion is usually polypoidal, but about one-third of cases exhibit ulceration and endophytic growth. In our case, we found the lesion to be endophytic. Extensive infiltration and tissue destruction are common, so is perineural invasion and angioinvasion. Lymphatic spread uncommon. Hence the diagnosis is essentially by an incisional biopsy and histopathological examination. Histologically, such tumors show a pleomorphic spindle cell component along with invasive cancer or Carcinoma in situ [8]. The differential diagnosis mostly includes soft tissue sarcoma and malignant melanoma. The treatment protocol for sarcomatoid carcinoma is supposed to be the same as for squamous cell carcinoma which consists of surgical excision of the lesion with an adequate margin [9-11]. However, it seems to be more aggressive than squamous cell carcinoma of same stage. There is no standard management of sarcomatoid carcinoma due to its rarity. However,

most of the reported cases were treated in the same way as squamous cell carcinoma. Hence we adopted same policy for the tumour resection with ipsilateral supra-omohyoid neck dissection followed by chemo-radiation in our case. However, the extent of disease towards base of tongue demanded substantial reconstruction, which we have successfully achieved through an innovative technique described in the case report. Adjuvant radiotherapy and chemotherapy may be beneficial in patients who have positive surgical margin or who have nodal metastasis [10]. Chemotherapy may reduce the risk of recurrence or metastasis from sarcomatous component. Prognosis of these tumors is poor with mean survival time of 2 years [11].

References

1. Takata T, Nikai H, Ogawa I, Ijuhin N. Ultrastructural and immunohistochemical observations of a true malignant mixed tumor (carcinosarcoma) of the tongue. *J Oral Pathol Med.* 1990; 19: 261-265.
2. Hansen LT, Kristensen S, Moesner J. Polypoidal carcinosarcoma of the oropharynx: a clinicopathological and immunohistochemical study. *J Laryngol Otol.* 1995; 109: 459-465.
3. Gorsky M, Epstein JB. Head and neck and intra-oral soft tissue sarcomas. *Oral Oncol.* 1998; 34: 292-296.
4. Orita Y, Ogawara T, Yorizane T, Yamatoril, Nishizaki K. True carcinosarcoma of the tongue—a case report. *Otolaryngol Head Neck Surg (Tokyo).* 2000; 72: 219–222.
5. Suzuki H, Yamashiro K, Yoshida C, Fujioka Y. Carcinosarcoma of the tongue with cyclin D1 gene amplification. *Arch Pathol Lab Med.* 2001; 125: 433-436.
6. Y. Miyajima, K. Onizawa, H. Kamma, and H. Yoshida. "Carcinosarcoma of the tongue," *Oral Oncology Extra.* 2006; 42: 78–81.
7. Greene GW Jr, Bernier JL. Spindle-cell squamous carcinoma of the lip; report of four cases. *Oral Surg Oral Med Oral Pathol.* 1959; 12: 1008-1016.
8. Tse JJ, Aughton W, Zirkin RM, Herman GE. Spindle cell carcinoma of oral mucosa: case report with immunoperoxidase and electron microscopic studies. *J Oral Maxillofac Surg.* 1987; 45: 267-270.
9. Oktay M, Kokenek-Unal TD, Ocal B, Saylam G, Korkmaz MH, Alper M. Spindle cell carcinoma of the tongue: a rare tumor in an unusual location. *Patholog Res Int.* 2011; 1-6.
10. Berthelet E, Shenouda G, Black MJ, Picariello M, Rochon L. Sarcomatoid carcinoma of the head and neck. *Am J Surg.* 1994; 168: 455-458.
11. Singh RK, Sinha R, Singh A, Suman S, Priya M. Huge Carcinosarcoma of the Endolarynx: a Rare Tumour with Unusual Presentation. *Indian J Surg Oncol.* 2015.