

Case Report

Nasopharyngeal Botryoid Type Embryonal Rhabdomyosarcoma: Case Report

Ismi O^{1*}, Cinpolat O¹, Bucioğlu H¹, Çıtak EC², Arpacı RB³, Eti N³, Vayısoglu Y¹ and Unal M¹

¹Department of Otorhinolaryngology, University of Mersin, Turkey

²Department of Pediatric Oncology, University of Mersin, Turkey

³Department of Pathology, University of Mersin, Turkey

***Corresponding author:** Onur Ismi, Department of Otorhinolaryngology, Mersin Üniversitesi Tıp Fakültesi Hastanesi, Kulak BurunBoğaz A.D Çiftlikköy Kampüsü, Çiftlikköy/Yenişehir-Mersin, Turkey

Received: September 02, 2015; **Accepted:** November 02, 2015; **Published:** November 04, 2015

Abstract

Rhabdomyosarcoma is the malignant mesenchymal tumor with skeletal muscle differentiation. They comprise only 2-5% of all soft tissue sarcomas in the adult age group, whereas 60% of all soft tissue sarcomas in childhood. They are the most common histologic type among pediatric nasal cavity and paranasal sinus tumors. For tumors which can be totally excised surgically; prognosis is favorable, whereas metastatic ones can be life threatening in the pediatric age group. In the head and neck region; rhabdomyosarcoma can manifest with nonspecific signs and symptoms which makes the early diagnosis difficult. We presented a case of nasopharyngeal and nasal cavity rhabdomyosarcoma in a three years old patient who was surgically treated with additional radiotherapy and chemotherapy under the light of current literature.

Keywords: Rhabdomyosarcoma; Embryonal; Botryoid; Nasopharynx; Endoscopic sinus surgery

Introduction

Rhabdomyosarcoma (RMS) is the malignant mesenchymal tumor with skeletal muscle differentiation [1]. They probably arise from satellite cells associated with skeletal muscle embryogenesis [2]. They show great incidence variability according to age groups, with a great dominance in the pediatric age. They are only 2-5% of all soft tissue sarcomas in the adult age group, whereas 60% of all soft tissue sarcomas in childhood [2]. Although rarely seen in the head and neck region in adults; 40 % have head and neck primaries in the pediatric age group [3]. For pediatric RMS cases; most of them have orbital primaries in the head and neck region, nasal cavity RMS cases are rarely seen [1]. But due to scarcity of nasal cavity and paranasal sinus tumor cases in childhood; in fact they are the most common histologic type among all nasal cavity and paranasal sinus tumors in this age group [3]. The exact pathogenesis is not known; viral infections, genetic factors, chemical and environmental exposure are all suggested to be the predisposing factors [4]. Hallmark translocation t(2;13) (q35;14) in alveolar type strongly suggests a genetic basis [5]. Although RMS was firstly described over a century ago by Weber in 1854 [6] there is still debates about treatment algorithms for head and neck RMS cases in the pediatric age group due to scarcity of single institution case series. In this case report; we presented a nasopharynx and nasal cavity RMS in a three years old patient with nasal obstruction complaint.

Case Presentation

Otherwise healthy three years old male patient was admitted to our tertiary center Otorhinolaryngology department with the complaint of nasal obstruction and hearing loss. Nasal obstruction has increased for three months and sleep apnea was well recognized by his parents for ten days. On his physical examination; there was a solid mass in the right nasal cavity filling also nasopharynx (Figure 1). On otoscopic examination; there was serous otitis media with air-fluid levels in right ear. Maxillofacial and neck magnetic resonance imaging (MRI) revealed a 3x2 cm. solid mass in right nasal cavity

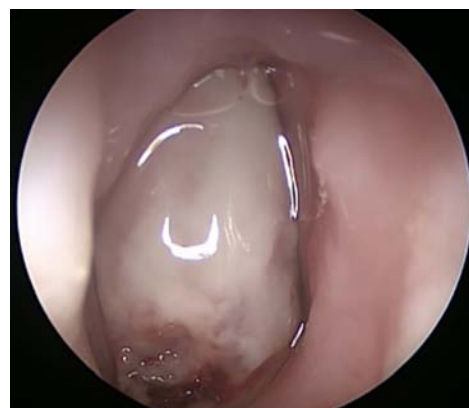

Figure 1: Endoscopic view of right nasal cavity tumor has been demonstrated.

starting at the middle meatus level with fulfilling the nasopharynx without intracranial extension or lymph node metastasis (Figure 2). Tissue biopsy under general anesthesia was performed. Histopathological investigation of the tumor revealed a hypercellular malignant neoplasm formed by atypical rhabdomyoblastic cells under the epithelium (Figure 3A). Tumor cells showed cytoplasmic immunohistochemical staining with desmin (Figure 3B). The final diagnosis was botryoid type embryonal rhabdomyosarcoma. Thoracic computerized tomography was free of metastasis. TNM staging of the tumor was T1N0M0. Endoscopic tumor excision was done under general anesthesia. Intraoperatively; tumor had no bone invasion but fulfilled the nasopharynx. Radiotherapy and chemotherapy including vincristine regimen was started by Pediatric Oncology department in the postoperative period. The patient is free of disease for 2 years and under follow-up with Pediatric Oncology department.

Discussion

Among sinonasal malignancies in the pediatric age group, RMS is the most common histologic type [7]. According to USA data

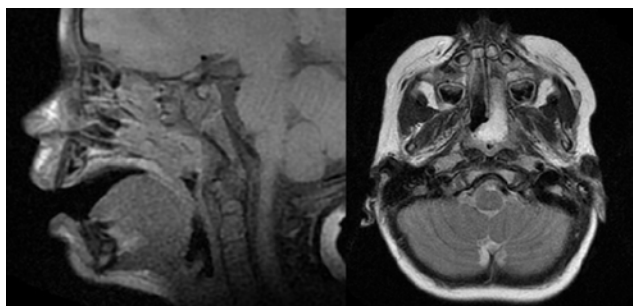


Figure 2: Magnetic Resonance Imaging of the patient was shown.

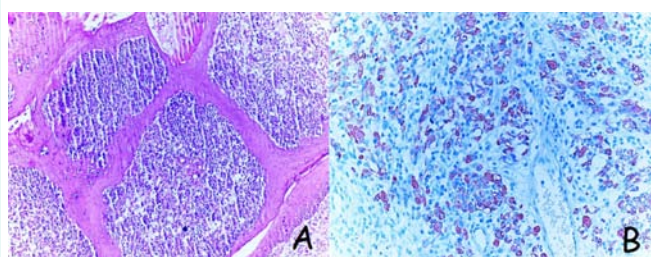


Figure 3: Histopathological features of the tumor was presented.
3A. Hypercellular malignant neoplasm formed by atypical rhabdomyoblastic cells under the epithelium (H&E, X100).
3B. Tumor cells showed cytoplasmic immunohistochemical staining with desmin. (Desmin, X200).

they comprise 47% of all pediatric sinonasal malignancies, the most common effected site is nasal cavity and nasopharynx. Paranasal sinuses are less affected probably due to undeveloped paranasal sinuses in the pediatric age group [7].

Sign and symptoms of RMS differ according to primary site. RMS of nasal cavity mostly manifests with nasal obstruction, rhinorrhea and recurrent otitis media, but there is no pathognomonic, tumor specific sign for early diagnosis [1]. Our patient had also nonspecific nasal obstruction and otitis media with effusion symptoms.

Subtypes of RMS include embryonal (with botyroid variant), alveolar and pleomorphic subtypes according to World Health Organization and Intergroup Rhabdomyosarcoma Studies Committee (IRS). With botyroid variant embryonal form accounts 60-66% of all [1]. Botyroid variant is a morphological subtype of embryonal form, it derives its name from gross appearance which resembles a cluster of grapes (Botyrs in Greek means a cluster of grapes) [8]. Younger children have embryonal form dominancy whereas adolescents have alveolar type mostly [2]. Prognostic factors for children with head and

neck RMS are important for predicting survival. Surgically treated tumors have a favorable prognosis. IRS group raised a post-surgical grading system for prognosis (Table 1) [9]. From group I to IV 5-year survival rates decrease from 93% to 30% [2]. For patients in group I (totally excised tumor) embryonal form has a more favorable survival rates than alveolar form [9]. When molecular basis of embryonal and alveolar forms are compared; PAX3-FOXO1 fusion gene which forms by translocation of chromosome 2 and 13 is responsible from activating proliferation and aggressive behavior in alveolar form RMS. PAX3-FOXO1 fusion gene has been found roughly in 60% of all alveolar RMS cases [10]. For primary site; head and neck RMS can be classified into three categories: orbital, parameningeal and non-orbital non-parameningeal. Nasal cavity, nasopharynx, paranasal sinuses, infratemporal and pterygopalatine fossa are classified in the parameningeal group. Due to lower chance of total excision in these anatomic regions, tumors are mostly accepted to be a clinically group III disease according to IRS group classification [11]. With regards to the imaging findings of RMS cases; there are multiple pathologies including both benign and malignant ones in the differential diagnosis list [12] (Table 2).

The treatment of head and neck RMS had a favorable progression over years. According to IRS group cure rate was 25% in 1970s for these soft tissue cancers, whereas overall long-term survival rate for non-metastatic disease is expected to exceed 80% now [9]. Although primary treatment of head and neck RMS was accepted to be surgery before multi-modality treatment era; chemotherapy and radiotherapy combination with surgery had been shown to be the best treatment protocol for increasing survival rates [11]. Surgery is the cornerstone of this combined modality treatment because volume of the residual tumor is the most important factor for survival. Except orbital primaries, head and neck RMS cases must be treated with surgery, with total excision if possible [11]. In order to decide if the tumor is amenable to total excision, preoperative assessment of the tumor size, bone erosion and intracranial invasion using imaging modalities such as computerized tomography and MRI is very important [8]. Orbital RMS cases have an excellent prognosis with radiotherapy and chemotherapy without surgery. Histopathologic type of the tumor is also important for choosing the treatment modality. With unfavorable pathologies such as alveolar or undifferentiated RMS, adjuvant radiotherapy must be added to surgery even after total surgical excision. For embryonal type; if total excision could be achieved the patient can be followed-up for metastasis without additional treatment [11]. On the other hands; nasal cavity and nasopharyngeal tumors have a lower chance for total excision and are classified as clinical group III according to IRS group classification [11]. For our

Table 1: Surgical-Pathological Grouping system of pediatric rhabdomyosarcoma cases according to Intergroup Rhabdomyosarcoma Study [9].

GROUP	DEFINITION
GROUP I	Localized disease, completely resected
GROUP II	Total gross resection with evidence of regional spread
GROUP IIA	Grossly resected tumor with microscopic residual disease
GROUP IIB	Regional disease with involved nodes, completely resected with no microscopic residual disease
GROUP IIC	Regional disease with involved nodes, grossly resected but with evidence of microscopic residual disease and/or histologic involvement of most distal regional node (from the primary site) in the dissection
GROUP III	Incomplete resection with gross residual disease
GROUP IV	Distant metastatic disease present at onset

Table 2: Differential diagnosis of craniofacial rhabdomyosarcomas according to imaging findings [12].

BENIGN	MALIGNANT
PM	PM
Hemangioma/lympangioma	Malignant lymphoma
Juvenile nasopharyngeal angiofibroma	Nasopharyngeal carcinoma
Schwannoma, plexiform neurofibroma	Ewing's sarcoma
Aneurysmal bone cyst	Osteosarcoma, metastatic tumor
Parotid tumor	
NON-PM head and neck	NON-PM head and neck
Reactive lymph nodes	Metastasis(neuroblastoma)
Mucocele, nasal polyp	Chondrosarcoma
Ossifying fibroma	Fibrosarcoma
Teratoma	Synoviosarcoma
Lateral neck cyst	
Ectopic thyroid tissue	
ORBIT	ORBIT
Hemangioma	PNET
Vascular malformation	Ewing's sarcoma
Schwannoma	Metastasis(neuroblastoma)
Optic nerve glioma	Optic nerve glioma
Teratoma	
Demoid cyst	
Lacrimal gland tumor	
Fibrous dysplasia	

PM: Parameningeal

case although preoperative staging was T1N0M0, we grossly resected the tumor with suspicious of microscopic residual disease which makes our patient group IIA according to postsurgical group risk. (Table 1) We preferred adjuvant radiotherapy and chemotherapy for our patient due to this reason. Although there is a great evolution for treatment of head and RMS cases over years [9], there is no globally accepted treatment algorithm for all head and neck RMS cases.

As a conclusion; for children with nonspecific nasal obstruction symptom, nasal cavity and nasopharyngeal RMS must also be

thought in differential diagnosis. Combined modality treatment regimens including surgery, radiotherapy and chemotherapy are the most suitable treatment options for tumors which are not amenable to total excision.

References

1. Mondal PK, Pal I, Misra S, Biswas S, Bera SP. Rhabdomyosarcoma of nose, nasopharynx and paranasal sinuses. Indian J Otolaryngol Head Neck Surg. 2009; 61: 317-319.
2. Hicks J, Flaitz C. Rhabdomyosarcoma of the head and neck in children. Oral Oncol. 2002; 38: 450-459.
3. Holsinger FC, Hafemeister AC, Hicks MJ, Sulek M, Huh WW, Friedman EM. Differential diagnosis of pediatric tumors of the nasal cavity and paranasal sinuses: a 45-year multi-institutional review. Ear Nose Throat J. 2010; 89: 534-540.
4. Lawrence W Jr, Hays DM, Heyn R, Tefft M, Crist W, Beltangady M, et al. Lymphatic metastases with childhood rhabdomyosarcoma. A report from the Intergroup Rhabdomyosarcoma Study. Cancer. 1987; 60: 910-915.
5. Womer RB, Pressey JG. Rhabdomyosarcoma and soft tissue sarcoma in childhood. Curr Opin Oncol. 2000; 12: 337-344.
6. Weber CO. Anatomische Untersuchung einer hypertrophischen Zunge nebst Bemerkungen über die Neubildung quergestreifter Muskelfasern. Virchow Arch PatholAnat 1854; 7: 15.
7. Gerth DJ, Tashiro J, Thaller SR. Pediatric sinonasal tumors in the United States: incidence and outcomes. J Surg Res. 2014; 190: 214-220.
8. Chigurupati R, Alfatooni A, Myall RW, Hawkins D, Oda D. Orofacial rhabdomyosarcoma in neonates and young children: a review of literature and management of four cases. Oral Oncol. 2002; 38: 508-515.
9. Meza JL, Anderson J, Pappo AS, Meyer WH; Children's Oncology Group. Analysis of prognostic factors in patients with nonmetastatic rhabdomyosarcoma treated on Intergroup Rhabdomyosarcoma studies III and IV: The Children's Oncology Group. J ClinOncol. 2006; 24: 3844-3851.
10. Reilly BK, Kim A, Peña MT, Dong TA, Rossi C, Murnick JG, et al. Rhabdomyosarcoma of the head and neck in children: review and update. Int J Pediatr Otorhinolaryngol. 2015; 79: 1477-1483.
11. Daya H, Chan HS, Sirkin W, Forte V. Pediatric rhabdomyosarcoma of the head and neck: is there a place for surgical management? Arch Otolaryngol Head Neck Surg. 2000; 126: 468-472.
12. Freling NJ, Merks JH, Saeed P, Balm AJ, Bras J, Pieters BR, et al. Imaging findings in craniofacial childhood rhabdomyosarcoma. Pediatr Radiol. 2010; 40: 1723-1738.