

Case Report

Primary Right Atrial Leiomyosarcoma

Sabzi F* and Ghasemi F

Preventive Cardiovascular Research Centre Kermanshah, Kermanshah University of Medical Sciences, Iran

*Corresponding author: Feridoun Sabzi, Preventive Cardiovascular Research Centre Kermanshah, Kermanshah University of Medical Sciences, Kermanshah, Iran

Received: June 21, 2015; Accepted: September 07, 2015; Published: September 11, 2015

Abstract

Right atrial leiomyosarcoma is a rare neoplasm and its diagnosis is a difficult challenge. The reported case was a 45-year-old man, that presenting with dyspnea, weight loss, fatigue and transthoracic echocardiography revealed an irregular mass in right atrium. The patient underwent open cardiac surgery and right atrial mass that extended to opening of superior vena cava was resected and right atrium constructed by fresh pericardial patch. In the preoperative examination, distant organ metastasis was not detected by computed tomography. On histopathological examination, the resected mass was a leiomyosarcoma. Because of later pulmonary involvement, further management was symptomatic and; the subject expired 8 months following beginning of his first symptom regarding to his problems. The further histochemical exam confirmed that the mass was a leiomyosarcoma. Rarity, unusual presentation, diagnosing and treating is discussed.

Keywords: Cardiac leiomyosarcoma; Right atrial origin; Open heart surgery

Introduction

The incidence of primary cardiac tumor in necropsy series is as low as 0.0016% to 0.3%. These neoplasms are 40-60 time rarer than metastatic tumor. Seventy five percent of all primary cardiac tumors have a benign nature and 25% of remainder is malignant. The angiosarcoma, liposarcoma, fibrosarcomas rhabdomyosarcomas, chondrosarcoma and osteosarcomas are most common cardiac sarcoma with their special histology and early invasiveness [1]. Most of these malignant neoplasms have not been related to gender, or familial history but most of them has been occurred in the 4th or 5th decades of life. The most common site of sarcoma origin in cardiac structures is in the superior vena cava (SVC), left atrium, the right atrium, the right ventricle, left ventricle and in the aorto-mitral fibrous continuity subsequently. Clinical presentation of heart sarcomas is related to their location, differentiation and rate of progression of the neoplasm. The main clinical manifestation of sarcomas are heart failure, pulmonary symptoms such cough, hemoptysis, chest wall pain, and pericardial effusion. Sometimes sarcoma presenting with

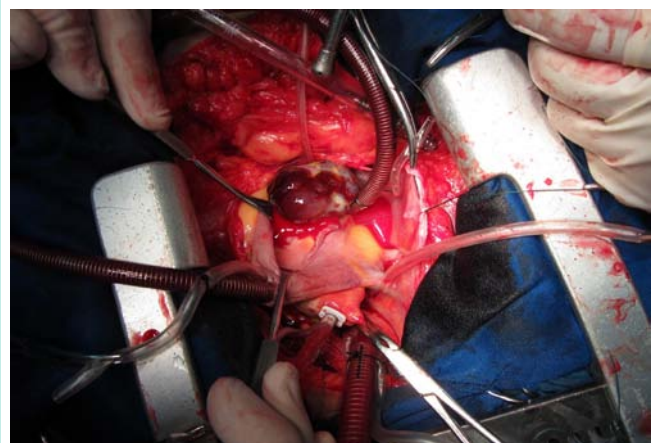


Figure 2: Shows intra operative view of right atrial tumor.

cardiac tamponade, arrhythmias, conduction defects, obstruction of the cardiac chamber or sudden death. Tumors developing in the myocardium are clinically silent. When sarcomas invade the cardiac cavities and pericardium, 75% of the patients develop distant metastases, most frequently to the lung parenchyma, thoracic lymph nodes, mediastinum and skeletal system [2]. However none of the clinical symptoms is typical of cardiac sarcoma, but, the patient rarely remains asymptomatic. The main imaging modalities are transthoracic (TTE) and transesophageal echocardiography (TEE), that may be complemented by computed tomography (CT) and magnetic resonance imaging. Cardiac angiography is needed before cardiac surgery for good visualization of the tumor blush and cardiac chambers or rule out of coronary artery disease [3]. The outcome is generally poor and the survival time is reported to be from several weeks to two years [4].

Case Presentation

A 45 year old patient was hospitalized with a two month history of progressive fatigue, dyspnea, weight loss, chest wall pain, productive

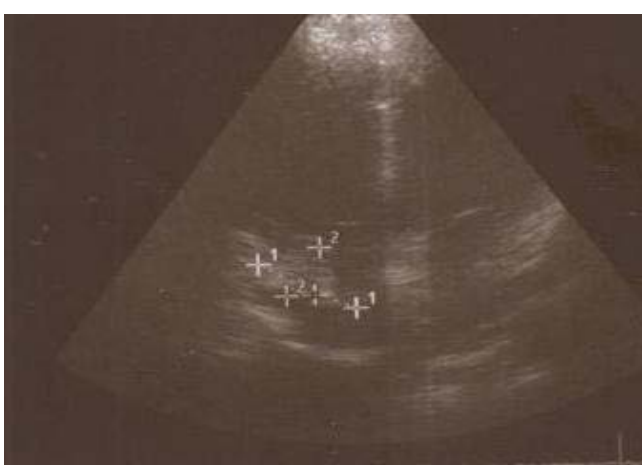

Figure 1: Shows right atrial mass.

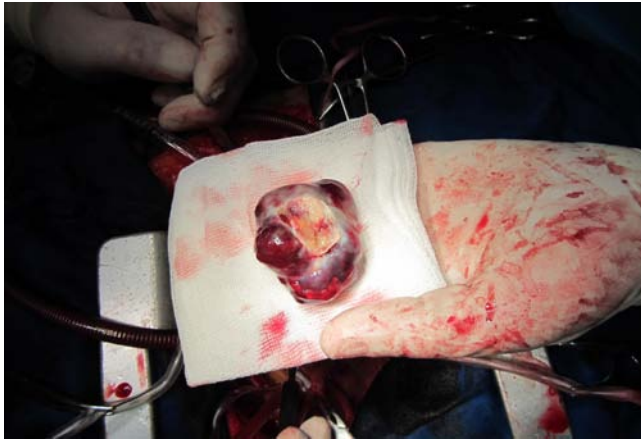


Figure 3: Shows gross pathology of resected mass.

cough, malaise, and night diaphoresis. Physical examination showed pallor, lower extremity pitting edema, normal sinus rhythm with tachycardia of 115 beats per minute, hypotension (90/50 mm Hg). There was not any evidence of paradoxical pulse, engorged jugular veins, or tricuspid insufficiency murmur. The lung exam showed fine crackles in the lower lung zones. In abdominal examination ascitis, organomegaly or abdominal mass were not detected. TEE revealed a large sessile mass in the right atrium without invasion into the tricuspid valve or both vena cava (Figure 1). Coronary angiography showed normal coronary arteries without evidence of stenosis or tumor blush or leash of collateral arteries. The patient underwent open cardiac surgery with midline sternotomy and aortic and bi-caval cannulation. At operation, following pericardiotomy no evidence of bloody pericardial effusion or exfoliated invasive mass to pericardial cavity was detected. The tumor was found as an encapsulated mass attached to interatrial septum. The atrial wall along with some part of proximal SVC was resected and repaired by the fresh pericardium (Figure 2,3). The section areas consisted of un-differentiated zone having a partial fascicular growth appearance but also of region with a less reticular pattern. High cellularity, areas were also observed. The tumor cell nuclei had partial elongated shape with some degree of pleomorphism (Figure 4). Immunohistochemical staining revealed positive areas for alpha-smooth-muscle actin and desmin. Histopathological and histochemical staining showed the mass to be a leiomyosarcoma. One month after surgery he treated with 4 cycles of combination chemotherapy and his surveillance was checked with total body scan imaging. After 6 months the patient admitted with dyspnea but TEE showed no evidence of tumor recurrence in cardiac cavity. Abdominal ultrasound evaluation showed also no evidence of tumor spreading into the liver however computed tomography (C-T) scan and chest X-ray showed para tracheal lymph nodes involvement with spreading to lung parenchyma. The patient died in 8th months of operation with clinical picture of respiratory failure.

Discussion

The primary cardiac sarcomas usually occur in the subjects in four or five decade of life and most of them are less than 55 years old. In most of case series or case reports of sarcoma study there was not any gender tendency in the occurrence of sarcoma but in one study a slight male predominance was detected. The surgical

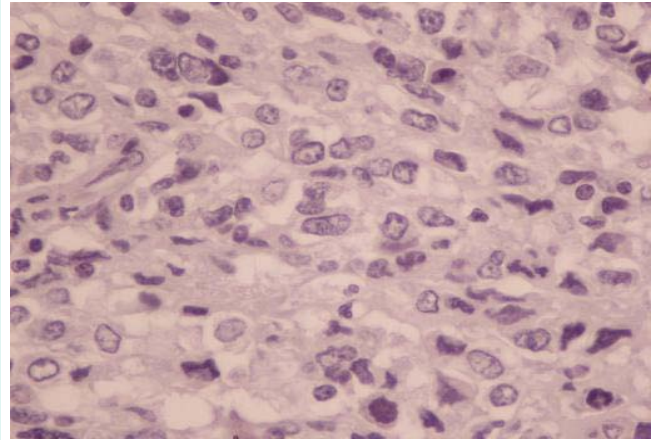


Figure 4: Epithelioid smooth muscle cells with cytoplasmic glycogen, blunted nuclei with moderate/marked pleomorphism, mitotic activity occasionally giant cells, and perinuclear vacuoles.

approach is recommended as the main definitive therapy of the cardiac sarcoma that usually are associated with infiltration of cardiac cavity or invasion to surrounding structures and for reducing risk of systemic or pulmonary emboli. In some cases with presence of distant metastasis, surgery is also considered as an effective method for palliation [5]. This concept has been obtained in review of subjects that despite of tumor stage, the most of patients have been scheduled for palliative resection. Indeed, in more than 70% of cases with localized intracardiac sarcoma and in the 70% of patients with extra cardiac spreading, surgery was performed for palliation [6]. Interestingly, in 41% of the subjects with local spreading or distant metastasis, surgery also considered for relief of obstructive effect of mass in cardiac chamber. All of previous studies also confirm the likely present trend toward the palliative removal of cardiac sarcoma [7]. In opposed to others soft tissue sarcoma, cardiac sarcomas tends to be diagnosed at higher stage and when loco-regional spreading or distant metastasis has been occurred. Leiomyosarcoma represent less than 10% of all cardiac sarcoma cases, while comprising less than 1% of others soft tissue sarcomas. The mean overall survival of the sarcoma patients is 12 months [8]. Bakaeen and colleagues exhibited an amazing, two year survival rate of 60% in 30 cases of primary cardiac sarcoma who

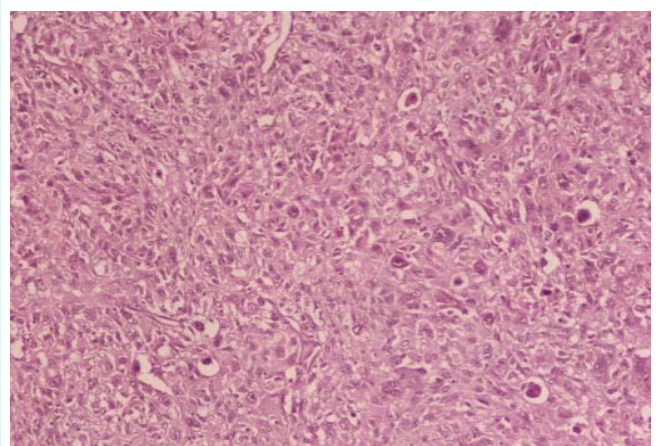


Figure 5: Hematoxylin-eosin staining of histological section of the tumor.

treated with aggressive combined surgery and chemotherapy. Tumor grade was also considered as an important factor that is associated with poor survival in the subjects with cardiac sarcoma [9]. This study was in opposed to the Burke et al. study. Authors found that survival of cardiac sarcoma was not related to the grade or differentiation of tumor [10]. Bakaeen et al. have recommended an aggressive surgical intervention in the patients with any grade of tumor with or without presence of metastasis. The author also recommends a multimodality therapy composing of surgical removal, with adjuvant combined chemotherapy and radiation therapy [9]. In study of Llombart-Cussac et al. in follow-up of 15 cardiac sarcoma patients, which managed with combined adjuvant chemotherapy, an average survival rate of 1 year has been confirmed. The chemotherapy regimen was started within two months of surgery. Future studies of new combinations therapy such as transplantation with adjuvant chemotherapy with or without radiotherapy could be reiterated these poorer outcome results [11].

References

- Boey S, Tribouilloy C, Lesbre JP, Stankowiak C, Copin MC, Haffreingue E, et al. [Surgical treatment of leiomyosarcoma of the left atrium Report of a case and review of the literature]. *Arch Mal Coeur Vaiss.* 1994; 87: 291-294.
- Zhang PJ, Brooks JS, Goldblum JR, Yoder B, Seethala R, Pawel B, et al. Primary cardiac sarcomas: a clinicopathologic analysis of a series with follow-up information in 17 patients and emphasis on long-term survival. *Hum Pathol.* 2008; 39: 1385-1395.
- Winther C, Timmermans-Wielenga V, Daugaard S, Mortensen SA, Sander K, Andersen CB. Primary cardiac tumors: a clinicopathologic evaluation of four cases. *Cardiovasc Pathol.* 2011; 20: 63-67.
- Kim CH, Dancer JY, Coffey D, Zhai QJ, Reardon M, Ayala AG, et al. Clinicopathologic study of 24 patients with primary cardiac sarcomas: a 10-year single institution experience. *Hum Pathol.* 2008; 39: 933-938.
- Mayer F, Aebert H, Rudert M, Königsrainer A, Horger M, Kanz L, et al. Primary malignant sarcomas of the heart and great vessels in adult patients- a single-center experience. *Oncologist.* 2007; 12: 1134-1142.
- Kim JD, Kim JS, Hwang TS, Shin JK, Song MG. Surgical management of recurrent leiomyosarcoma in heart. *Korean J Thorac Cardiovasc Surg.* 2014; 47: 35-38.
- Andersen RE, Kristensen BW, Gill S. Cardiac leiomyosarcoma, a case report. *Int J Clin Exp Pathol.* 2013; 6: 1197-1199.
- Nakanishi H, Furukawa K, Noguchi R, Furutachi A, Itoh M, Kamohara K, et al. [Primary cardiac leiomyosarcoma originating from the left atrium]. *Kyobu Geka.* 2012; 65: 1057-1061.
- Bakaeen FG, Jaroszewski DE, Rice DC, Walsh GL, Vaporciyan AA, Swisher SS, et al. Outcomes after surgical resection of cardiac sarcoma in the multimodality treatment era. *J Thorac Cardiovasc Surg.* 2009; 137: 1454-1460.
- Burke AP, Cowan D, Virmani R. Primary sarcomas of the heart. *Cancer.* 1992; 69: 387-395.
- Llombart-Cussac A, Pivot X, Contesso G, Rhor-Alvarado A, Delord JP, Spielmann M, et al. Adjuvant chemotherapy for primary cardiac sarcomas: the IGR experience. *Br J Cancer.* 1998; 78: 1624-1628.