

## Case Report

# Management of Temporomandibular Joint Dislocation in a Bisphosphonate-Medicated Patient

Gokhan Ozkan<sup>1\*</sup>, Umut Demetoglu<sup>2</sup>, Hasan Onur Simsek<sup>2</sup> and Goknil Alkan Demetoglu<sup>3</sup>

<sup>1</sup>Adnan Menderes University, Department of Oral and Maxillofacial Radiology, Turkey

<sup>2</sup>Adnan Menderes University, Department of Oral and Maxillofacial Surgery, Turkey

<sup>3</sup>Adnan Menderes University, Department of Prosthetics, Turkey

\*Corresponding author: Gokhan Ozkan, Adnan Menderes University, Faculty of Dentistry, Department of Oral and Maxillofacial Radiology, Aydin, Turkey

Received: August 05, 2016; Accepted: September 19, 2016; Published: September 21, 2016

## Abstract

The purpose is to evaluate the treatment outcomes for a 75-year-old female patient with unilateral chronic mandibular condylar dislocation and during the past two years has received on oral bisphosphonate. In the present study, eminectomy was performed on a patient who had been receiving zoledronic acid (a bisphosphonate) for osteoporosis. On the follow-up examinations, there were no clinical and radiological signs associated with medication-related osteonecrosis of the jaws. Although this treatment protocol was successful in this single case, further studies are required to validate the application of this treatment protocol.

**Keywords:** Temporomandibular joint; Mandibular condyle; Dislocation; Bisphosphonate; Eminectomy

## Introduction

The management of dislocated mandible is a substantial issue in medicine and dentistry [1]. Dislocation is a Temporomandibular Joint (TMJ) disorder and can be classified into 3 categories: acute, chronic, or chronic recurrent [2,3]. Chronic recurrent mandibular dislocation is rarely seen and can present due to various etiologies such as general joint laxity, internal derangement of the TMJ, occlusal disturbances in accordance with tooth loss, alterations in vertical height, and neurologic diseases [1,4].

Conservative treatments; physiotherapy, prosthetic restoration of vertical height, and immobilization of the jaw in the closed position are management options for TMJ dislocation.

Surgical management is proposed when conservative treatment methods fail. Eminectomy is one of the preferred and considered effective technique for the management of chronic recurrent TMJ dislocation [1,3,5,6].

However, to date, there are no studies that mention eminectomy in association with TMJ dislocation in patients who are being treated with Bisphosphonates (BPs) for osteoporosis. BPs is synthetic analogs of pyrophosphates. These medications inhibit osteoclasts, reduce bone metabolism, and are potent inhibitors of osteoclastic bone resorption that are used to control malignancy-related hypercalcemia, multiple myeloma, fibrous dysplasia, metastatic bone tumors, osteoporosis, and Paget's disease of the bone [5,7]. Medication-related osteonecrosis frequently develops in the posterior mandible, followed by the maxilla and both jaws [5]. Many articles on Medication-Related Osteonecrosis of Jaws (MRONJ) have been published in the literature, but reports of TMJ in association with bisphosphonate treatment are inadequate [8-10].

To the best of our knowledge, this is the first case report to describe the long-term follow-up results of an eminectomy that was performed on a patient who was being administered. The purpose is to evaluate the treatment outcomes for a 75-year-old female patient with unilateral chronic mandibular condylar dislocation and during

the past two years has received on oral bisphosphonate.

## Case Presentation

A 75-year-old female patient was referred to our clinic due to severe unilateral TMJ pain, mandibular dislocation, and inability to chew. The patient had experienced mandibular dislocation many times for 2 years. At all times, a dental practitioner helped the patient set the mandibular condyle into position. In addition, the patient had been receiving oral zoledronic acid (a BP) for 2 years as a treatment for osteoporosis. An intraoral examination revealed the unilateral deviation of the mandible to the right side when opening the mouth. The frontal position of the left condyle and deviation to the right side of the mandible could easily be seen on the clinical evaluation. On the TMJ images, there was no evidence of any destruction in the mandibular condyle and glenoid fossa (Figure 1).

After seating the mandibular condyle into the fossa, effective maxillomandibular fixation could not be achieved due to the lack of a sufficient number of teeth. Consequently, a barrel bandage was used to stabilize the mandible.

The next day, the patient visited the clinic again due to repeat mandibular dislocation. After considering the patient's previous experiences, an eminectomy was planned and detailed information was provided to the patient about the procedure. After the patient consented to the treatment approach, Cone Beam Computed

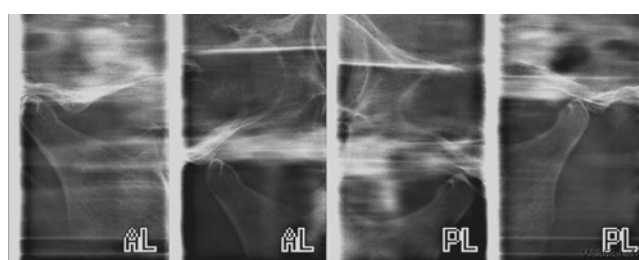
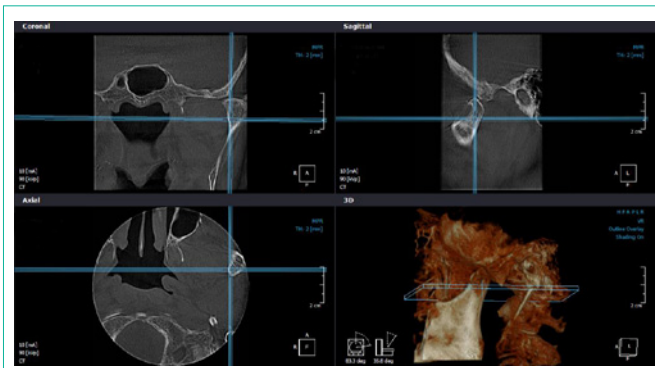


Figure 1: TMJ images showing the dislocated condyle at the left side.



**Figure 2:** Detailed visualization of TMJ on CBCT.

Tomography (CBCT) images were obtained for detailed planning purposes (Figure 2). However, Magnetic Resonance Imaging (MRI) could be helpful in defining the presenting pathology and most ideal treatment option [11], it was not achieved due to claustrophobia of the patient.

The risk of BP-related osteonecrosis of the jaw was considered and 1 g amoxicillin and clavulanic acids were preoperatively administered twice per day for 1 week. During surgery, a 1 g intravenous antibiotic was intraoperatively administered. A preauricular lateral incision that reached the eminentia and condyle was performed under general anesthesia. Then, the eminentia was shaved under saline irrigation and flattened with the help of osteotomes. The mandibular movements were checked after the eminentectomy, and no mandibular dislocation was detected throughout the process.

Following surgery, the antibiotic regimen (1 g amoxicillin and clavulanic acid) was administered twice per day for 2 weeks because of the risk of infection and osteonecrosis.

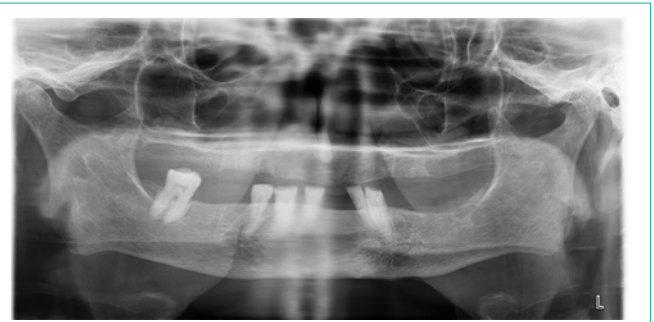## Results

After 1 week, at the first follow-up examination, pain relief and mouth opening without dislocation was achieved. The patient had mild edema and slight pain while chewing. There were no signs of infection. The flattening of the eminentia articularis was seen on a panoramic radiograph. Postoperative follow-up examinations (3-6 months later) were uneventful. There was no pain during mastication, and no edema was observed. At the 1-year follow-up examination, there was no resorption or bone defect around the mandibular condyle and the operated eminentia was absent on the panoramic radiograph (Figure 3). Also, there were no clinical indicators associated with MRONJ. Follow up continued for 16 months.

## Discussion

Research on the effects of antiresorptive drugs, such as BPs, on trabecular architecture has increased in recent years. BPs inhibits osteoclastic activity and change the osteoblast-osteoclast balance. Due to this effect, BPs reduces bone resorption and increase bone formation [12]. Therefore, BPs are widely used to treat postmenopausal osteoporosis and malignancies that lead to hypercalcemia [13,14].

Several side effects have been reported as related to BPs, particularly in the jaws, since increased osteoblastic and osteoclastic activities occur in this region [15]. This increase in activity may cause



**Figure 3:** Panoramic image of the patient at 12 months following the procedure.

the excessive deposition of BPs in these regions. Bone remodeling is also crucial for TMJ structures, and therefore adverse effects might occur in this area. Marks reported the first paper on osteonecrosis of the jaws in patients using BPs [16]. On the other hand, there are only a few reports that mention MRONJ of the TMJ [8-10]. Hammarfjord et al. reported a case report on bilateral TMJ ankylosis that was related to BPs and claimed that altered bone remodeling caused this kind of aberration [10]. In addition, a case of unilateral suppurative arthritis of the TMJ was reported by Enomoto et al. [8]. The patient was medicated with BPs (zoledronate) to treat prostate cancer. There was no history of TMJ trauma or any invasive dental treatments, and the authors associated the arthritis with BPs. Another case report presented a femoral fracture on both sides of the hip and TMJ destruction following the use of BPs [9]. The patient had received osteoporosis prophylaxis with alendronate for the past 14 years. The authors declared that these fractures may have occurred as a result of a deficiency in the bone-repair process. The joint surface defects healed by 3.5 years after stopping alendronate medication.

According to a study by Tatli et al. [17] administering a single dose of zoledronic acid to the condyle can lead to increases in bone mineralization. A limited number of studies state that BPs may result in some alterations in the TMJ region. We suggested surgical intervention as the best course of action since the frequency of dislocation significantly decreased the quality of life of our patient, although there was a potential risk of MRONJ. Following minimal traumatic surgical intervention under antibiotic prophylaxis, our patient has not had an MRONJ experience for 16 months.

## Conclusion

There are few case reports and experimental studies that investigate the influence of BPs on the TMJ region. Further research studies are needed to help guide clinicians regarding the appropriate surgical approaches to apply to the maxillofacial region in patients receiving BP therapies. Although this treatment protocol was successful in this single case, further studies are required to validate the application of this treatment protocol.

## References

1. Undt G. Temporomandibular joint eminentectomy for recurrent dislocation. *Atlas Oral Maxillofac Surg Clin North Am.* 2011; 19: 189-206.
2. Adekeye EO, Shamia RI, Cove P. Inverted L-shaped ramus osteotomy for prolonged bilateral dislocation of the temporomandibular joint. *Oral Surg Oral Med Oral Pathol.* 1976; 41: 568-577.

3. Rowe PF, Caldwell JB. Correction of permanent temporomandibular joint dislocation. *J Oral Surg.* 1970; 28: 222-226.
4. de Almeida VL, Vitorino Nde S, Nascimento AL, da Silva Júnior DC, de Freitas PH. Stability of treatments for recurrent temporomandibular joint luxation: a systematic review. *Int J Oral Maxillofac Surg.* 2016; 45: 304-307.
5. Lee L. Inflammatory lesions of the jaws. White SC, Pharoah MJ, editors. In: *Oral Radiology Principles and Interpretation.* St. Louis: Mosby. 2009; 341.
6. de Freitas Silva L, Ribeiro NR, Faverani LP, Gondim RF, Maia RN. Treatment of Chronic Recurrent Temporomandibular Joint Dislocation. *J Craniofac Surg.* 2016; 27: 815.
7. Hubner RA, Houston SJ. Bisphosphonates' use in metastatic bone disease. *Hosp Med.* 2005; 66: 414-419.
8. Enomoto A, Uchihashi T, Izumoto T, Nakahara H, Hamada S. Suppurative arthritis of the temporomandibular joint associated with bisphosphonate: a case report. *J Oral Maxillofac Surg.* 2012; 70: 1376-1379.
9. Skoglund K, Hjortdal O. Femoral fracture and temporomandibular joint destruction following the use of bisphosphonates. *Tidsskr Nor Laegeforen.* 2015; 135: 116-117.
10. Hammarfjord O, Stassen LF. Bisphosphonate therapy and ankylosis of the temporomandibular joint: is there a relationship? A case report. *Oral Surg Oral Med Oral Pathol Oral Radiol.* 2014; 118: 68-70.
11. Vogl TJ, Lauer HC, Lehnert T, Naguib NN, Ottl P, Filmann N, et al. The value of MRI in patients with temporomandibular joint dysfunction: Correlation of MRI and clinical findings. *Eur J Radiol.* 2016; 85: 714-719.
12. Maruotti N, Corrado A, Neve A, Cantatore FP. Bisphosphonates: effects on osteoblast. *Eur J Clin Pharmacol.* 2012; 68: 1013-1018.
13. Walsh JP, Ward LC, Stewart GO, Will RK, Criddle RA, Prince RL, et al. A randomized clinical trial comparing oral alendronate and intravenous pamidronate for the treatment of Paget's disease of bone. *Bone.* 2004; 34: 747-754.
14. Bone HG, Hosking D, Devogelaer JP, Tucci JR, Emkey RD, Tonino RP, et al. Alendronate Phase III Osteoporosis Treatment Study Group. Ten years' experience with alendronate for osteoporosis in postmenopausal women. *N Engl J Med.* 2004; 350: 1189-1199.
15. Marx RE, Sawatari Y, Fortin M, Broumand V. Bisphosphonate-induced exposed bone (osteonecrosis/osteopetrosis) of the jaws: risk factors, recognition, prevention, and treatment. *J Oral Maxillofac Surg.* 2005; 63: 1567-1575.
16. Marx RE. Pamidronate (Aredia) and zoledronate (Zometa) induced avascular necrosis of the jaws: a growing epidemic. *J Oral Maxillofac Surg.* 2003; 61: 1115-1117.
17. Tatli U, Ustün Y, Kürkçü M, Benlidayı ME. Effects of zoledronic acid on physiologic bone remodeling of condylar part of TMJ: a radiologic and histomorphometric examination in rabbits. *ScientificWorld Journal.* 2014.