

Case Report

Tuberculous Granuloma of the Brain

Moawia Gameraddin* and Sultan Alshoabi

Department of Diagnostic Radiologic Technology, Taibah University, Saudi Arabia

*Corresponding author: Moawia Gameraddin, Department of Radiology, Taibah University, Faculty of Applied Medical Sciences, Saudi Arabia

Received: June 19, 2016; Accepted: June 29, 2016;

Published: July 02, 2016

Abstract

Tuberculous granuloma of the brain is a bacterial infection involved the brain that causes severe morbidity and mortality. The patient in this case presented with repeated attacks of seizures, fever, intermittent loss of conscious and signs of increased intracranial pressure since several months. This case was firstly diagnosed as Glioblastoma Multiform (GBM), but there was a focal calcification inside the lesion that lead the specialist to suspect tuberculosis. The patient was referred to MRI that revealed a low signal intensity lesion with severe edema in the right cerebral hemisphere which mainly involved the frontal, parietal and temporal lobes of the right cerebral hemisphere. After contrast administration, the lesion showed gyral enhancement of the cortical parts of the lesion that is strongly suggesting tuberculous infection. The histopathology confirmed the diagnosis of tuberculous granuloma. The MRI with contrast remains an important imaging modality to assess the tuberculous infection of the brain.

Keywords: Tuberculous; Granuloma; Brain

Introduction

Tuberculosis is a bacterial infection and remains a main cause of morbidity and mortality in the developing world. There was approximately 1/6th of the 3 million of mortality in the world due to infection of Mycobacterium tuberculosis. Infection of Central Nervous System (CNS) was approximately occurring in 2-5% of patients with tuberculosis and up to 15% of those with AIDS-related tuberculosis. In endemic regions, tuberculomas were found to be as many as 50% of all intracranial masses. This infection affect all age groups with approximately 60-70 % of cases found in patients lesser than 20 years old [1-3].

Tuberculosis of the brain can result from hematogenous spread of Mycobacterium Tuberculosis from a distant infection as pulmonary tuberculosis or gastrointestinal tract or from direct extension from local infection at a nearby area to the brain as tuberculous mastoiditis. Tuberculous brain infection can occur by a wide spectrum of manifestations as tuberculous meningitis and tuberculous granuloma of the brain. Tuberculous meningitis is involving commonly the leptomeninges particularly at the base of the brain and commonly complicating by obstructive hydrocephalus but rarely involving the pachymeninges [4].

Diagnosis of Tuberculous meningitis is not easy since other sorts of bacterial meningitis does not present with the classic signs of bacterial meningitis as fever, projectile vomiting and seizures. Tuberculous meningitis usually begins with non-specific symptoms of night fever, headache and feeling unwell for weeks then worse symptoms start as vomiting, neck stiffness and seizures occur. Diagnosis of Tuberculosis can't be made or excluded on clinical features. The gold standard for diagnosis of central nervous system tuberculosis is dependent on lumbar puncture and Cerebrospinal Fluid (CSF) culture to search for acid fast bacilli [5]. Results of CSF Polymerase Chain Reaction (PCR) assays may provide accurate diagnosis [6-8]. However, imaging modalities provide significant findings in diagnosis of extra pulmonary tuberculosis [10].

Intracerebral tuberculomas may be solitary or multiple and usually occurs near the base of the skull and may occur without associated tuberculous meningitis. The granulomatous focus of the brain usually starts as a focal cerebritis that progress to a non-caseating granuloma that appears as isodense to slight hypodense on CT with surrounding hypodenseoedema and isointense to slight hypointense on T1 weighted images of MRI and hyperintense on T2 weighted images of MRI. The lesion reveals dense nodular enhancement but after caseation occurs, the lesion appears as ring-enhancing lesion after contrast administration on both CT-scan and MRI that is an important differential diagnosis with brain abscess, neurocysticercosis, fungal infections, glioma, lymphoma and metastasis [11].

Case Report

A 28 years slim old male patient referred to Al-Thawra Hospital Sana in Yemen, presented with repeated attacks of seizures, fever, intermittent loss of conscious and signs of increased intracranial pressure since several months. He underwent CT brain which

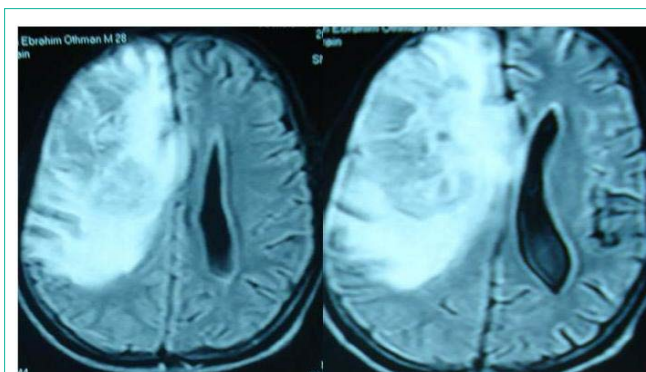


Figure 1: MRI FLAIR waited-image of 28 year patient showed high signal intensity lesion at frontal and parietal lobe in the right cerebral hemisphere causing mass effect manifesting as compression of the right lateral ventricle and mild shifting of the midline to the contralateral side.

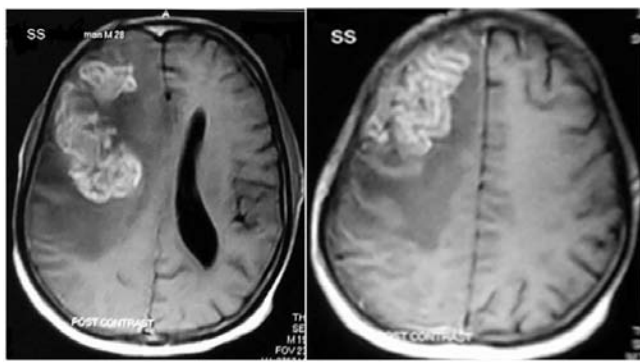


Figure 2: MRI T1 waited-image with contrast of a 28 year patient showed edema at the frontal and parietal lobe of the right cerebral hemisphere manifested as compression of the right lateral ventricle and mild deviation of the midline to the contra lateral side with gyral type of enhancement of the lesion after contrast administration that consistent with tuberculoma.

revealed edema in the right cerebral hemisphere with mass effect grade-2 that appear as effacement of the brain sulci and compression of the right lateral ventricle. This case was firstly diagnosed as Glioblastomamultiform (GBM) but there were focal calcifications inside the lesion that lead the specialist to suspect Tuberculosis (TB). Then the patient was referred to do MRI of the brain that revealed a mass with severe edema in the right cerebral hemisphere which mainly involved the frontal, parietal and temporal lobes of the right cerebral hemisphere.

After contrast administration, the lesion showed gyral enhancement of the cortical parts of the lesion that is strongly suggesting tuberculous infection. Then the patient was referred to neurosurgery for biopsy. The histopathology examination confirmed the diagnosis of Tuberculous granuloma and consistent with the MRI finding.

Discussion

Tuberculosis (TB) of the Central Nervous System (CNS) is a granulomatous infection caused by *Mycobacterium tuberculosis*. This infection involves the brain and meninges and it is difficult to be clinically diagnosed. So, imaging modalities plays a central role to establish the diagnosis. There were challenges to report the final diagnosis since several brain lesions reveal similar appearance such as abscess, gliomas, metastasis, histoplamosis and cysticercosis.

The imaging modalities have a major role in diagnosis of central nervous system tuberculosis. Magnetic Resonance Imaging (MRI) with gadolinium enhancement is the preferred imaging modality of initial examination and assessment [12,13]. The appearance of tuberous granuloma on MRI is variable from T1-weighted to T2-weighted images. On T1-weighted images, it appears isointense to grey matter and may have central region with high signal representing caseation [14]. In this case, the granulomas appear as a ring-enhancing lesion on T1-weighted image after contrast administration with significant surrounding edema (Figure 1&2).

Differential diagnosis remains a challenge to differentiate granuloma form other brain lesions such as abscesses, metastases, cerebral toxoplasmosis, neurocysticercosis and cryptococcosis. But the appearance of central isointensity or low signal compared to grey matter which visualized centrally on T2-weighted is a useful characteristic that it is not present in most other lesions [14].

Conclusion

We have reported a case of tuberculous granuloma that involved the parietal and frontal lobes of the brain which was detected by MRI. But MRI with contrast is nearly the most useful imaging modality for depicting features, including edema and gyral enhancement, but CT is better to detect calcifications. These imaging modalities play a major role in preoperative decisions and management.

References

- Burrill J, Williams CJ, Bain G, Conder G, Hine AL, Misra RR. Tuberculosis: a radiologic review. *Radiographics*. 2007; 27: 1255-1273.
- Kornienko VN, Pronin IN. *Diagnostic Neuroradiology*. Springer Verlag. 2009.
- Gupta RK, Lufkin RB. *MR imaging and spectroscopy of central nervous system infection*. Springer Us. 2001.
- Leonard JM, Des Prez RM. Tuberculous meningitis. *Infect Dis Clin North Am*. 1990; 4: 769-787.
- Thwaites G, Chau TT, Mai NT, Drobniewski F, McAdam K, Farrar J. Tuberculous meningitis. *J Neurol Neurosurg Psychiatry*. 2000; 68: 289-299.
- Sangani SV, Parikh S. Can sonographic measurement of optic nerve sheath diameter be used to detect raised intracranial pressure in patients with tuberculous meningitis? A prospective observational study. *Indian J Radiol Imaging*. 2015; 25: 173-176.
- Sanei Taheri M, Karimi MA, Haghighatkah H, Pourghorban R, Samadian M, Delavar Kasmaei H. Central nervous system tuberculosis: an imaging-focused review of a reemerging disease. *Radiol Res Pract*. 2015; 202806.
- Shih RY, Koeller KK. Bacterial, Fungal, and Parasitic Infections of the Central Nervous System: Radiologic-Pathologic Correlation and Historical Perspectives. *Radiographics*. 2015; 35: 1141-1169.
- Torres C, Riascos R, Figueroa R, Gupta RK. Central nervous system tuberculosis. *Top Magn Reson Imaging*. 2014; 23: 173-189.
- Engin G, Acunas B, Acunas G, Tunaci M. Imaging of extrapulmonary tuberculosis. *Radiographics*. 2000; 20: 471-488.
- Sutton D, Robinson PJA, Jenkins JPR, Whitehouse RW, Allan PL, Wilde P, et al. *Textbook of Radiology and Imaging*. 7th edition. 2003.
- Thirunavukarasu SC, Ramachandrapa A. A rare case of intramedullary tuberculoma: Complete resolution after medical treatment and role of magnetic resonance imaging in diagnosis and follow-up. *Asian J Neurosurg*. 2012; 7: 223-226.
- Sankhe S, Baheti A, Ihare A, Mathur S, Dabhade P, Sarode A. Perfusion magnetic resonance imaging characteristics of intracerebral tuberculomas and its role in differentiating tuberculomas from metastases. *Acta Radiol*. 2013; 54: 307-312.
- Kim TK, Chang KH, Kim CJ, Goo JM, Kook MC, Han MH. Intracranial tuberculoma: comparison of MR with pathologic findings. *AJNR Am J Neuroradiol*. 1995; 16: 1903-1908.