

## Case Series

# Ultrasound Diagnosis of Crystal Jelly Ball Ingestion Causing Intestinal Obstruction

Faizah MZ<sup>1\*</sup>, Soon YY<sup>1</sup>, Che Zubaidah CD<sup>2</sup>, Mohd Yusof A<sup>3</sup> and Dayang AA<sup>4</sup>

<sup>1</sup>Department of Radiology, Universiti Kebangsaan Malaysia Medical Center, Malaysia

<sup>2</sup>Department of Diagnostic Imaging, General Hospital of Kuala Lumpur, Malaysia

<sup>3</sup>Department of Pediatric Surgery, General Hospital of Kuala Lumpur, Malaysia

<sup>4</sup>Department of Surgery, Universiti Kebangsaan Malaysia Medical Center, Malaysia

\*Corresponding author: Faizah MZ, Department of Radiology, Universiti Kebangsaan Malaysia Medical Center, Jalan Yaacob Latiff, 56000 Cheras, Kuala Lumpur, Malaysia

Received: January 18, 2016; Accepted: February 23, 2016; Published: February 24, 2016

## Introduction

Foreign Body (FB) ingestion can cause serious morbidity and mortality, especially among children aged six months to three years [1,2]. Unfortunately, almost half of these cases are not witnessed and often the child does not develop symptoms until presented with complications [3]. There is very little discussion in the literature regarding ultrasound appearance of a radiolucent intraluminal FB such as a crystal jelly ball. Previous literature did not describe the ultrasound findings but the radiograph and CT findings instead of this unique FB ingestion [4]. We aim to present a case series of crystal jelly ball ingestion emphasizing on the ultrasound findings. Ultrasound is a preferred imaging modality in children as it is readily available and no radiation involved. There was no history of FB ingestion prior to the pre-operative ultrasound in both cases.

## Case Series

### Case 1

An 18 month old girl presented with a history of two days of vomiting with poor oral intake. There was no associated fever or diarrhoea. Upon examination, she was dehydrated and lethargic. Her abdomen was still soft, non-tender and not distended. She was admitted and treated for acute gastroenteritis. The following day, she developed bilious vomiting.

Abdominal ultrasound using a L12-5 MHz superficial probe Philips IU22 ultrasound (Eindhoven, The Netherlands) demonstrated a well-defined anechoic thin-walled, intraluminal cystic lesion. The lesion was suspected to be in the splenic flexure as it was located at left hypochondrium with presence of dilated right sided colon. The provisional diagnosis was an enteric duplication cyst since there was a “double wall sign” noted (Figure 1).

A lower gastrointestinal study was performed due to the suspicion of an intracolonic lesion. The results showed opacification of the

### Abstract

Ingestion of Foreign Bodies (FB) by young children is a common presentation in the emergency department. We present two cases which were diagnosed with intestinal obstruction. Abdominal ultrasound revealed an intraluminal anechoic cystic lesion causing intestinal obstruction in both cases. We discuss the ultrasound findings of an intraluminal crystal jelly ball FB highlighting the technical consideration on ultrasound probe selection. In both cases, Intraoperative findings confirmed that the small bowel obstruction was due to a crystal jelly ball bezoar.

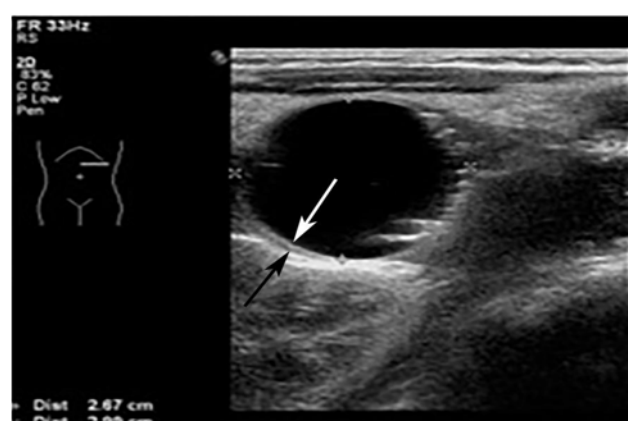
**Keywords:** Ultrasound; Jelly ball; Intestinal obstruction

descending colon up to the splenic flexure with sudden tapering. However, since there was no evidence of “claw sign” to suggest intussusception with no describable features on earlier ultrasound, the impression was that the intraluminal cystic lesion was in the small bowel and has caused compression to the adjacent splenic flexure.

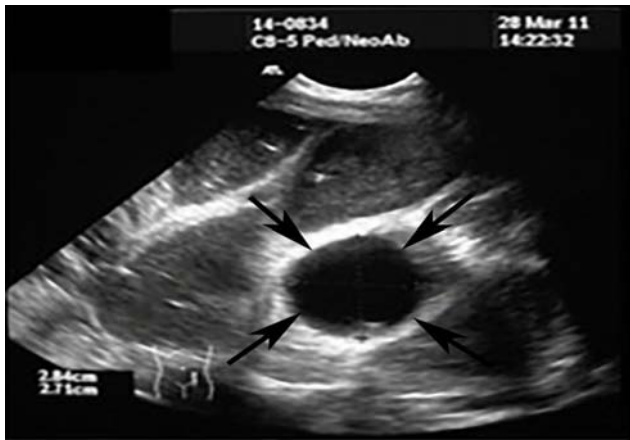
An emergency diagnostic laparotomy and enterotomy was performed soon after the imaging study and revealed a mobile intraluminal mass in the jejunum which was a crystal jelly ball bezoar. After an operation to remove the bezoar, the child recovered well and was discharged after three days.

### Case 2

A previously healthy 17 month old girl, presented to emergency room with non-bilious vomiting for one day and poor oral intake. There was no documented history of foreign body ingestion. Later,



**Figure 1:** Eighteen-month-old girl with crystal jelly ball ingestion (Case 1). The transabdominal transverse sonogram using linear superficial probe L12-5 MHz demonstrates an intraluminal anechoic cystic lesion with a “double wall sign” of thin hyperechoic inner layer (white arrow) and thin hypoechoic outer layer (black arrow).



**Figure 2:** Seventeen-month-old girl with crystal jelly ball ingestion (Case 2). The transabdominal transverse sonogram using curvilinear probe C8-5 MHz shows a well-defined anechoic lesion with a thin hyperechoic wall (arrows) within the small bowel. The visualized proximal small bowel is dilated and fluid-filled.

she developed abdominal distension and nil bowel output for 3 days. Examination revealed that she was febrile and dehydrated with a distended abdomen.

She was then referred to the paediatric surgery team with provisional diagnosis of intestinal obstruction. An abdominal x-ray showed evidence of intestinal obstruction with no radio-opaque intra-abdominal lesion. Ultrasound evaluation of the abdomen using a C8-5 MHz convex probe Philips ATL ultrasound (Eindhoven, The Netherlands), showed a well-defined hypo echoic intraluminal lesion at the distal ileum which was mobile with peristalsis. There were dilated small bowel loops proximal to this lesion. Primary diagnosis of a foreign body was suspected (Figure 2).

The patient underwent laparotomy and enterotomy. Intraoperative findings showed a bezoar comprised of a jelly-like material fragmented into multiple pieces within the ileum (Figure 3). Post-operatively, the child recovered well and was discharged after five days.

## Discussion

As a natural way to explore their curiosity and begin to learn about the world around them, young children often place various items into their mouths. Although this is normal developmental behaviour, it can also create a dangerous scenario. Ten-twenty percent of ingested Foreign Bodies (FB) into the gastrointestinal system requires endoscopic removal, and less than 1% require surgery when complicated by intestinal obstruction, stricture, or even perforation [1-3].

The most common ingested FB in children is organic with approximately more than half of the cases are peanut [2]. Organic materials are radiolucent on radiograph and this is also true in decorative crystal jelly balls. Radiograph will only show the complications of intestinal obstruction which is similar as in our cases [4]. On the other hand, radiopaque FB such as coins, batteries, sharp or metal objects, magnets, bone particles and fruit stones were demonstrated in 26.55% of cases [1,3].



**Figure 3:** Seventeen-month-old girl with crystal jelly ball ingestion (Case 2). Specimen of a polymer crystal jelly ball bezoar obtained post-operatively after removal following enterostomy.

Crystal jelly balls, often used for planting or decorative purposes, are attractive to children because of their interesting color and texture. Made from a polymer which can act as water reservoir, they can absorb water 100 times more than their dry volume and expand 30-60 times their original volume [5]. Thus, if ingested, a crystal jelly ball can cause intestinal obstruction especially proximal to the ileocecal junction [4,6].

To our current literature review, there is no reported case discussion pertaining to the sonographic appearance of an intraluminal crystal jelly ball. Previous literature described that this FB demonstrated as an intraluminal hypodense mass on CT and sign of intestinal obstruction [4]. Our case series showed that an intraluminal crystal jelly ball could mimic other sonographic findings, such as an enteric duplication cyst. On sonography, enteric duplication cyst shows an inner hyperechoic mucosal rim and outer hypo echoic muscular rim giving rise to a “double wall sign” or “gut signature sign” [7]. However, there are other lesions that can mimic these signs which are commonly described as “pseudo double wall” signs or “pseudo gut signature” signs; examples being a mesenteric cyst or twisted ovarian cyst [8].

The intraluminal crystal jelly ball in case 1 was demonstrated as a well-defined anechoic lesion with “double-wall sign”, using a high frequency probe (12MHz). In comparison, the intraluminal crystal jelly ball in Case 2 did not show the “double wall sign” when a lower frequency probe was used (8MHz). This interface phenomenon artifact may be observed along the wall of other cysts and may mimic the “double wall sign” configuration in duplication cysts. A previous study stated that this artifact presented in 12 of 27 non-enteric cysts which was seen over a small segment of the lower portion of the cyst wall and disappeared with slight movements of the transducer. A false-positive sign may become a more frequent occurrence with higher-frequency ultrasound probes [7].

We had six additional similar cases in our country that were correctly diagnosed as an intraluminal crystal jelly ball upon preoperative ultrasound. We alerted our Ministry of Domestic

Trade, Co-operatives and Consumerism regarding the medical complications of this household product, which resulted in an official ban of the crystal jelly ball in our country [9].

In conclusion, intraluminal crystal jelly ball FB can be devastating as it can result in intestinal obstruction due to its absorptive effect. It is radiolucent on radiograph and hypodense on CT when located in the intestinal lumen. Whereas, the FB appeared as an anechoic cystic mass on ultrasound that sometimes may mimic an enteric duplication cyst. This criteria is crucial in order to avoid unnecessary additional imaging, especially when radiation protection is of major concern in paediatric population.

## References

1. Sahin A, Meteroglu F, Eren S, Celik Y. Inhalation of foreign bodies in children: experience of 22 years. *J Trauma Acute Care Surg.* 2013; 74: 658-663.
2. Mu L, He P, Sun D. Inhalation of foreign bodies in Chinese children: a review of 400 cases. *Laryngoscope.* 1991; 101: 657-660.
3. Chung S, Forte V, Campisi P. A review of pediatric foreign body ingestion and management. *Clinical Pediatric Emergency Medicine.* 2010; 11: 225-230.
4. Mirza B, Sheikh A. Mortality in a case of crystal gel ball ingestion: an alert for parents. *APSP J Case Rep.* 2012; 3: 6.
5. Decorative water crystal™ website.
6. Mirza B, Ijaz L, Sheikh A. Decorative crystal balls causing intestinal perforation. *J Indian Assoc Pediatr Surg.* 2011; 16: 106-107.
7. Cheng G, Soboleski D, Daneman A, Poenaru D, Hurlbut D. Sonographic pitfalls in the diagnosis of enteric duplication cysts. *AJR Am J Roentgenol.* 2005; 184: 521-525.
8. Godfrey H, Abernethy L, Boothroyd A. Torsion of an ovarian cyst mimicking enteric duplication cyst on transabdominal ultrasound: two cases. *Pediatr Radiol.* 1998; 28: 171-173.
9. 'Crystal ball' seed-growing kits banned from The Star Online website. 2011.