

## Clinical Image

# Anticoagulant-Related Bleeding Presenting with Abdominal Hematoma

Wilson T Lao and Wing P Chan\*

Department of Radiology, Wan Fang Hospital, Taipei Medical University, Taiwan

\*Corresponding author: Wing P Chan, Department of Radiology, Wan Fang Hospital, Taipei Medical University, 111 Hsing-Long Road, Sec 3, Taipei 116, Taiwan

Received: September 09, 2015; Accepted: January 25, 2016; Published: January 29, 2016

## Keywords

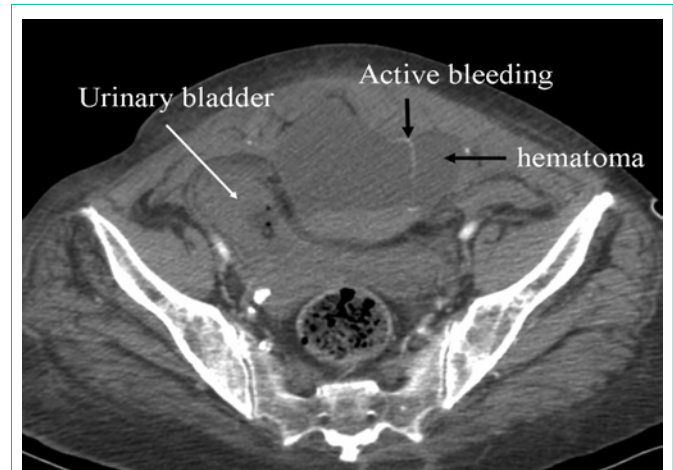
Abdomen; Anticoagulant; Bleeding; Computed tomography (CT); Hematoma

## Clinical Image

A 71-year-old woman presented to the emergency department with a chief complaint of diffuse abdominal pain and a palpable mass in her lower abdomen. She had a past history of hypertensive cardiovascular disease and right hemiplegia due to stroke, for which she was taking regular aspirin (100 mg/day). On physical examination, bradycardia (51 beats/min) and hypotension (8/55 mmHg) were noted. The patient denied any history of trauma. The coagulation profile showed International Normalized Ratio (INR) >10 (reference range, 0.8–1.15), prothrombin time >120 (8–12), and Activated Partial Thromboplastin Time (APTT) >181 (24–35). Computed tomography scan of the abdomen showed a hematoma in the lower abdomen with a fluid-fluid level and active bleeding, as indicated by contrast extravasation from the left rectus abdominis muscle (Figure 1). Angiography revealed bleeding from the left inferior epigastric artery, which was treated by embolization of the vessel. However, the patient died of acute renal failure and related complications two days later.

Treatment with warfarin sodium or aspirin alone or in combination is effective for preventing stroke caused by arterial or venous thromboembolism. However, their use is associated with risk of hemorrhage [1,2]. Predictors of hemorrhage during anticoagulation are: poor initiation and control of anticoagulation, associated diseases (such as cerebrovascular disease and peripheral vascular disease), old age, drugs, and food interactions [3,4].

Anticoagulant treatment requires monitoring of the INR at least once daily for the first two days and 2 to 3 times per week for the next 1–2 weeks in order to achieve and maintain a therapeutic INR range of 2.0 to 3.0 in most cases [5]. Once stable, the INR can be monitored once every 4 weeks but more frequently if dose adjustment is needed. In patients on long-term anticoagulant therapy, the dose response can fluctuate due to dietary factors, concurrent medication changes, alcohol consumption, or poor compliance.



**Figure 1:** CT scan of the abdomen shows hematoma in the lower abdomen with fluid-fluid level and active bleeding, as evidenced by contrast extravasation (arrow).

Bleeding can be classified as major (with incidence 1.2–7.0 episodes per 100 patients) or minor (with incidence 2.0–24 per 100 patients) [5]. Minor bleeding events are not life threatening and include occult gastrointestinal tract bleeding, hematuria, nose bleeding, bruising, and symptomatic anemia. Major bleeding, as experienced by our patient, may be fatal and usually requires medical or surgical intervention such as blood transfusion or embolization.

When a patient is treated regularly with an anticoagulant after suffering a stroke, it is important to check the INR daily and then weekly to achieve INR stability.

## References

1. Baglin TP, Keeling DM, Watson HG. British Committee for Standards in Haematology. Guidelines on oral anticoagulation (warfarin): third edition--2005 update. *Br J Haematol.* 2006; 132: 277-285.
2. Fihn SD, Callahan CM, Martin DC, McDonnell MB, Henikoff JG, White RH. The risk for and severity of bleeding complications in elderly patients treated with warfarin. The National Consortium of Anticoagulation Clinics. *Ann Intern Med.* 1996; 124: 970-979.
3. Beyth RJ, Quinn LM, Landefeld CS. Prospective evaluation of an index for predicting the risk of major bleeding in outpatients treated with warfarin. *Am J Med.* 1998; 105: 91-99.
4. Hylek EM, Regan S, Go AS, Hughes RA, Singer DE, Skates SJ. Clinical predictors of prolonged delay in return of the international normalized ratio to within the therapeutic range after excessive anticoagulation with warfarin. *Ann Intern Med.* 2001; 135: 393-400.
5. Landefeld CS, Beyth RJ. Anticoagulant-related bleeding: clinical epidemiology, prediction, and prevention. *Am J Med.* 1993; 95: 315-328.