

## Clinical Image

## Isolated Subscapular Muscle Rupture

Onder Yeniceri<sup>1</sup>, Nesat Cullu<sup>2\*</sup>, Mehmet Deveer<sup>2</sup> and Rabia Mihriban Kilinc<sup>2</sup>

<sup>1</sup>Department of Radiology, Yucelen Hospital, Turkey

<sup>2</sup>Department of Radiology, Mugla Sitki Kocman University, Turkey

\*Corresponding author: Nesat Cullu, Department of Radiology, Mugla Sitki Kocman University, School of Medicine, Central Campus, 48000, Mugla/Turkey

Received: January 30, 2015; Accepted: February 25, 2015; Published: February 27, 2015

## Clinical Image

A 70-year old female presented at the Orthopaedic Polyclinic with complaints of pain in the left shoulder which increased particularly at night. There was no history of trauma, surgery or injection in the shoulder region. Physical examination revealed no soft tissue swelling and ecchymosis. Anterior aspect of the glenohumeral joint was painful. Internal rotation was limited. Active abduction could be performed to 50 degrees. On MRI, on the axial fat-sat T2 series, the subscapular muscle tendon was ruptured. The biceps muscle long head of the bicipital groove was displaced towards the medial. Shoulder-sling was applied to upper extremity and nonsteroidal antiinflammatory analgesic treatment was initiated. Subsequently, physical therapy was planned for the joint maintenance (Figure 1&2).

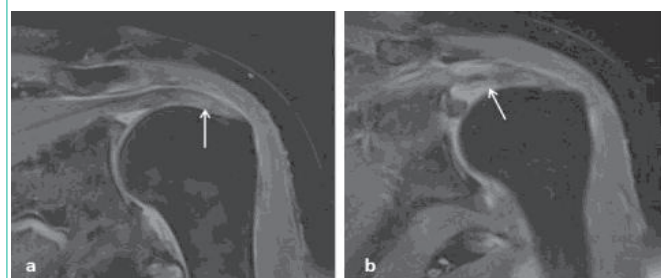


Figure 1: On MRI, on the coronal fat-sat T2 series, the sub scapular muscle tendon was ruptured (a, b) (white arrow).

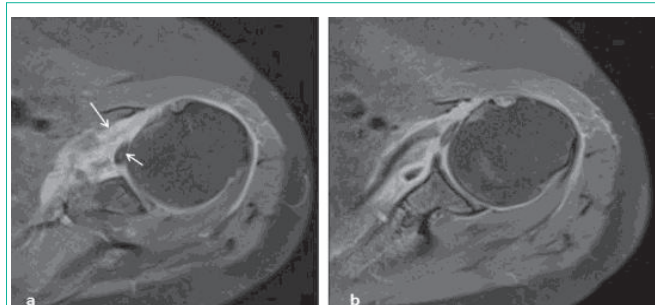


Figure 2: The biceps muscle long head of the bicipital groove was displaced towards the medial (a, b) (small white arrow).

Isolated subscapular tendon ruptures are rare, comprising 5% of rotator cuff tears. External rotation of the arm in abduction and forced hyperextension is an important mechanism in the occurrence of a tear. Shoulder pain and restricted joint movement are the most significant complaints. If there are no concomitant calcific changes, then direct radiographs will not be sufficient for diagnosis. Ultrasonography is useful in diagnosis but MRI is the most valuable method in the diagnosis of tears and accompanying changes [1,2].

## References

1. Biondi J, Bear TF. Isolated rupture of the subscapularis tendon in an arm wrestler. *Orthopedics*. 1988;11: 647-649.
2. Kreuz PC, Remiger A, Erggelet C, Hinterwimmer S, Niemeyer P, Gachter A. Isolated and combined tears of the subscapularis tendon. *Am J Sports Med*. 2005; 33: 1831-1837.