

Research Article

Improved Perioperative Analgesia with Ultrasound-Guided Ilioinguinal/iliohypogastric Nerve or Transversus Abdominis Plane Block for Open Inguinal Surgery: A Systematic Review and Meta-Analysis of Randomized Controlled Trials

Yuexiang Wang^{1,2}, Tao Wu³, Marisa J Terry³, Jason S Eldrige¹, Qiang Tong^{1,3}, Patricia J Erwin⁴, Zhen Wang⁵ and Wenchun Qu^{1,3*}

¹Department of Anesthesiology Pain Division, Mayo Clinic, Rochester, USA

²Department of Ultrasound Medicine, Chinese PLA General Hospital, Beijing, China

³Department of Physical Medicine and Rehabilitation, Mayo Clinic, Rochester, USA

⁴Department of Library-Public Services, Mayo Clinic, Rochester, USA

⁵Center for the Science of Healthcare Delivery, Mayo Clinic, Rochester, USA

*Corresponding author: Wenchun Qu, Department of Physical Medicine and Rehabilitation, Department of Anesthesiology Pain Division, Mayo Clinic, Rochester, 55905, USA

Received: May 22, 2015; Accepted: July 23, 2015;

Published: July 27, 2015

Abstract

Ilioinguinal/iliohypogastric (II/IH) nerve and transversus abdominis plane (TAP) blocks are both effective perioperative analgesic techniques for open inguinal surgery. Ultrasound-guided II/IH nerve and TAP blocks have been increasingly utilized in patients for perioperative analgesia. Yet the use of ultrasound has not been fully evaluated. We conducted this meta-analysis to evaluate the clinical efficacy of ultrasound-guided II/IH nerve or TAP blocks for perioperative analgesia in patients undergoing open inguinal surgery. A systematic search of seven databases was conducted from database inception to March 5, 2015. Randomized controlled trials (RCTs) comparing the clinical efficacy of either ultrasound-guided or landmark-based techniques to perform II/IH nerve and TAP blocks for perioperative analgesia in patients with open inguinal surgery were included. Two reviewers independently (and in duplicate) screened abstracts and full texts. We constructed random effects models to pool standardized mean difference (SMD) for continuous outcomes and odds ratio (OR) for dichotomized outcomes. Heterogeneity between studies was estimated by I² statistic. One hundred thirty-nine articles were identified and among them 4 articles were eligible for the final analysis. Ultrasound-guided II/IH nerve or TAP blocks were associated with reduced use of intraoperative additional analgesia with OR=0.21 (95% CI: 0.09 to 0.49; p<0.001; I²=0.00%) and significant reduction of pain scores during day-stay with SMD=-0.96 (95% CI: -1.68 to -0.24; p<0.001; I²=88.3%). The use of rescue drug was also significantly lower in the ultrasound-guided group (OR=0.16; 95% CI: 0.06, 0.40; p<0.001, I²=10.2%). In conclusion, the use of ultrasound-guidance to perform an II/IH nerve or a TAP block was associated with improved perioperative analgesia in patients following open inguinal surgery compared to landmark-based methods.

Keywords: Ultrasound; Ilioinguinal/iliohypogastric nerve; Inguinal surgery

Abbreviations

II/IH: Ilioinguinal/Iliohypogastric; TAP: Transversus Abdominis Plane; RCT: Randomized Controlled Trials; SMD: Standard Mean Difference; OR: Odds Ratio.

Introduction

Open inguinal surgery can lead to high levels of intra- and post-operative pain. Currently available perioperative pain management options include oral or intravenous analgesics, surgical wound infiltration, and single-shot caudal blocks. However, these treatments may yield suboptimal pain control or may be limited by the significant risk of side effects. Of the commonly used oral analgesics, acetaminophen has only mild analgesic properties and has a prolonged time to onset [1, 2]. Opioid medications are associated with somnolence, nausea, vomiting, and respiratory depression [1]. The potential risks of caudal blocks include subcutaneous infiltration,

blood vessel puncture, and dural penetration [3, 4]. Recently, ilioinguinal/iliohypogastric (II/IH) nerve or transversus abdominis plane (TAP) blocks have attracted interest as viable alternatives [5-11] to provide effective perioperative analgesia for open inguinal surgery. Importantly, it may provide similar duration of analgesia as a caudal block, with a smaller dosage of local anesthetic agent, at 0.3 ml/kg of 0.25% bupivacaine in II/IH block compared to 1 ml/kg used in caudal block [7,12].

There are two main techniques for II/IH or TAP blocks: the landmark-based method or the use of ultrasound guidance. Traditional landmark-based II/IH block using a fascial “click” technique has a low accuracy rate and is associated with increased procedural risks. It is difficult to identify the correct fascial plane, which may lead to the need for multiple attempts [9, 10, 11]. A failure rate of 28-45% has been reported, even in experienced hands [13,14]. Weintraud et al [14] reported a mere 14% accuracy rate when local

anesthetic was deposited using a landmark-based approach and subsequently imaged under ultrasound to document the location of the fluid collection. No optimal injection site along the course of II/IH nerve have been identified to improve the accuracy rate largely due to the fact that none of the sites studied has an anatomical feature that would make the 'clicking' prominent enough to be reproducible [13, 15-18]. In addition, landmark-based techniques are associated with substantial risk of colonic or small bowel punctures, pelvic hematoma [19-21], and femoral nerve palsy [22-24].

Ultrasound guidance in regional anesthesia has gained popularity in recent years [25, 26-28]. It has emerged as an excellent modality to visualize the TAP, II/IH nerves, vessels, and needle, which may be beneficial in reducing the risk of intraneural, intravascular, or intraperitoneal injections. In addition, a smaller dosage of local anesthetic may be possible because the needle placement can be confirmed, which negates any additional volume used to offset for inaccurate needle placement [16, 29-33]. The disadvantages of an ultrasound guided procedure are the required special equipment, training, and increased cost. The cost-benefit justification requires assessment of efficacy with ultrasound guidance in comparison with landmark-based approach. Multiple randomized controlled trials have been conducted, but often with small sample size, heterogeneous designs, and conflicting outcomes. Therefore, we conducted this systematic review and meta-analysis to summarize the current evidence and evaluate the clinical efficacy of ultrasound-guided II/IH or TAP block for perioperative analgesia in pediatric and adult patients undergoing inguinal surgery.

Methods

The study protocol was finalized in advance of any data collection, which defined objectives, search strategy, inclusion/exclusion criteria, data extraction, outcomes of interest, and analytical approaches. The reporting of this systematic review complies with the Preferred Reporting Items for Systematic Reviews and Meta-Analyses (PRISMA) statement [34,35].

Search strategy and study selection

Comprehensive searches were performed on PubMed, Ovid MEDLINE, Ovid EMBASE, Ovid Cochrane CENTRAL, Web of Science, and Scopus from database inception through on March 8, 2015. Each concept used a combination of controlled vocabulary (MeSH and Emtree) combined with text words for each database which uses subject heading (PubMed, MEDLINE, EMBASE, CENTRAL). Web of Science and Scopus depend primarily on text words alone. The subject headings included inguinal canal, hernia, and inguinal, inguinal hernia and text words: inguinal, ilioinguinal or iliohypogastric. In the same fashion, the concept of pain and ultrasound guidance included nerve block, pain, postoperative, as well as text words for ultrasound: echogram*, ultrasound, ultrasono*. Each search was imported into an EndNote (Thomson Reuters Research Soft), a bibliographic database manager, and duplicates removed.

Inclusion and exclusion criteria

We included randomized controlled trials (RCTs) comparing the clinical efficacy of II/IH nerve or TAP block using ultrasound guidance vs. landmark-based technique for perioperative analgesia

in patients following open inguinal surgery. Case series and case reports were excluded. Articles focusing on the therapeutic effect of ultrasound-guided II/IH nerve block for chronic inguinal pain were excluded. Articles focusing on the comparison of ultrasound-guided II/IH nerve or TAP block and wound infiltration were also excluded.

Data extraction and quality assessment

Two reviewers, working independently and in duplicate, (Y.W. and M.T.) reviewed titles and abstracts and then full texts in order to exclude irrelevant studies. All conflicts were discussed and resolved with a third author (W.Q.). The same two reviewers extracted study details from the full text studies using a standardized pilot-tested form. The following data were extracted: the author, year of publication, study location, sample size, patient characteristics (gender, age), general anesthesia, regional anesthesia, timing of regional anesthesia, the surgery performed, and outcome measures including the number of patients receiving additional analgesia during surgery and pain scores of patients during day-stay. The reference sections of all articles were used to identify additional relevant articles.

Quality assessment

We used the Cochrane Risk of bias tool to assess the methodological quality of the included RCTs in terms of sequence generation, allocation concealment, blinding, incomplete outcome data, selective outcome reporting, and other sources of bias [36].

Statistical analysis

For the continuous outcomes (pain scores), we combined

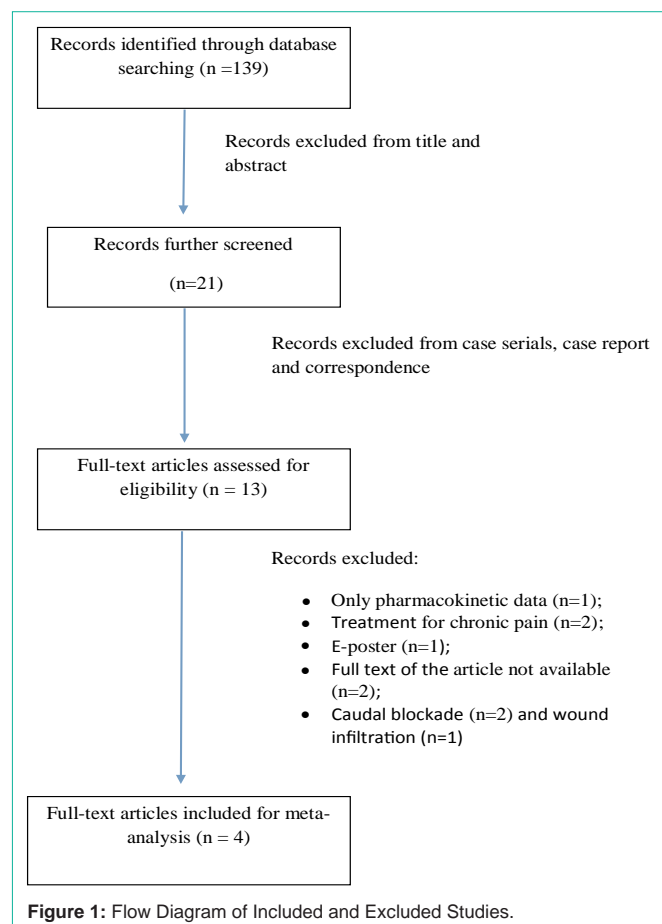


Table 1: The characteristics of the enrolled studies.

First author	Publish year	Country	Sample size	Patients age	Regional anesthesia		Timing of anesthesia	Surgery	Study design	Study conclusion
					Conventional nerve block group	Ultrasound-guided II/IH nerve or TAP block				
Willschke et al.	2005	Austria	100	1 month–8 years	Landmark II/IH nerve block: 0.25% levobupivacaine 0.3ml/kg	US-guided II/IH nerve block: 0.25% levobupivacaine 0.19ml/kg	Before surgery	Inguinal hernia repair, orchidopexy or hydrocele repair.	RCT	Ultrasound-guided II/IH nerve blocks can be achieved with significantly smaller volumes of local anaesthetics.
Aveline et al.	2011	France	273	31-83 years	II/IH block by the loss-of-resistance technique: 0.5%levobupivacaine (1.5 mg /kg)	Ultrasound-guided TAP block: 0.5%levobupivacaine (1.5 mg /kg)	Before surgery	unilateral open inguinal hernia repair	RCT	Ultrasound-guided TAP block provided better pain control than 'blind' II/IH block after inguinal hernia.
Nan et al.	2012	China	100	4-8 years	Landmark II/IH nerve block: 0.8% lidocaine and 0.25% levobupivacaine 0.3ml/kg	US-guided II/IH nerve block: 0.8% lidocaine and 0.25% levobupivacaine 0.2ml/kg	Before surgery	Unilateral inguinal hernia repair, hydrocelectomy, or orchidopexy	RCT	US-guided II/IH nerve block can lower the quantity of local anesthetic and alleviate the medicinal toxicity.
Demirci et al.	2014	Portugal	40	18-80 years	Landmark- II/IH nerve block: 20 ml of 0.5% levobupivacaine	II/IH nerve block with the US guided: 20 ml of 0.5% levobupivacaine	Before surgery	Inguinal hernia repair	RCT	US guided II/IH nerve block in adult are more effective than landmark technique

standardized mean difference (SMD) from the included studies using the Der Simonian and Laird random-effect models [37]. We also calculated odds ratio (OR) for dichotomized outcomes and pooled OR using the Der Simonian and Laird random-effect models.

We used the I^2 statistic to measure the heterogeneity across the included studies, in which $I^2 > 50\%$ suggests high heterogeneity [38]. Although we planned to assess publication bias by visual inspection of funnel plots and conducting the Egger regression asymmetry test, we were unable to conduct these tests due to the limited number of the included studies [39,40]. All statistical analyses were conducted using STATA version 12.1 (Stata Corp LP, College Station, Texas).

Results

Study characteristics

We identified 139 articles, of which four RCTs [16, 41-43] conducted between 2005 and 2014 were eligible for this review (Figure 1). Characteristics of the enrolled studies are described in Table 1. Patients of all ages were included. All patients underwent open surgeries including inguinal hernia repair, orchidopexy, hydrocelectomy or hydrocele repair. All patients received general anesthesia that was maintained by Halothane or Sevoflurane in nitrous oxide and oxygen. All patients were randomized into one of the two technique groups: ultrasound guided group and landmark-based group. All ultrasound guided procedures were performed with a high frequency linear probe. The procedures of the control group were performed with landmark-based technique. All II/IH nerve or TAP blocks in both groups were performed before surgery.

Risk of bias

Figure 2 shows the risk of bias of the included studies. All of the studies reported low risk of bias in terms of incomplete outcome data, and selective outcome reporting. However, patients and care providers were not blinded to half of the included studies and the rest of the studies did not report the blinding at all. We were also unable

to evaluate publication bias due to small number of studies included in the analyses. In summary, the risk of bias within the studies was medium due to potential publication bias and unknown quality.

Outcomes

Four studies were included in the meta-analysis, of which 3 studies [16, 41, 42] blocked the II/IH nerve and 1 study [43] blocked TAP using either ultrasound guided or landmark-based technique. A total of 513 patients were randomized into either one of the two technique groups for II/IH nerve or TAP block: ultrasound guided group (n=245) or landmark-based group (n=259). Two hundred patients were children who were evenly randomized into either group. Of the 313 adult patients, 154 were in the ultrasound guided group and 159 were in the landmark-based group.

Patients who received an ultrasound-guided ilioinguinal/iliohypogastric nerve block were significantly less likely to have intraoperative additional analgesia with OR=0.21 (95% CI: 0.09 to 0.49; $p < 0.001$; $I^2 = 0.0\%$). In day-stay units, the pain score of the ultrasound-guided II/IH or TAP block group was significantly lower than that in the control group with SMD=-0.96 (95% CI: -1.68 to -0.24; $p < 0.001$; $I^2 = 88.3\%$). The use of rescue drug was also significantly lower in the ultrasound-guided group (OR=0.16; 95%

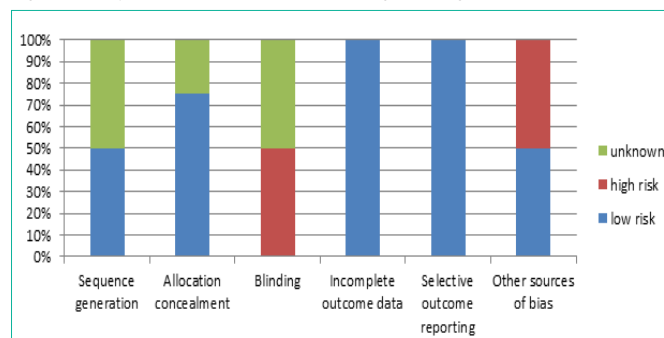


Figure 2: Risk of bias of the included studies.

Table 2: Comparison between ultrasound guided and landmark-based II/IH or TAP blocks.

Outcomes	Measure	ES	95% CI	P-value	I ²
Need intraoperative additional analgesia	OR	0.21	0.09, 0.49	<0.001	0.0%
Pain scores during day-stay	SMD	-0.96	-1.68, -0.24	<0.001	88.3%
Need rescue drug	OR	0.16	0.06, 0.40	<0.001	10.2%
Patient Satisfaction	OR	1.08	0.49, 2.38	0.84	n/a

CI: 0.06, 0.40; $p < 0.001$, $I^2 = 10.2\%$). We found no significant difference on the number of satisfied patients ($p = 0.84$) (Table 2).

Discussion

This meta-analysis shows that ultrasound-guided II/IH nerve or TAP block is associated with reduced use of intraoperative additional analgesia, reduced pain in day-stay unit, and reduced use of rescue drug. This improved efficacy is most likely associated with improved proximity of needle placement and local anesthetic agent deposit to II/IH nerves. Landmark-based II/IH nerve block has a low success rate largely because of the highly variable course of II/IH nerves shown by cadaver studies [18, 44]. In addition, only two muscle layers could be identified in some patients in the common injection sites where the external oblique abdominal muscle is only aponeurosis. Thus, the “click” feeling may not be a reliable way to target the fascial plane between the internal oblique abdominal muscle and the transversus abdominis muscle. In contrast, ultrasound-guided II/IH nerve block could target the II/IH nerve with more accuracy due to the high-resolution imaging of the soft tissue. Not only the abdominal wall layers could be visualized, but also the II/IH nerves themselves could often be detected on real-time ultrasound. The real-time visualization of the injectant flow assists final adjustment of needle position for optimal distribution of the local anaesthetic solution to the nerves lying under the fascia of the transversus abdominis muscle, including II/IH.

The significant decrease in intra-operative analgesia is of great value for patients undergoing open inguinal surgery. Fentanyl and morphine are commonly used for additional intraoperative and PACU pain control, which are associated with common side effects including nausea, vomiting, and respiratory depression [41, 45-47]. The lowest effective amount of local anesthetics for peripheral block is particularly important in pediatric patients because of increased risk of toxicity secondary to a higher level of unbound fraction of local anesthetic in younger age [48]. With ultrasound-guidance, successful peripheral nerve blocks have been reported with a lower dose of local anesthetics, compared with non-guided techniques [29-31].

Ultrasound guidance in regional anesthesia has been recognized as a cost-effective modality and recommended as preferred nerve block techniques in larger anesthetic departments [49]. Access to equipment and training has been dramatically improved over the past few decades through regional anesthesia fellowship programs as well as workshops offered by various academic societies and groups [50]. While the application of ultrasound guidance in perioperative pain control is expanding, this study provides evidence in support of using ultrasound guided II/IH nerve or TAP blocks in managing perioperative open inguinal surgery pain.

Our study has several limitations. Although we conducted a

comprehensive search of five databases, only four studies were included in this review. This small number of studies limited the statistical power of detecting significant finding. In addition, we were unable to test potential publication bias due to the small number of studies. Overall, using the Grades of Recommendation Assessment, Development and Evaluation (GRADE) framework, the overall quality of the evidence is moderate due to the likelihood of publication bias.

Conclusion

In summary, the findings of this meta-analysis suggest that ultrasound-guided II/IH nerve or TAP blocks are associated with improved perioperative analgesia in patients following inguinal surgery compared with landmark-based techniques. While large medical centers may have already adopted the use of ultrasound for guidance in nerve blocks, it is noted that more anesthesia practices may benefit from ultrasound guided II/IH nerve or TAP block techniques in the management of perioperative pain associated with open inguinal surgeries.

References

- Ho D, Keneally JP. Analgesia following paediatric day-surgical orchidopexy and herniotomy. *Paediatr Anaesth*. 2000; 10: 627-631.
- Arana A, Morton NS, Hansen TG. Treatment with paracetamol in infants. *Acta Anaesthesiol Scand*. 2001; 45: 20-29.
- Beyaz SG, Tokgöz O, Tüfek A. Caudal epidural block in children and infants: retrospective analysis of 2088 cases. *Ann Saudi Med*. 2011; 31: 494-497.
- Veyckemans F, Van Obbergh LJ, Gouverneur JM. Lessons from 1100 pediatric caudal blocks in a teaching hospital. *Reg Anesth*. 1992; 17: 119-125.
- Smith T, Moratin P, Wulf H. Smaller children have greater bupivacaine plasma concentrations after ilioinguinal block. *Br J Anaesth*. 1996; 76: 452-455.
- Markham SJ, Tomlinson J, Hain WR. Ilioinguinal nerve block in children. A comparison with caudal block for intra and postoperative analgesia. *Anaesthesia*. 1986; 41: 1098-1103.
- Bhattarai BK, Rahman TR, Sah BP. Analgesia after inguinal herniotomy in children: combination of simplified (Single Puncture) ilioinguinal and iliohypogastric nerve blocks and wound infiltration vs. caudal block with 0.25% bupivacaine. *Kathmandu Univ Med J (KUMJ)*. 2005; 3: 208-211.
- Saeed A, Khan AR, Lee V, Aslam A, Brain J, Williams MP, et al. Pain management for unilateral orchidopexy in children: an effective regimen. *World J Surg*. 2009; 33: 603-606.
- Ho D, Keneally JP. Analgesia following paediatric day-surgical orchidopexy and herniotomy. *Paediatric anaesthesia*. 2000; 10: 627-631.
- Moore MA, Wandless JG, Fell D. Paediatric postoperative analgesia. A comparison of rectal diclofenac with caudal bupivacaine after inguinal herniotomy. *Anaesthesia*. 1990; 45: 156-158.
- Hannallah RS, Broadman LM, Belman AB, Abramowitz MD, Epstein BS. Comparison of caudal and ilioinguinal/iliohypogastric nerve blocks for control of post-orchidopexy pain in pediatric ambulatory surgery. *Anesthesiology*. 1987; 66: 832-834.
- Seyedhejazi M, Daemi OR, Taheri R, Ghojzadeh M. Success rate of two different methods of ilioinguinal-iliohypogastric nerve block in children inguinal surgery. *Afr J Paediatr Surg*. 2013; 10: 255-258.
- Lim SL, Ng Sb A, Tan GM. Ilioinguinal and iliohypogastric nerve block revisited: single shot versus double shot technique for hernia repair in children. *Paediatr Anaesth*. 2002; 12: 255-260.
- Weintraud M, Marhofer P, Bösenberg A, Kapral S, Willschke H, Felfernig M, et al. Ilioinguinal/iliohypogastric blocks in children: where do we administer

- the local anesthetic without direct visualization? *Anesth Analg*. 2008; 106: 89-93, table of contents.
15. Dalens B. Regional anesthetic techniques. In: Bissonnette BDB (ed) *Pediatric Anesthesia—Principles and Techniques*. New York: McGraw Hill. 2008; 563-565.
 16. Willschke H, Marhofer P, Bösenberg A, Johnston S, Wanzen O, Cox SG, et al. Ultrasonography for ilioinguinal/iliohypogastric nerve blocks in children. *Br J Anaesth*. 2005; 95: 226-230.
 17. Sethna N, Berde C. Pediatric regional anesthesia. In: Gregory GA, ed. *Pediatric Anesthesia*, Vol. 1, 2nd. New York: Churchill Livingstone Inc. 1989; 647- 678.
 18. Van Schoor AN, Boon JM, Bosenberg AT. Anatomical considerations of the pediatric ilioinguinal/iliohypogastric nerve block. *Paediatric anaesthesia*. 2005; 15: 371-377.
 19. Jöhr M, Sossai R. Colonic puncture during ilioinguinal nerve block in a child. *Anesth Analg*. 1999; 88: 1051-1052.
 20. Amory C, Mariscal A, Guyot E, Chauvet P, Leon A, Poli-Merol ML. Is ilioinguinal/iliohypogastric nerve block always totally safe in children? *Paediatr Anaesth*. 2003; 13: 164-166.
 21. Vaisman J. Pelvic hematoma after an ilioinguinal nerve block for orchialgia. *Anesth Analg*. 2001; 92: 1048-1049.
 22. Notaras MJ. Transient femoral nerve palsy complicating preoperative ilioinguinal nerve blockade inguinal for herniorrhaphy. *Br J Surg*. 1995; 82: 854.
 23. Ghani KR, McMillan R, Paterson-Brown S. Transient femoral nerve palsy following ilio-inguinal nerve blockade for day case inguinal hernia repair. *J R Coll Surg Edinb*. 2002; 47: 626-629.
 24. Erez I, Buchumensky V, Shenkman Z, Lazar L, Freud E. Quadriceps paresis in pediatric groin surgery. *Pediatr Surg Int*. 2002; 18: 157-158.
 25. Dillow JM, Rosett RL, Petersen TR. Ultrasound-guided parasacral approach to the sciatic nerve block in children. *Paediatric anaesthesia*. 2013; 23: 1042-1047.
 26. Wang LZ, Hu XX, Zhang YF, Chang XY. A randomized comparison of caudal block by sacral hiatus injection under ultrasound guidance with traditional sacral canal injection in children. *Paediatric anaesthesia*. 2013; 23: 395-400.
 27. Miller BR. Combined ultrasound-guided femoral and lateral femoral cutaneous nerve blocks in pediatric patients requiring surgical repair of femur fractures. *Pediatric Anesthesia*. 2011; 21: 1163-1164.
 28. Miller BR. Ultrasound-guided fascia iliaca compartment block in pediatric patients using a long-axis, in-plane needle technique: a report of three cases. *Paediatr Anaesth*. 2011; 21: 1261-1264.
 29. Bodner G, Bernathova M, Galiano K, Putz D, Martinoli C, Felfernig M. Ultrasound of the lateral femoral cutaneous nerve: normal findings in a cadaver and in volunteers. *Reg Anesth Pain Med*. 2009; 34: 265-268.
 30. Riazi S, Carmichael N, Awad I, Holtby RM, McCartney CJ. Effect of local anaesthetic volume (20 vs 5 ml) on the efficacy and respiratory consequences of ultrasound-guided interscalene brachial plexus block. *Br J Anaesth*. 2008; 101: 549-556.
 31. Danelli G, Ghisi D, Fanelli A, Ortu A, Moschini E, Berti M, et al. The effects of ultrasound guidance and neurostimulation on the minimum effective anesthetic volume of mepivacaine 1.5% required to block the sciatic nerve using the subgluteal approach. *Anesth Analg*. 2009; 109: 1674-1678.
 32. Abdellatif AA. Ultrasound-guided ilioinguinal/iliohypogastric nerve blocks versus caudal block for postoperative analgesia in children undergoing unilateral groin surgery. *Saudi journal of anaesthesia*. 2012; 6: 367-372.
 33. Fredrickson MJ, Paine C, Hamill J. Improved analgesia with the ilioinguinal block compared to the transversus abdominis plane block after pediatric inguinal surgery: a prospective randomized trial. *Paediatric anaesthesia*. 2010; 20: 1022-1027.
 34. Liberati A, Altman DG, Tetzlaff J. The PRISMA statement for reporting systematic reviews and meta-analyses of studies that evaluate healthcare interventions: explanation and elaboration. *PLoS Med*. 2009; 6: e1000100.
 35. Higgins J, Green S. *Cochrane Handbook for Systematic Reviews of Interventions* Version 510. The Cochrane Collaboration. 2011.
 36. Higgins JP, Green S. *Cochrane Handbook for Systematic Reviews of Interventions*. Cochrane Book Series. 2008; 187-241.
 37. DerSimonian R, Laird N. Meta-analysis in clinical trials. *Control Clin Trials*. 1986; 7: 177-188.
 38. Higgins JP, Thompson SG, Deeks JJ, Altman DG. Measuring inconsistency in meta-analyses. *BMJ*. 2003; 327: 557-560.
 39. Egger M, Davey Smith G, Schneider M, Minder C. Bias in meta-analysis detected by a simple, graphical test. *BMJ*. 1997; 315: 629-634.
 40. Ioannidis JP, Trikalinos TA. The appropriateness of asymmetry tests for publication bias in meta-analyses: a large survey. *CMAJ*. 2007; 176: 1091-1096.
 41. Demirci A, Efe EM, Türker G, Gurbet A, Kaya FN, Anil A, et al. Iliohypogastric/ ilioinguinal nerve block in inguinal hernia repair for postoperative pain management: Comparison of the anatomical landmark and ultrasound guided techniques. *Braz J Anesthesiol*. 2014; 64: 350-356.
 42. Nan Y, Zhou J, Ma Q, Li T, Lian QQ, Li J. [Application of ultrasound guidance for ilioinguinal or iliohypogastric nerve block in pediatric inguinal surgery]. *Zhonghua Yi Xue Za Zhi*. 2012; 92: 873-877.
 43. Aveline C, Le Hetet H, Le Roux A, Vautier P, Cognet F, Vinet E, et al. Comparison between ultrasound-guided transversus abdominis plane and conventional ilioinguinal/iliohypogastric nerve blocks for day-case open inguinal hernia repair. *Br J Anaesth*. 2011; 106: 380-386.
 44. Rosenberger RJ, Loeweneck H, Meyer G. The cutaneous nerves encountered during laparoscopic repair of inguinal hernia: new anatomical findings for the surgeon. *Surg Endosc*. 2000; 14: 731-735.
 45. Bray RJ, Woodhams AM, Vallis CJ, Kelly PJ, Ward-Platt MP. A double-blind comparison of morphine infusion and patient controlled analgesia in children. *Paediatr Anaesth*. 1996; 6: 121-127.
 46. Kokinsky E, Thornberg E, Nilsson K, Larsson LE. Postoperative nausea and vomiting in children using patient-controlled analgesia: the effect of prophylactic intravenous dixyrazine. *Acta Anaesthesiol Scand*. 1999; 43: 191-195.
 47. Doyle E, Byers G, McNicol LR, Morton NS. Prevention of postoperative nausea and vomiting with transdermal hyoscine in children using patient-controlled analgesia. *Br J Anaesth*. 1994; 72: 72-76.
 48. Tucker GT, Boyes RN, Bridenbaugh PO, Moore DC. Binding of anilide-type local anesthetics in human plasma. I. Relationships between binding, physicochemical properties, and anesthetic activity. *Anesthesiology*. 1970; 33: 287-303.
 49. Ehlers L, Jensen JM, Bendtsen TF. Cost-effectiveness of ultrasound vs nerve stimulation guidance for continuous sciatic nerve block. *Br J Anaesth*. 2012; 109: 804-808.
 50. Mariano ER. Making it work: setting up a regional anesthesia program that provides value. *Anesthesiol Clin*. 2008; 26: 681-692, vi.