

Clinical Image

Small Bowel Obstruction after Gastrostomy Removal

McCarthy D¹, Jassal N¹ and Sabini RS^{1*}

¹Department of Physical Medicine & Rehabilitation, Hofstra North Shore-LIJ School of Medicine at Hofstra University, USA

*Corresponding author: Sabini RS, Department of Physical Medicine & Rehabilitation, North Shore LIJ - Southside Hospital, USA

Received: November 18, 2014; Accepted: November 19, 2014; Published: November 20, 2014

Keywords

PEG complication, Traumatic brain injury, Foreign object, Bowel obstruction

A 55-year-old-male sustained a traumatic brain injury after a fall secondary to alcohol intoxication. He developed respiratory failure requiring a bumper-type Percutaneous Endoscopic Gastrostomy (PEG). The patient also had significant cognitive deficits with agitation requiring physical restraints including vest and mittens. During inpatient rehabilitation, his cognition and swallowing improved to warrant PEG removal. However, traction removal of the PEG was complicated by a break in the tube and the patient subsequently developed abdominal pain. An abdominal x-ray demonstrated dilated loops of small bowel but no radiopaque foreign body (Figure 1). The abdominal CT demonstrated dilated loops of small bowel and a foreign body measuring 2.65cm x 1.65cm in the distal small bowel (Figure 2). What was the object?

The object was a plastic buckle from a hand mitten presumably ingested during his acute hospitalization. The buckle lodged itself around the bumper, causing increased resistance and difficulty in the removal of the PEG. When the PEG broke, the bumper and buckle were released causing the small bowel obstruction that was managed medically.

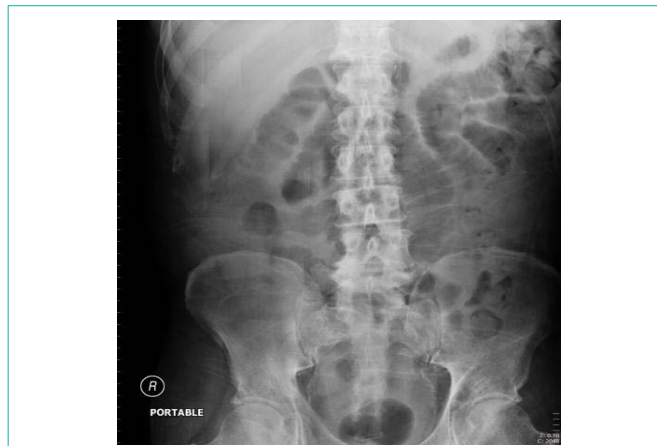

Figure 1: Portable AP x-ray view of the abdomen.

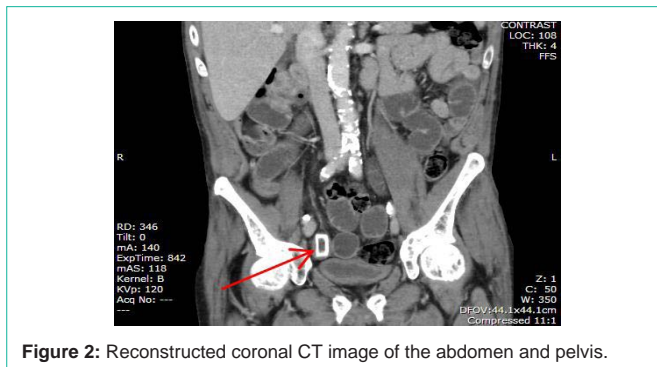


Figure 2: Reconstructed coronal CT image of the abdomen and pelvis.