

Research Article

Parental Report of Child's Depressive Symptoms and Cerebral Cortical Volume: Racial Differences

Assari S^{1,2,3*}, Najand B¹ and Saqib M⁴¹Marginalization-Related Diminished Returns (MDRs) Research Center, Charles Drew University, Los Angeles, CA 90059, USA²Department of Family Medicine, Charles Drew University, Los Angeles, CA 90059, USA³Department of Urban Public Health, Charles Drew University, Los Angeles, CA 90059, USA⁴University of Michigan School of Public Health, Ann Arbor, MI, 48109, USA***Corresponding author:** Shervin Assari, Marginalization-Related Diminished Returns (MDRs) Research Center, Charles Drew University, Los Angeles, CA 90059, USA; Email: assari@umich.edu**Received:** December 06, 2021; **Accepted:** January 06, 2022; **Published:** January 13, 2022**Abstract**

Background: Although the association between self-reported depression and altered properties of the prefrontal cortex are well described, less is known about the link between parental reports or child depressive symptoms and volume for various cortical structures. It is also unknown whether these associations differ by race/ethnicity.

Aim: This study tested the associations between parental reports of the child's depressive symptoms, and volume of various cortical structures in 9/10-year-old U.S. children. We also explored racial/ethnic differences in these associations.

Methods: We used the Adolescent Brain Cognitive Development (ABCD) study's baseline data for this cross-sectional study. Our analytical sample included 10,855 non-Latino Black and non-Latino White U.S. children between the ages of 9 and 10. The independent variable was the parental report or child's depressive symptoms, measured using Parent Adult Self Report Scores Aseba (ASR). Structural Magnetic Resonance Imaging (sMRI) was used to measure the volume of various cortical structures based on the Desikan cortical atlas. Race/ethnicity was the moderator. Age, sex, parental education, household income, and family structure were the covariates. Mixed-effects regression models were used for data analysis.

Results: In the overall sample, parental report of child's depressive symptoms was associated with the volume of cortical structures. The direction of the association between parental report or child's depressive symptoms (PRCDS) and cerebral cortex regions differed across cortical areas. These associations also differed between non-Latino Black and non-Latino White children. Opposite associations were found for various cortical structures and regions including the right caudal middle frontal, Isthmus cingulate, lateral orbitofrontal, medial orbitofrontal, middle temporal, paracentral, pericalcarine, supramarginal, temporal pole, superior temporal, postcentral, and the Transverse temporal region as well as left bankssts, cuneus, entorhinal, fusiform, inferior temporal, insula, isthmus cingulate, lateral orbitofrontal, medial orbitofrontal, middle temporal, parahippocampal, pericalcarine, rostral middle frontal, superior temporal, supramarginal, Transverse temporal. For almost all of these cortical structures, the association between depressive symptoms and cortical volume was negative in non-Latino White but positive for non-Latino Black children.

Conclusion: Racial differences in the association between parental reports or child depressive symptoms and child cerebral cortical morphometry, in non-Latino Black and non-Latino White children, invite researchers to explore how repeated stress, trauma, and adversity contribute to such differences. Differential access to depression treatment and chronicity of depression may also alter how depression correlates with cortical structures across racial groups.

Keywords: Cerebral cortex; Depression depressive symptoms; Ethnic groups; Population groups; MRI

Introduction

Depression is one of the most common in the U.S. With more than a 16% lifetime prevalence [1], depression imposes a 200 billion dollar burden on the U.S. economy annually [2]. According to the WHO, depression is the leading cause of years lived with disability worldwide [3]. Not only is depression one of the most prevalent non-

fatal health problems [3], it is also linked to multiple health and social consequences, including suicide and addiction [4]. Additionally, only 50% of patients with depression respond to standard-of-care treatments [5], and up to 70% do not get full remission [6]. Over half of all depression cases are from individuals younger than 25 years old, meaning that a heavy burden of depression is on youth and young adults. Youth depression is also a predictor of undesired

outcomes later in life, including chronic illnesses, suicide, addiction, and unemployment [7]. While depression is linked to brain structure impairments [8-11], most of what we know is about the association to an individual's own self-reported depression. Less is known about the association between parental report or child's depressive symptoms (PRCDS) and imaging characteristics of the individual. In addition, due to the lack of diversity in imaging studies of adolescent samples, we know very little about the heterogeneity in the imaging characteristics linked to parental depression.

During the last few decades, structural imaging techniques such as magnetic resonance imaging (MRI) have provided more knowledge on the link between brain structures and depression [12,13]. MRI provides useful information on brain structure with a broad range of techniques for analysis, measurement, and visualization of brain structure's morphology [14]. Various structural magnetic resonance imaging (sMRI) studies in patients with depression have documented morphological changes, mainly regarding changes in thickness and volume of cortical structures [15-17].

Further, the development of voxel-based morphometry (VBM) has allowed for an exploration of the analysis of whole-brain anatomical structures [18]. The VBM method has helped with the detection of some alterations of changes in the volume of gray matter structures in patients with depression [19]. For example, some studies have provided evidence of a decline in the volume of the anterior cingulate cortex (ACC) in depression patients [20,21], which may play a role in various affective and cognitive presentations of depression [22]. In addition, a study indicated a negative association between the cortical thickness of the rostral middle frontal cortex (MFC), and depression severity in untreated patients with first-episode mid-life depression [23]. Other research has documented early morphological alterations in first-episode untreated depression [24,25].

Aims

We are unaware of any previous studies on racial and ethnic differences in the association between depressive symptoms and morphometry of the cerebral cortex. Given that race is a proxy of trauma, poverty, stress, adversity, and discrimination, race -- as a social construct -- may alter the link between cerebral cortex regions and depression. In the present study, we aimed to examine racial and ethnic heterogeneity in the association between depressive symptoms and morphometry of cerebral cortex in a sample of 9/10-year-old American pre-adolescents from the Adolescent Brain Cognitive Development (ABCD) research study [26]. We expected an association between depressive symptoms and surface area, thickness, and volume of various cortical measures. We explored heterogeneity in the direction of the association between depressive symptoms and cerebral cortex regions by race/ethnicity.

Methods

This is a cross-sectional analysis of the baseline ABCD data. ABCD baseline data were collected between 2016 and 2018. The ABCD study is an unprecedented study of brain development following a large, diverse national sample of 9/10 year old children during their transition to young adulthood.

The ABCD sample is primarily selected from schools in the U.S. Sampling was performed *via* 21 study sites that were located in 15

states. The analytical sample that participated in this analysis was non-Latino White and non-Latino Black. Individuals who identified as Asian, Latino, mixed-race, Native American, or other races were excluded.

The study variables included age, sex, race/ethnicity, parental education, household income, family structure (confounders), parental report or child's depressive symptoms and volume of various cortical structures measured using sMRI (outcome).

Depressive symptoms

Our main independent variable of interest was depressive symptoms reported by the parent, which is also referred to as `asr_scr_depress_t` in the NDA website. This variable is a quantitative (numerical) score, where a higher score indicates more depressive symptoms, that is positively correlated with a history of depression (KSADS), as well as teacher reports of depressive symptoms.

Structural MRI (sMRI)

Structural MRI (sMRI) was performed as described in detail by Casey et al. (2018) available here [26]. In the ABCD study, participants completed a high-resolution T_1 -weighted sMRI scan (1mm isotropic voxels) using scanners from Philips Healthcare (Philips, Andover, Massachusetts, USA), GE Healthcare (General Electric, Waukesha, WI, USA), or Siemens Healthcare (Siemens, Erlangen, Germany). The sMRI data were then processed using FreeSurfer version 5.3.0, available at <http://surfer.nmr.mgh.harvard.edu/> [27-30], according to standard processing pipelines. Processing included removal of nonbrain tissue, segmentation of gray and white matter structures, and cortical parcellation [26]. All scan sessions underwent radiological review, whereby scans with incidental findings were identified. Quality control for the structural images comprised of visual inspections of T_1 images and FreeSurfer outputs for quality [27-30]. The quality review was conducted by the ABCD team. Subjects whose scans failed inspection (due to severe artifacts or irregularities) were excluded. The Desikan-Killiany atlas was used for cortical parcellation [31,32]. Regions of interest (ROIs) included bankssts, caudal anterior cingulate, caudal middle frontal, cuneus, entorhinal, frontal pole, fusiform, inferior parietal, inferior temporal, insula, isthmus cingulate, lateral occipital, lateral orbitofrontal, lingual, medial orbitofrontal, middle temporal, paracentral, parahippocampal, pars opercularis, pars orbitalis, pars triangularis, pericalcarine, postcentral, posterior cingulate, precentral, precuneus, rostral anterior cingulate, rostral middle frontal, superior frontal, superior parietal, superior temporal, supramarginal, temporal pole, and transverse temporal for right and left hemispheres. In this analysis, we used the volumetric data of the cerebral cortex provided by the ABCD data and available for download on the NDA website (<https://nda.nih.gov/abcd>).

Data analysis

Data analysis was performed on ABCD's DEAP Website. DEAP is a platform specifically designed for analysis of the ABCD data. First, we reported frequency (%) and mean (SD) of our variables overall and by race/ethnicity. Then, we compared our racial/ethnic groups for our study variables. Chi-square was used for statistical comparison of non-Latino White and non-Latino Black children. Finally, we applied mixed-effects regression models to test whether parental report of the child's depressive symptoms was associated

with the cortical volume, specifically and separately, for each cortical structure. The independent variable was the parental report of child’s depressive symptoms, measured using Parent Adult Self Report Scores Aseba (ASR). The dependent variable was each structural MRI data (volume), treated as a continuous measure. We tested the assumptions required for multivariable analysis. All our outcomes had a normal distribution. Error terms were also normally distributed, and there was no multi-collinearity between the study measures. Beta and p values were reported for the association between depressive symptoms and each cortical structure volume. These modeling’s were performed using DEAP ROI analysis.

Results

Overall, 10,855 participants entered our analysis. Participants included 8,833 (81.4%) non-Latino White and 2,022 (18.6%) non-Latino Black children. Table 1 describes their demographic, socioeconomic, and depressive symptoms overall and by race. As shown in the table, non-Latino Black children were younger and had less depressive symptoms, reported by parents, than non-Latino White children. Compared to non-Latino White children, non-Latino Black children were from families with lower education, lower-income, and unmarried families.

Table 2 shows the results of mixed-effects regression models, with various volumes of the cortical structures as the outcome, while age, sex, family structure, parental education, and household income were controlled. These models are estimated for overall, as well as separately, for non-Latino White and non-Latino Black children. While parental report or child’s depressive symptoms were associated with cortical

volume in the overall sample, the direction of these associations was highly different across various cortical regions. In addition, the direction of the association between parental report or child’s depressive symptoms, and cerebral cortex regions were different in some regions between non-Latino Black and non-Latino White children. Opposite associations were found for right caudal middle frontal, Isthmus cingulate, lateral orbitofrontal, medial orbitofrontal, middle temporal, paracentral, pericalcarine, supramarginal, temporal pole, superior temporal, postcentral, and transverse temporal regions as well as left bankssts, cuneus, entorhinal, fusiform, inferior temporal, insula, isthmus cingulate, lateral orbitofrontal, medial orbitofrontal, middle temporal, parahippocampal, pericalcarine, rostral middle frontal, superior temporal, supramarginal, Transverse temporal regions. For almost all of these cortical structures, the association between depressive symptoms and cortical volume was negative in non-Latino White but positive for non-Latino Black children (Figure 1).

Discussion

This study tested the association between parental report of child’s depressive symptoms, and cerebral cortex volume in a large national sample of 9/10-year-old children in the U.S. We also explored differences in these associations by cortical structures as well as by race.

While parental report of child’s depressive symptoms was correlated with cerebral cortex volume, this link was not invariant by cortical structure and race. A wide range of racial differences were found in the magnitude and direction of the association between

Table 1: Descriptive Data.

Level	Non-Latino White (NLW)	Non-Latino Black (NLB)	Overall	p
N	N = 8,833	N = 2,022	N = 10,855	
	N(%)	N(%)	N(%)	
Sex				
Female	4088 (46.3)	1008 (49.9)	5096 (46.9)	< 0.001
Male	4745 (53.7)	1014 (50.1)	5759 (53.1)	
Family Structure (Married)				
No	1526 (17.3)	1415 (70.0)	2941 (27.1)	< 0.001
Yes	7307 (82.7)	607 (30.0)	7914 (72.9)	
Parental Education				
< HS Diploma	40 (0.5)	153 (7.6)	193 (1.8)	< 0.001
HS Diploma/GED	259 (2.9)	438 (21.7)	697 (6.4)	
Some College	1650 (18.7)	821 (40.6)	2471 (22.8)	
Bachelor	2827 (32.0)	310 (15.3)	3137 (28.9)	
Post Graduate Degree	4057 (45.9)	300 (14.8)	4357 (40.1)	
Household income				
< 50K	1123 (12.7)	1334 (66.0)	2457 (22.6)	< 0.001
> =50K & < 100K	2732 (30.9)	470 (23.2)	3202 (29.5)	
> =100K	4978 (56.4)	218 (10.8)	5196 (47.9)	
	Mean(SD)	Mean(SD)	Mean(SD)	
Age (Months)	127.37 (13.72)	125.96 (13.00)	127.11 (13.60)	< 0.001
Parental Report of Child Depressive Symptom	54.21 (5.94)	53.72 (6.25)	54.12 (6.00)	< 0.001

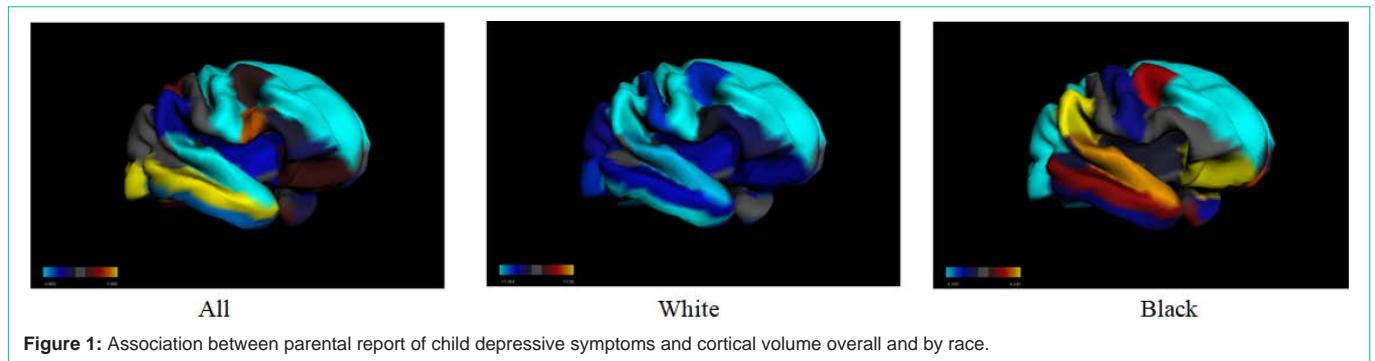
Table 2: Association between parental report of child depressive symptoms and cortical volume overall and by race.

ROI name	All				Non-Latino White (NLW)				Non-Latino Black (NLB)			
	Beta Weights (RH)	Standard Error (RH)	Beta Weights (LH)	Standard Error (LH)	Beta Weights (LH)	Standard Error (LH)	Beta Weights (RH)	Standard Error (RH)	Beta Weights (RH)	Standard Error (RH)	Beta Weights (LH)	Standard Error (LH)
Bankssts	-0.2351	0.822	-1.1823	0.938	-2.4226	1.3434	-0.7034	1.1596	-1.0348	2.0772	0.559	2.2537
Caudal anterior cingulate	1.0819	1.0167	-1.8186	0.995	-2.8451	1.3705	0.2141	1.4093	0.374	2.65	-1.2481	2.6436
Caudal middle frontal	0.6468	2.4793	2.8348	2.4631	-4.1499	3.4434	-8.6442	3.4555	2.1893	6.2093	-1.2314	6.1694
Cuneus	1.2561	1.0721	1.1399	0.9575	-2.3291	1.3351	-2.1728	1.4957	-0.8413	2.6261	1.8693	2.3478
Entorhinal	0.9111	0.6455	0.9782	0.6308	-1.7097	0.8808	-0.2658	0.9174	-0.6071	1.3799	1.6012	1.394
Frontal pole	0.0157	0.3848	-0.0637	0.2956	-0.2977	0.4216	-0.7668	0.5522	-0.586	0.9754	-0.9924	0.7755
Fusiform	-0.986	2.474	-0.8604	2.6313	-9.2005	3.6505	-7.6502	3.4814	-0.9958	6.1183	2.6483	6.55
Inferior parietal	-0.1968	4.0811	-3.1033	3.6401	-7.9546	5.1316	-5.8394	5.7092	-5.4113	10.1383	-3.4726	9.1744
Inferior temporal	-3.066	2.9847	0.1378	3.1592	-10.8577	4.3521	-17.2407	4.116	-1.8991	7.4269	0.14	7.8258
Insula	-2.1787	1.3707	-1.152	1.3318	-7.3157	1.8486	-6.8125	1.9206	-0.6718	3.4093	3.9467	3.459
Isthmus cingulate	0.4691	0.9211	-0.2365	0.9585	-3.4815	1.371	-2.0587	1.3001	0.8796	2.3219	1.2524	2.2647
Lateral occipital	5.5089	3.1352	1.6172	2.9268	-12.071	3.9827	-8.6381	4.2167	-8.4841	7.3461	-7.6646	6.9985
Lateral orbitofrontal	0.989	1.7299	0.836	1.6546	-5.9263	2.2348	-6.98	2.3462	7.4402	4.463	1.0291	4.1529
Lingual	3.5327	1.8613	3.1483	1.9278	-2.0811	2.6614	-1.5145	2.5789	-1.9423	4.5944	-1.6307	4.8581
Medial orbitofrontal	-0.5389	1.1985	-1.2741	1.3304	-5.3198	1.8694	-4.9278	1.6944	4.4186	2.9541	2.768	3.3183
Middle temporal	3.808	2.979	5.1755	2.8441	-5	3.9258	-7.5934	4.0105	1.8952	7.4682	5.4475	7.0663
Paracentral	-2.0266	1.3469	0.5904	1.1475	-0.7133	1.6392	-5.0763	1.9037	2.6498	3.2672	-2.8577	2.7342
Parahippocampal	-0.2122	0.6778	0.8736	0.7147	-1.3313	1.0271	-2.2616	0.9774	-1.1797	1.8037	0.3164	1.6262
Pars opercularis	2.8875	1.4007	-0.3995	1.6882	-7.0936	2.3469	-2.0136	1.9566	-0.2733	3.4002	3.8997	4.2257
Pars orbitalis	-1.0977	0.721	-0.6548	0.5967	-2.5634	0.826	-3.3379	0.9925	-0.3419	1.9114	-0.6238	1.5599
Pars triangularis	-0.6575	1.4632	-0.8486	1.2119	-3.0156	1.715	-4.1584	2.0853	-0.3861	3.592	-1.0332	3.1108
Pericalcarine	0.6275	0.7407	0.4852	0.701	-1.2355	0.9791	-0.8349	1.0208	0.3943	2.0542	1.6852	1.813
Postcentral	0.0544	2.6414	1.0521	2.795	-7.1615	3.8969	-8.8549	3.6853	0.0011	6.597	-8.2148	6.4336
Posterior cingulate	0.9627	1.121	-0.9156	1.0708	-3.5458	1.5135	-1.8703	1.5899	-0.9726	2.761	-1.2514	2.6391
precentral	-7.0037	2.9056	-5.2311	2.9519	-13.4679	4.1095	-14.5931	3.9755	-1.7705	7.4084	-6.6982	7.0012
Precuneus	-1.6731	2.6107	-1.274	2.5034	-13.5602	3.4268	-14.5923	3.5527	-2.7694	6.334	-0.3784	5.9742
Rostral anterior cingulate	3.3212	0.8358	-0.6832	0.9485	-2.8466	1.3283	1.7339	1.1672	4.5549	2.169	-0.0375	2.3993
Rostral middle frontal	-5.6311	4.0785	-5.0191	4.0146	-17.8116	5.6173	-14.9317	5.6292	-6.965	10.8418	6.9284	10.5687
Superior frontal	-7.7304	4.9918	-9.7552	4.9395	-27.2573	6.8235	-27.1277	6.877	-5.8259	12.6918	-5.571	12.4565
Superior parietal	1.5083	3.4415	3.5614	3.4657	-12.0029	4.7744	-13.74	4.6983	-6.5904	8.2741	-4.5065	8.1177
Superior temporal	-4.5765	2.5932	-2.3472	2.7972	-9.0134	3.897	-12.3513	3.5868	3.5918	6.6416	6.6558	7.0944
Supramarginal	-1.8521	3.1172	0.9362	3.3211	-10.7604	4.6496	-13.5125	4.4105	7.7538	7.7448	0.1929	7.8867
Temporal pole	0.6757	0.5879	-0.8975	0.6116	-1.096	0.8668	0.2472	0.8403	-0.5596	1.4622	-1.9584	1.5194
Transverse temporal	-0.4568	0.3426	-0.4178	0.4349	-2.3273	0.6175	-1.5021	0.4819	0.2973	0.819	1.7037	1.0582

parental report of child depressive symptoms, and child cerebral cortical morphometry. Opposite associations were found for right caudal middle frontal, Isthmus cingulate, lateral orbitofrontal, medial orbitofrontal, middle temporal, paracentral, pericalcarine, supramarginal, temporal pole, superior temporal, postcentral, and transverse temporal regions as well as left bankssts, cuneus, entorhinal, fusiform, inferior temporal, insula, isthmus cingulate, lateral orbitofrontal, medial orbitofrontal, middle temporal, parahippocampal, pericalcarine, rostral middle frontal, superior temporal, supramarginal, Transverse temporal regions. For almost

all of these cortical structures, the association between depressive symptoms and cortical volume was negative in non-Latino White but positive for non-Latino Black children.

We found associations between volume of various cortical structures, and parental report of depressive symptoms in 9/10-year-old U.S. children. These associations, however, differed for various cortical structures. Our results expand past research in the field, because past research mainly focused on self-reported depressive symptoms of depression. However, a link between depression and



cortical morphometry is known.

Several areas such as the prefrontal cortex (PFC) showed similar association with parental report or child's depressive symptoms in non-Latino White and non-Latino Black children. Studies have documented early morphological alterations in first-episode untreated depression [24,25]. One study indicated a negative association between cortical thickness of the rostral middle frontal cortex (MFC), and depression severity in untreated patients with first-episode mid-life depression [23]. Some studies have provided evidence of a decline in the volume of the anterior cingulate cortex (ACC) in depression patients [20,21], which may play a role in various affective and cognitive presentations of depression [22]. In general, structural MRI studies have found changes in gray matter volume, cortical thickness, and white matter integrity in frontal and fronto-subcortical regions of individuals with depression that may elucidate some of the deficits in behavioral, emotional, and executive functioning [33]. Further, certain changes in some regions, including anterior cingulate-limbic white matter integrity, and cortical thickness in the right caudal ACC and rostral middle frontal cortex, seem to be involved in estimating symptom severity, symptom improvement patterns, and treatment outcome in adult patients [33].

This is one of the first studies to explore racial variation in associations between volume of various cortical structures, and parental report or child's depressive symptoms in 9/10-year-old U.S. children. The lack of such studies in the current literature is rooted in the taboo nature of the study of race and brain. This taboo increased in the U.S. after Murray published "The Bell Curve," a book that attributed racial variations in IQ to genetic differences [34]. The sociology literature, however, has shown that race is a social-not biological--factor. This means a large proportion of racial variations observed can be explained by different history, environment, opportunity, and other social factors. As we see race as a social factor, we have decided to compare racial groups to better discover how unfairness, discrimination, and racism in society causes race differences. We also see race as a proxy of racism [35,36].

There are very few studies on racial variation in the associations between volume of various cortical structures and parental report or child's depressive symptoms. In a study, racial differences in the association between MDD and frontal pole volume were explored in U.S. children. In a cross-sectional study, we used the ABCD study data that included 10,185 American children between the ages of 9 and 10. Analysis included current MDD (measured using KSADS) as the independent variable, frontal pole volume as the outcome,

and race as the moderator. While MDD was associated with an overall smaller frontal pole volume among children, race showed a statistically significant interaction with MDD on children's frontal pole volume, indicating stronger effects on White children than Black children. We found a steeper inverse association between MDD and frontal pole volume in Black than White children. This meant White children with and without MDD show more similar frontal pole volume, while Black children with and without MDD differ more in their frontal pole volume. However, it is still unknown if the stronger association between MDD and frontal pole volume in Black children is due to a poor access to treatment that results in higher chronicity of MDD in the Black community [37]. Other studies have shown that, due to racism, race alters correlate of brain structures and functions in the U.S [37-41]. As explained elsewhere, these racial variations are due to the sociology of race - not biology [37-41].

Research should test if history and diagnosis, treatment, and outcomes of depression confound with the observed associations here. Follow-up studies of patients with depression have shown alterations of cortical thickness in the opposite directions [33]. While the remission phase may be associated with an increased thickness in some cortical structures, non-remitters show a decrease in cortical thickness [33]. This observation may suggest that treatment response may be linked to some recovery of brain structural abnormalities [33]. In a study of patients with depression receiving antidepressant treatment, only remitters showed cortical thickness increase over the orbitofrontal cortex, rostral middle frontal gyrus (RMFG), inferior temporal gyrus, and increased hippocampal volume [33]. One study showed an increase in orbitofrontal cortex thickness after pharmacotherapy in both remitters and non-remitters [42]. Therefore, the antidepressant-induced structural changes in some frontal areas are linked with antidepressant impacts, or remission itself [33].

Although we only studied cerebral cortex volume, structural and functional correlates of depression are not limited to the cerebral cortex. A wide range of structural brain abnormalities in depression are shown in regions such as the hippocampus, thalamus, and insula [43-45]. Patients with depression show smaller hippocampal volumes, which are involved in memory function [46]. This may likely be because of stress-related processes linked with repeated exposure to stress and depressive symptomatology [47,48]. Likewise, changes in the thalamus and amygdala [45] may play a crucial role in the impaired top-down processes in emotion regulation of negative influence of patients with depression [33]. Moreover, the anterior insula links to the ACC and to the inferior frontal cortex [49] appear

to be linked to cognitive and socio-emotional functioning aspects of depression [50]. Changes in anterior insula are involved in the neurobiological basis of depression [47]. Future research should also study how parental report of depressive symptoms correlate with subcortical structures, and whether race alters such associations.

Future research should also cover white matter, as well as function and functional connectivity across brain structures and networks. Changes in white matter integrity, as measured by diffusion tensor imaging (DTI), have also been found in individuals with depression. One study, for example, reported decreased prefrontal white matter integrity in individuals with depression [51]. Another study identified white matter integrity reduction in the right solitary tract. This means that a potential underpinning mechanism of depression may be a disconnection in the brainstem-amygdala afferent pathway [52]. Reduced white matter integrity in the left superior longitudinal fasciculus, inferior frontal-occipital fasciculus, and corpus callosum have also been found in patients with depression [53]. Similarly, some other neuroimaging studies have reported broad structural brain changes in depressive disorders, including alternation in fronto-limbic and fronto-thalamic pathways [54], volume decline in the hippocampus, and reduced cortical thickness in frontal cortex [11].

The results reported here may have public health and clinical implications. As adolescence is a period of enormous neurodevelopmental change [55], where the risk of depression is the highest [7], an understanding of the structural brain correlates of depression in adolescence is important. Our study provides additional insight on racial/ethnic variations in sMRI correlates of depressive symptoms. However, it is still unknown if these correlates vary by context and SES.

We found that PRCDS differently correlates with cortical volume in non-Latino White and non-Latino Black children. Research has shown racial differences in correlations between depression and socioeconomic status, stress, social support, obesity, substance use, health, chronic disease, and life expectancy [56-62]. In two studies, stress differently predicted depression of Black and White individuals [59,60]. In other studies, financial difficulty showed differential associations with depression of Black and White individuals [62-64]. These observations may explain why we observe racial variations in the link between depression and cortical volume between non-Latino White, and non-Latino Black children.

This study had a few limitations. First, we only studied cortical structures, and no sub-cortical structures were included. Second, we only studied cortical volume; surface area and cortical thickness were not included. We also did not include functional connectivity or functional aspects of the cortical structures. The design was cross-sectional, so no causal associations could be inferred. We only included child's depressive symptoms as reported by the parent. We did not include history of major depression, history of depression treatment, or depression in parents. We also did not include a wide range of confounders, such as nutrition, exercise, and environment. Despite these limitations, this study is the first step to test how race alters structural correlates of depression.

Conclusion

We found associations between parental report or child's

depressive symptoms and child cerebral cortical morphometry. However, the magnitudes and directions of these associations differed across cortical structures. We also found that race alters the association between parental report or child's depressive symptoms and child cerebral cortical morphometry. Racial differences were mostly due to a positive association for non-Latino Black children, while the associations were almost always negative for non-Latino White children. Racial differences in the association between parental report or child's depressive symptoms and child cerebral cortical morphometry, in non-Latino Black and non-Latino White children, invites researchers to explore the role of repeated stress, trauma, and adversity in contributing to such differences. Research should also test if non-Latino Black communities' lower access to depression diagnosis and treatment explains racial variations in brain correlates of PRCDS by race/ethnicity.

Acknowledgements

Publicly available data were used from the NDA website. Data used in the preparation of this article were obtained from the ABCD Study, held in the National Institutes of Mental Health Data Archive. The ABCD study is supported by awards U01DA041022, U01DA041028, U01DA041048, U01DA041089, U01DA041106, U01DA041117, U01DA041120, U01DA041134, U01DA041148, U01DA041156, U01DA041174, U24DA041123, and U24DA041147 from the NIH and other federal partners. A full list of supporters is available at <https://abcdstudy.org/feds-eral-partners.html>. The ABCD data used in this report came from DOI:10.15154/1504041. Shervin Assari was supported by the grants with the numbers CA201415 02, DA035811-05, U54MD007598, U54MD008149, D084526-03, and U54CA229974 by the National Institutes of Health (NIH).

References

1. Kessler RC, Berglund P, Demler O, Jin R, Merikangas KR, Walters EE. Lifetime prevalence and age-of-onset distributions of DSM-IV disorders in the National Comorbidity Survey Replication. *Archives of general psychiatry*. 2005; 62: 593-602.
2. Greenberg PE. *The Economic Burden of Adults with Major Depressive Disorder in the United States*. 2014.
3. James SL, Abate D, Abate KH, Abay SM, Abbafati C, Abbasi N, et al. Global, regional, and national incidence, prevalence, and years lived with disability for 354 diseases and injuries for 195 countries and territories, 1990-2017: A systematic analysis for the Global Burden of Disease Study 2017. *The Lancet*. 2018; 392: 1789-1858.
4. Thompson SM, Kallarackal AJ, Kvarta MD, Van Dyke AM, LeGates TA, Cai X. An excitatory synapse hypothesis of depression. *Trends in neurosciences*. 2015; 38: 279-294.
5. Gartlehner G, Hansen RA, Morgan LC, Thaler K, Lux L, Van Noord M, et al. Comparative benefits and harms of second-generation antidepressants for treating major depressive disorder: an updated meta-analysis. *Annals of internal medicine*. 2011; 155: 772-785.
6. Gaynes BN, Warden D, Trivedi MH, Wisniewski SR, Fava M, Rush AJ. What did STAR* D teach us? Results from a large-scale, practical, clinical trial for patients with depression. *Psychiatric services*. 2009; 60: 1439-1445.
7. Thapar A, Collishaw S, Pine DS, Thapar AK. Depression in adolescence. *The Lancet*. 2012; 379: 1056-1067.
8. Shen X, Reus LM, Cox SR, Adams MJ, Liewald DC, Bastin ME, et al. Subcortical volume and white matter integrity abnormalities in major depressive disorder: findings from UK Biobank imaging data. *Scientific reports*. 2017; 7: 1-10.
9. Shen X, Adams MJ, Ritakari TE, Cox SR, McIntosh AM, Whalley HC. White

- matter microstructure and its relation to longitudinal measures of depressive symptoms in mid-and late life. *Biological psychiatry*. 2019; 86: 759-768.
10. Schmaal L, Pozzi E, Ho TC, Van Velzen LS, Veer IM, Opel N, et al. ENIGMA MDD: seven years of global neuroimaging studies of major depression through worldwide data sharing. *Translational psychiatry*. 2020; 10: 172.
 11. Schmaal L, Hibar D, Sämann PG, Hall G, Baune B, Jahanshad N, Cheung J, et al. Cortical abnormalities in adults and adolescents with major depression based on brain scans from 20 cohorts worldwide in the ENIGMA Major Depressive Disorder Working Group. *Molecular psychiatry*. 2017; 22: 900-909.
 12. Fowler AM. A molecular approach to breast imaging. *Journal of Nuclear Medicine*. 2014; 55: 177-180.
 13. James ML, Gambhir SS. A molecular imaging primer: modalities, imaging agents, and applications. *Physiological reviews*. 2012; 92: 897-965.
 14. Blamire A. The technology of MRI-the next 10 years? *The British journal of radiology*. 2008; 81: 601-617.
 15. Han K-M, Choi S, Jung J, Na K-S, Yoon H-K, Lee M-S, Ham B-J. Cortical thickness, cortical and subcortical volume, and white matter integrity in patients with their first episode of major depression. *Journal of affective disorders*. 2014; 155: 42-48.
 16. Reynolds S, Carrey N, Jaworska N, Langevin LM, Yang X-R, MacMaster FP. Cortical thickness in youth with major depressive disorder. *BMC psychiatry*. 2014; 14: 1-8.
 17. Grieve SM, Korgaonkar MS, Koslow SH, Gordon E, Williams LM. Widespread reductions in gray matter volume in depression. *NeuroImage: Clinical*. 2013; 3: 332-339.
 18. Lu X, Zhong Y, Ma Z, Wu Y, Fox PT, Zhang N, et al. Structural imaging biomarkers for bipolar disorder: Meta-analyses of whole-brain voxel-based morphometry studies. *Depression and anxiety*. 2019; 36: 353-364.
 19. Depping MS, Wolf ND, Vasic N, Sambataro F, Thomann PA, Wolf RC. Specificity of abnormal brain volume in major depressive disorder: a comparison with borderline personality disorder. *Journal of affective disorders*. 2015; 174: 650-657.
 20. Lai C-H. Gray matter volume in major depressive disorder: a meta-analysis of voxel-based morphometry studies. *Psychiatry Research: Neuroimaging*. 2013; 211: 37-46.
 21. Bora E, Fornito A, Pantelis C, Yücel M. Gray matter abnormalities in major depressive disorder: a meta-analysis of voxel based morphometry studies. *Journal of affective disorders*. 2012; 138: 9-18.
 22. Ramirez-Mahaluf JP, Perramon J, Otal B, Villoslada P, Compte A. Subgenual anterior cingulate cortex controls sadness-induced modulations of cognitive and emotional network hubs. *Scientific reports*. 2018; 8: 1-16.
 23. Qiu L, Lui S, Kuang W, Huang X, Li J, Zhang J, et al. Regional increases of cortical thickness in untreated, first-episode major depressive disorder. *Translational psychiatry*. 2014; 4: e378.
 24. Lai C-H, Wu Y-T. Frontal-insula gray matter deficits in first-episode medication-naïve patients with major depressive disorder. *Journal of affective disorders*. 2014; 160: 74-79.
 25. Lai C-H, Wu Y-T. The gray matter alterations in major depressive disorder and panic disorder: putative differences in the pathogenesis. *Journal of affective disorders*. 2015; 186: 1-6.
 26. Casey B, Cannonier T, Conley MI, Cohen AO, Barch DM, Heitzeg MM, et al. The adolescent brain cognitive development (ABCD) study: imaging acquisition across 21 sites. *Developmental cognitive neuroscience*. 2018; 32: 43-54.
 27. Zhong J, Phua DY, Qiu A. Quantitative evaluation of LDDMM, FreeSurfer, and CARET for cortical surface mapping. *Neuroimage*. 2010; 52: 131-141.
 28. Fischl B. FreeSurfer. *Neuroimage*. 2012; 62: 774-781.
 29. Cardinale F, Chinnici G, Bramerio M, Mai R, Sartori I, Cossu M, et al. Validation of FreeSurfer-estimated brain cortical thickness: comparison with histologic measurements. *Neuroinformatics*. 2014; 12: 535-542.
 30. Desikan RS, Ségonne F, Fischl B, Quinn BT, Dickerson BC, Blacker D, et al. An automated labeling system for subdividing the human cerebral cortex on MRI scans into gyral based regions of interest. *Neuroimage*. 2006; 31: 968-980.
 31. Hagler DJ Jr., Hatton S, Cornejo MD, Makowski C, Fair DA, Dick AS, et al. Image processing and analysis methods for the Adolescent Brain Cognitive Development Study. *Neuroimage*. 2019; 202: 116091.
 32. Zhang K, Zhu Y, Zhu Y, Wu S, Liu H, Zhang W, et al. Molecular, functional, and structural imaging of major depressive disorder. *Neuroscience bulletin*. 2016; 32: 273-285.
 33. Herrnstein RJ, Murray C. *The bell curve: Intelligence and class structure in American life*: Simon and Schuster. 2010.
 34. Bailey ZD, Krieger N, Agenor M, Graves J, Linos N, Bassett MT. Structural racism and health inequities in the USA: evidence and interventions. *Lancet*. 2017; 389: 1453-1463.
 35. Bassett MT, Krieger N, Bailey Z. Charlottesville: blatant racism, not grievances, on display. *Lancet*. 2017; 390: 2243.
 36. Assari S. Racial Variation in the Association between Childhood Depression and Frontal Pole Volume among American Children. *Res Health Sci*. 2020; 5: 121-140.
 37. Assari S. Race, Ethnicity, Family Socioeconomic Status, and Children's Hippocampus Volume. *Res Health Sci*. 2020; 5: 25-45.
 38. Assari S. Parental Education, Household Income, and Cortical Surface Area among 9-10 Years Old Children: Minorities' Diminished Returns. *Brain Sci*. 2020; 10.
 39. Assari S. Neighborhood Poverty and Amygdala Response to Negative Face. *J Econ Public Financ*. 2020; 6: 67-85.
 40. Assari S, Curry TJ. Parental Education Ain't Enough: A Study of Race (Racism), Parental Education, and Children's Thalamus Volume. *J Educ Cult Stud*. 2021; 5: 1-21.
 41. Järnum H, Eskildsen SF, Steffensen EG, Lundbye-Christensen S, Simonsen CW, Thomsen IS, et al. Longitudinal MRI study of cortical thickness, perfusion, and metabolite levels in major depressive disorder. *Acta Psychiatrica Scandinavica*. 2011; 124: 435-446.
 42. Malykhin N, Coupland N. Hippocampal neuroplasticity in major depressive disorder. *Neuroscience*. 2015; 309: 200-213.
 43. Hagan CC, Graham JM, Tait R, Widmer B, van Nieuwenhuizen AO, Ooi C, et al. Adolescents with current major depressive disorder show dissimilar patterns of age-related differences in ACC and thalamus. *NeuroImage: Clinical*. 2015; 7: 391-399.
 44. Price JL, Drevets WC. Neurocircuitry of mood disorders. *Neuropsychopharmacology*. 2010; 35: 192-216.
 45. Turner AD, Furey ML, Drevets WC, Zarate Jr C, Nugent AC. Association between subcortical volumes and verbal memory in unmedicated depressed patients and healthy controls. *Neuropsychologia*. 2012; 50: 2348-2355.
 46. Stratmann M, Konrad C, Kugel H, Krug A, Schöning S, Ohrmann P, et al. Insular and hippocampal gray matter volume reductions in patients with major depressive disorder. *PLoS one*. 2014; 9: e102692.
 47. Warner-Schmidt JL, Duman RS. Hippocampal neurogenesis: opposing effects of stress and antidepressant treatment. *Hippocampus*. 2006; 16: 239-249.
 48. Cauda F, D'agata F, Sacco K, Duca S, Geminiani G, Vercelli A. Functional connectivity of the insula in the resting brain. *Neuroimage*. 2011; 55: 8-23.
 49. Stephani C, Vaca GF-B, Maciunas R, Koubeissi M, Lüders HO. Functional neuroanatomy of the insular lobe. *Brain Structure and Function*. 2011; 216: 137-149.
 50. Li L, Ma N, Li Z, Tan L, Liu J, Gong G, et al. Prefrontal white matter abnormalities in young adult with major depressive disorder: a diffusion tensor imaging study. *Brain research*. 2007; 1168: 124-128.

51. Song YJC, Korgaonkar MS, Armstrong LV, Eagles S, Williams LM, Grieve SM. Tractography of the brainstem in major depressive disorder using diffusion tensor imaging. *PLoS One*. 2014; 9: e84825.
52. Ota M, Noda T, Sato N, Hattori K, Hori H, Sasayama D, et al. White matter abnormalities in major depressive disorder with melancholic and atypical features: a diffusion tensor imaging study. *Psychiatry and clinical neurosciences*. 2015; 69: 360-368.
53. Van Velzen LS, Kelly S, Isaev D, Aleman A, Aftanas LI, Bauer J, et al. White matter disturbances in major depressive disorder: a coordinated analysis across 20 international cohorts in the ENIGMA MDD working group. *Molecular psychiatry*. 2020; 25: 1511-1525.
54. Tamnes CK, Herting MM, Goddings A-L, Meuwese R, Blakemore S-J, Dahl RE, et al. Development of the cerebral cortex across adolescence: a multisample study of inter-related longitudinal changes in cortical volume, surface area, and thickness. *Journal of Neuroscience*. 2017; 37: 3402-3412.
55. Assari S, Lankarani MM. Race and Ethnic Differences in the Associations between Cardiovascular Diseases, Anxiety, and Depression in the United States. *Int J Travel Med Glob Health*. 2014; 2: 107-113.
56. Lankarani MM, Assari S. Association between number of comorbid medical conditions and depression among individuals with diabetes; race and ethnic variations. *J Diabetes Metab Disord*. 2015; 14: 56.
57. Assari S. Race and Ethnic Differences in Additive and Multiplicative Effects of Depression and Anxiety on Cardiovascular Risk. *Int J Prev Med*. 2016; 7: 22.
58. Assari S, Lankarani MM. Association between Stressful Life Events and Depression; Intersection of Race and Gender. *J Racial Ethn Health Disparities*. 2016; 3: 349-356.
59. Assari S, Lankarani MM. Stressful Life Events and Risk of Depression 25 Years Later: Race and Gender Differences. *Front Public Health*. 2016; 4: 49.
60. Assari S. Social Determinants of Depression: The Intersections of Race, Gender, and Socioeconomic Status. *Brain Sci*. 2017; 7.
61. Assari S. Race, Depression, and Financial Distress in a Nationally Representative Sample of American Adults. *Brain Sci*. 2019; 9.
62. Assari S. Subjective financial status and suicidal ideation among American college students: Racial differences. *Arch Gen Intern Med*. 2019; 3: 16-21.
63. Evans MC, Bazargan M, Cobb S, Assari S. Mental and Physical Health Correlates of Financial Difficulties Among African-American Older Adults in Low-Income Areas of Los Angeles. *Front Public Health*. 2020; 8: 21.