

Case Report

Status: Thinking Outside the Box

Galeotti S^{1*}, Fiore NM¹, Beckwith-Fickas K², Eapen S² and Sultan R³

¹Department of Pediatrics, K. Hovnanian Children's Hospital at Jersey Shore University Medical Center, USA

²Division of Pediatric Endocrinology, USA

³Division of Pediatric Neurology, USA

*Corresponding author: Sara Galeotti, Department of Pediatrics, K. Hovnanian Children's Hospital at Jersey Shore University Medical Center, Neptune, NJ, USA

Received: June 29, 2020; Accepted: July 22, 2020;

Published: July 29, 2020

Introduction

Hashimoto Encephalopathy (HE) is a rare, serious, but reversible illness. It presents in one of two ways, with each presentation having overlapping symptomatology with each other. All organic causes of Encephalopathy must be ruled out before a definitive diagnosis can be made.

Objectives

After reading this article, readers should be able to:

1. Define Encephalopathy vs Encephalitis
2. Differential diagnosis of Toxic Metabolic Encephalopathy (TME)
3. Hashimoto Encephalopathy (HE)

Clinical Case

15-year-old female with history of Hashimoto thyroiditis, polyarticular joint pain, and chronic migraines presents with status epilepticus and altered mental status. Patient was seen by neurology in June of 2019 because of an event at school where she had sudden numbness in her right arm and the right side of her face. She reported having a left-sided throbbing headache. She had changes in her speech which lasted 4-5 hours. She was brought to the emergency room by which time her headache had resolved. During the time of her admission, she had a significant work up for Transient Ischemic Attack (TIA), including a brain MRI, MRA, Echocardiogram, EEG and a coagulation work up -- all of which were within normal limits. After this event resolved, her mother subsequently noted a gradual decline in her overall cognitive function.

Additionally, as per her mother's report, her daughter had slow changes in personality in the months before this, becoming more easily agitated and progressively forgetful. Academically, her grades significantly dropped from A's to C's and teachers were calling the home concerned about the patient's welfare due to her increasingly odd behavior. She would leave an exam thinking she had done well and then would be surprised to learn she had failed. Her tutors reported to her mother that the patient's logic was tangential and difficult to follow. She was a competitive dancer since the age of two and while at a dance competition over the summer, she was unable to

complete her routine and walked off the stage after forgetting her next steps. The patient was admitted to the Pediatric Intensive Care Unit (PICU) after she presented in status epilepticus in August of 2019. On the day of admission, the patient was in the back of a moving vehicle, listening to music, when her mother noticed that she stopped talking, turned her head to the right, and started convulsing. She had associated excessive drooling, urinary incontinence, gray appearance, and perioral cyanosis. She was not able to provide a verbal or physical response to questions. Mother reported no recent fevers or recent illnesses.

Upon arrival to the ED, the patient was in status epilepticus refractory to Ativan and a Keppra boluses. The patient was given Versed, which subsequently stopped seizure activity, and she was intubated. She was immediately taken for CT scan (brain), and admitted to PICU.

Initial Workup Included

Complete blood count showed a slightly elevated white blood cell count of 15.5 and low platelets of 87, 4 bands with 88% neutrophil predominance. Complete metabolic panel was normal. Venous blood gas was consistent with metabolic acidosis. Urinalysis and urine culture was within normal limits. Urine drug screen: positive for Benzodiazepine after versed and ativan given. Cerebrospinal fluid studies: Protein was high at 138 mg/dl, glucose was high at 80 mg/dl, red blood cells 0, white blood cells 1, no oligoclonal bands or xanthochromia. Culture was negative. Chest x-ray: no cardiopulmonary disease. Brain CT scan: Unremarkable. Video Electroencephalogram (vEEG) was placed for 5 days. Initial results revealed severe diffuse slowing (Figure 1 & Figure 2) that improved throughout her hospital stay. No clinical or electrographic seizures were recorded.

Subsequent Workup

MRI brain: small venous anomaly of likely no clinical significance. Thyroid-stimulating hormone and Free T4: within normal limits. Thyroid Peroxidase antibody 980.3 (range 0-9 IU/mL); Markedly elevated. Rheumatologic workup was extensive and non-contributory which included but was not limited to exclusion of Lupus, autoimmune encephalitis, and Lyme disease

Consults

Neurology, Endocrinology, Rheumatology.

Because she met diagnostic criteria for Hashimoto Encephalopathy and after exclusion of other causes for her symptomatology, treatment was initiated with high dose corticosteroids. Patient was extubated and transitioned to room air. Her mental status post extubation remained impaired. She had a long processing time, anomia, and she had gait disturbance that remained throughout her hospital stay. She was discharged home and followed closely with neurology and endocrinology. It took several months for her to completely return to her baseline functioning.

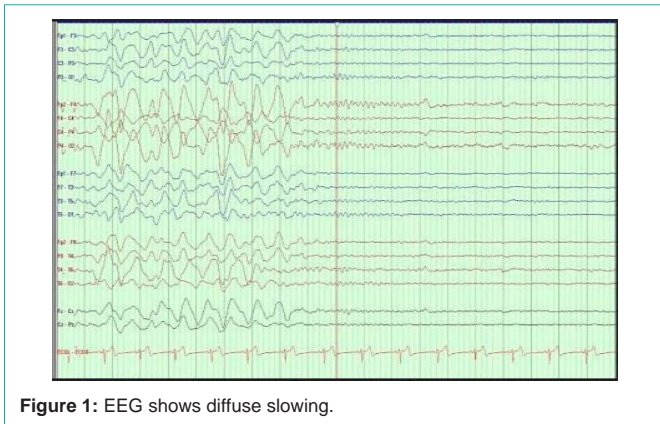


Figure 1: EEG shows diffuse slowing.

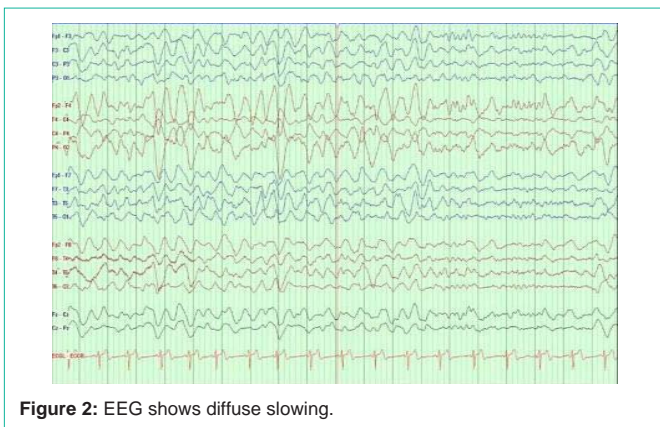


Figure 2: EEG shows diffuse slowing.

Discussion

The distinction between encephalopathy and encephalitis is an important one. This article will discuss encephalopathy as defined by brain disease that alters brain function and/or structure. It may be transient, recurrent or permanent. It may manifest as confusion, disorientation or behavior changes, can cause altered mental status and lead to coma. It may or may not have associated inflammation of brain tissue. Encephalitis is an umbrella term for inflammation of brain tissue that encompasses a variety of signs and symptoms ranging from infectious meningitis to psychiatric disturbances to generalized seizures caused by many different pathological processes. It is therefore important to narrow the list of differential diagnoses based on acute, chronic or acute on chronic symptoms. Common etiologies include but are not limited to: electrolyte imbalances, hypertension, infection, hepatorenal function, paraneoplastic syndromes and autoimmune causes. [Fiore, et al.]

Acute Toxic-Metabolic Encephalopathy (TME) is a condition of acute global cerebral dysfunction manifested by altered consciousness, behavior changes and/or seizures in the absence of primary structural brain disease or direct CNS infection. TME is often reversible and interruption of neuronal activity in the developing brain can have long-lasting effects, therefore prompt identification and resolution are important.

Hashimoto Encephalopathy (HE) is a rare, serious, but reversible illness. With an estimated prevalence of 2.1 per 100,000 patients with unexplained neurological symptoms, the disease is often under

diagnosed and underreported. It commonly affects more females than males with average age of onset being 56 years, but can present between 9 - 78 years. [Fiore, et al.]

HE can present in one of two ways; the first being a “stroke-like” pattern of multiple recurrent focal neurologic deficits with a variable degree of cognitive dysfunction and alteration of consciousness. Twenty-five percent of patients present in this manner. The second pattern is a diffuse progressive pattern characterized by slow progressive cognitive impairment with confusion, hallucinations, somnolence or dementia. Our patient was unique in presenting with both an initial TIA picture and subsequent slow cognitive decline.

Both presentations will have some symptomatology in common. Approximately 2/3 of patients will have tonic-clonic seizures, 12% will present with status epilepticus. In up to 38% of patients tremors/myoclonus will be present. Psychosis and hallucinations have been reported in 25-36% of patients. On neurological examination, the most common findings are changes in mental status associated with hyperreflexia.

Thyroid hormone levels vary from subclinical hypothyroid to overt hyperthyroid and most patients are euthyroid at presentation. As was seen in our patient, protein in the cerebrospinal fluid is often elevated. They can also have lymphocytic pleocytosis and normal glucose. Patients who have an MRI done, may have diffuse white matter changes, suggestive of primary demyelination. On EEG, patients have nonspecific slowing of background activity, however 90-98% of patients will show nonspecific EEG changes, consistent with the EEG pattern of our patient. There are varying reports of EEG resolution after treatment with some reports showing a rapid resolution and some showing a slower resolution of EEG changes.

“There are three essential features that must be present in order to diagnose Hashimoto encephalopathy; altered consciousness with reduced wakefulness, attention, or cognitive function, no CSF evidence of bacterial or viral infection; and high serum concentration (or titer) of antithyroid microsomal, antithyroid peroxidase, or antithyroglobulin antibodies.” [Fiore, et al.] Once diagnosed, the patient should respond quickly to therapy. Of note antithyroid antibodies may or may not decrease following treatment and are not followed routinely.

Treatment

The mainstay of treatment is oral prednisone ranging from 50-150 mg daily. Since steroid responsive encephalopathy associated with autoimmune thyroiditis is rare, there are not enough patients to reach a conclusion on a “typical” duration of treatment. The duration of treatment is tapered according to individual patient response. Sometimes a short course of 10 to 30 days of steroid therapy is all that is needed and at other times the treatment can last at least 6 months.

If there is a thyroid hormone imbalance, it should be treated. If patients are not responsive to or cannot tolerate corticosteroid treatment, patients can be treated with immunosuppressive medications.

Conclusion

This is a case of a 15-year-old female with a history of Hashimoto’s thyroiditis, polyarticular joint pain, and chronic migraines, who

presented initially with signs and symptoms of a TIA. After two months of steady cognitive decline, the patient presented in Status Epilepticus and was found to have Hashimoto Encephalopathy. After a course of high dose corticosteroid treatment (weaned over a course of 13 weeks), her symptoms resolved and cognitive function back to baseline.

References

1. Fiore AA, Pfeiffer WB, Rizvi SAA, Cortes A, Ziembinski C and Pham R, et al. May 16 2018. Hashimoto Encephalopathy as a Complication of Autoimmune Thyroiditis. 2019; 28: 91-95.
2. Payer J, Petrovic T, Lisy L and Langer P. Hashimoto Encephalopathy: A Rare Intricate Syndrome. *Int J Endocrinol Metab.* 2012; 10: 506-514.
3. Wilcox RA, To T, Koukourou A and Frasca J. Hashimoto's encephalopathy masquerading as acute psychosis. *Journal of Clinical Neuroscience.* 2008; 15: 1301-1304.