

Case Report

A Rare Case of Thyroid Abscess Associated with Thyrotoxicosis in a Child

Puthiyachirakkal M*, Sanalkumarn and Persaudr
Departments of Pediatrics, Endocrinology and ENT, Al Zahra Hospital, United Arab Emirates

***Corresponding author:** Mohammed Ashraf Puthiyachirakkal, Departments of Pediatrics, Endocrinology and ENT, Al Zahra Hospital, United Arab Emirates

Received: November 28, 2017; **Accepted:** December 22, 2017; **Published:** December 29, 2017

Abstract

Thyroid abscess associated with thyrotoxicosis is a rare condition in children. This is because the thyroid gland is relatively resistant to infection because of its high blood supply, thick fibrous capsule and its high iodine content. We present a unique case of a thyroid abscess caused by *Eikenella Corrodens* in a 3 year 4 month old boy. He had severe anemia, thrombocytosis and thyrotoxicosis. He was treated with antibiotics, atenolol, steroid and incision and drainage. He recovered completely without any complication. This potentially life threatening complication of thyroid gland infection, if treated promptly may recover without any sequel. These patients should be followed up to monitor the thyroid function for the subsequent development of hypothyroidism due to massive destruction of the gland.

Keywords: Suppurative Thyroiditis thyroid abscess; *Eikenella corrodens*; Thyrotoxicosis

Introduction

Acute Suppurative Thyroiditis (AST) resulting from bacterial infection is rare in children, but it's a potentially life threatening disease because of its close proximity to the trachea [1]. The diagnosis of AST is often delayed due to rarity of the condition [2]. The incidence of AST and thyroid abscess is estimated be 0.1-0.7% of surgically treated thyroid pathologies [2], if left untreated AST may result in 12% of higher mortality [3]. We report a case of thyroid abscess in a young child who was presented with fever of 2 weeks duration.

Case Report

A 3 year 4 month old male child was admitted with the complaints of fever of 14 days, cough and neck swelling for 3 days duration. He was seen in emergency department 10 days prior, for fever and cough and received antipyretics and antibiotics for 5 days. The neck swelling was noticed 3 days before admission which was gradually progressing. The cough was nonproductive and had noisy breathing noticed a day prior to the admission. No history of recurrent infections in the past or contact with tuberculosis. No history of travel outside the country. Past history was significant for eczema and few episodes of wheezing. Immunization was up to date. On physical examination, he was thin built, he weighed 11.35 kg (<5th canticle) with a height of 94 cm (25th canticle). The vitals showed temperature of 38.3°C, pulse rate 110/minute, respiratory rate 30/minute without any distress and Oxygen saturation of 97%. A firm and tender swelling of size 5 cm x 6 cm was noticed in the neck on the left side of trachea below the cricoids which moved upon swallowing. No redness over the swelling was noted. There were 2 cervical nodes of 0.5 cm each on both sides of the neck in the posterior cervical region. Throat was normal. The chest had conducted sounds and examinations of other systems were within normal limits (Table 1). The ultrasound (USG) neck (Figure 1) showed cystic swelling of size 3.2 cm x 2.2 cm x 2 cm, with thick capsule in the left lobe and isthmus of thyroid. The chest was normal except for tracheal deviation to right. CT scan

(Figures 2 & 3) showed large cystic swelling involving left lobe, isthmus and part of superior pole of right thyroid gland. Technetium 99 thyroid isotope scan showed very low uptake in the thyroid gland, consistent with destructive thyroiditis. The child was started oceftriaxone and vancomycin and Metronidazole. The child was started on oceftriaxone, vancomycin and Metronidazole. Atenolol was started for mild tachycardia. The patient received dexamethasone injection for tracheal compression, which was later changed to oral prednisolone for quick control of thyrotoxicosis. Low dose aspirin was started for very high platelet count. The fever subsided after 1

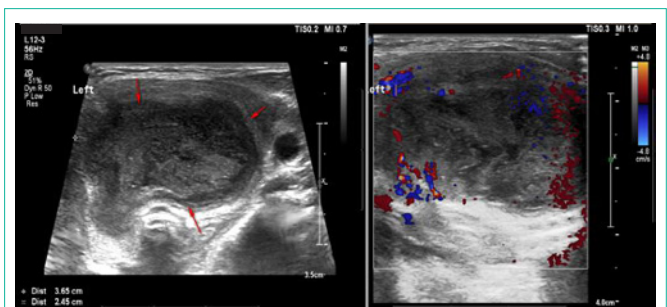


Figure 1: USG Neck showing thyroid abscess.

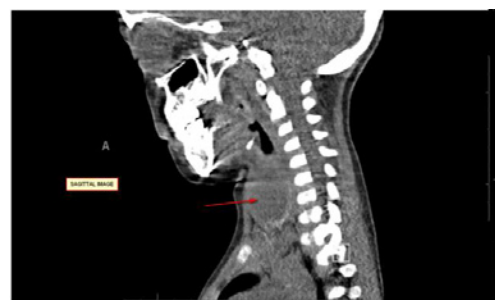
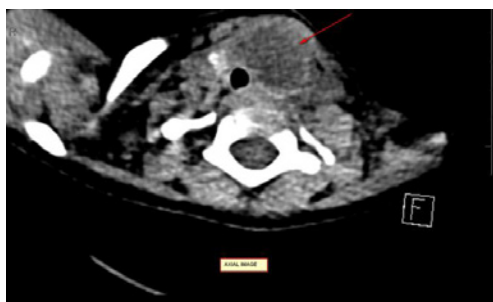
Figure 2: CT scan neck axial and sagittal view showing abscess.

Table 1: Initial lab results.

Initial Lab Results			
1	Hb/HCT	6.7 g/dl/21.5%	Low
2	MCV	67.4 fl	Low
3	RDW	16.60%	High
4	WBC	Total WBC- 19.2 x10 ⁹ /L	Neutrophilic leukocytes
		Polymorphs- 72.6%	
		Lymphocytes- 13.7%	
		Monocytes 13.3 %	
5	Platelets	725 x10 ⁹ /L	Thrombocytosis
		Repeat- 1123 x10 ⁹ /L	
6	CRP	159.5 mg/dl	High
7	Ferritin	717.57 µg/L	High
8	Serum iron	3.3 µm/L	Low
9	LDH	318 U/L	Elevated
10	TFT	Free T4-45.05 pmol/L	Thyrotoxicosis
		Free T3- 8.93 pmol/L	
		TSH-0.003 mIU/L	
11	Peripheral Smear	Leukocytes with shift to left, hypochromia, microcytosis, anisocytosis and thrombocytosis	
12	Blood Culture	Negative	

(Hb- Hemoglobin, HCT- Hematocrit, RDW- Red Cell Distribution Width, MCV- Mean Corpuscular Volume, CRP- C-Reactive Protein, LDH – Lactate dehydrogenase, TFT- Thyroid Function Test)

**Figure 3:** CT scan neck axial and sagittal view showing abscess.

day of antibiotic treatment, but thyroid USG repeated after 5 days of antibiotics showed slightly increased collection of pus. So, decision was made to do surgical drainage under general anesthesia. The patient received PRBC transfusion before the procedure. 10 ml of pus was removed by incision and drainage. A drain was inserted during the procedure which was removed 2 days later. The culture of the fluid grew *Eikenella Corrodens*, sensitive to ceftriaxone. The patient improved symptomatically and antibiotics were discontinued and the patient was discharged 3 days after the procedure. Steroids were tapered and stopped 1 week post discharge. The child was reviewed 1 week later and was clinically well. The Repeat CBC showed normal WBC, Hb 10.5 g/dl, platelets 507 x10⁹/L, ESR-22 mm/hr, CRP- 0.5 mg/L. The repeat free T4 was normal 13.4 p mol/L, free T3- 5.45 pmol/L and TSH- 1.86 m IU/L.

Discussion

We report a case of thyroid abscess due to *Eikenella Corrodens*. The patient also had thyrotoxicosis, iron deficiency anemia and

thrombocytosis. Thyrotoxicosis is an unusual finding in AST and is more often seen in sub acute thyroiditis of viral etiology [4,5]. Low uptake thyroid scan in our patient suggested that the thyrotoxicosis is due to an inflammatory or destructive process in the thyroid gland. He was given low dose atenolol and glucocorticoids to facilitate quick control of thyrotoxicosis. Thrombocytosis in our patient may be due to iron deficiency and from infection. Our patient had microcytic anemia with low RBC count and low iron suggestive of iron deficiency. Reactive thrombocytosis is also seen in variety of condition including infection [5]. The decline in platelet count after abscess drainage indicates that the thrombocytosis was partly due to infection.

Abscess in the thyroid gland is an unusual cause of head and neck infection in children [6]. Thyroid gland is resistant to infection because of its thick fibrous capsule, generous vascularity, good lymphatic drainage and the presence of large amount of iodine in the gland. AST may follow acute upper respiratory tract infection or otitis media and very rarely by hematogenous spread. The predisposing factors include left pyriform sinus fistula, thyroglossal duct remnant, congenital branchial fistula, blunt trauma and immunocompromised states such as HIV infection or cancer chemotherapy. Other rare predisposing factors include tooth abscess, infective endocarditic, fine needle aspiration, goiter and adenoma [6,7]. Persistence of pyriform sinus fistula, which extends from pharynx to the thyroid, is most common underlying abnormality responsible for recurrent suppurative thyroiditis [8]. The presence of fistula facilitates the entry of bacteria associated with upper respiratory tract infection to the thyroid gland. The left lobe is more often involved than the right [8,9].

Etiology

Acute suppurative thyroiditis and abscess are caused by bacteria.

Viruses usually cause sub acute thyroiditis. Staphylococcus aureus, staphylococcus epidermoid, streptococcus progenies, streptococcus pneumonia are the common organism causing AST. Other organisms include salmonella, klebsiella, bactericides, Treponema pallidum, *pasteurella* spp, Eikenella, gram negative anaerobic bacilli (eg, Prevotella, Porphyromonas, and Fusobacteria) and mycobacterium tuberculosis. Eikenella Corrodens, a facultative gram negative anaerobe is a normal inhabitant of the upper respiratory tract that has been reported as the etiologic agent in head and neck abscesses. Multiple organisms are reported in some cases. Fungi like Aspergillus species, Coccidioides immitis, Cryptococcus neoformans, Histoplasma capsulatum, Candida species are also reported as cause of suppurative thyroiditis. Pneumocystis carini thyroiditis is seen in HIV infected patients or those with underlying malignancy [10-14,17].

Clinical Manifestations

The patients usually present with fever and neck pain. Preceding upper respiratory tract infection may be present in some cases. Other features include cough, dysphonia, dysphagia, stridor and neck swelling. The pain worsens on extension of the neck [1,7]. Most often the swelling is noticed on left side. The tender swelling moves with swallowing. Cervical lymphadenopathy may be seen [1,7,15]. Most patients with AST are euthyroid. Thyrotoxicosis is a rare feature of AST. In one review, thyrotoxicosis was reported in 11.3% of cases and hypothyroidism in 17% of cases with suppurative thyroiditis. The thyrotoxicosis is due to the release of preformed thyroid hormone in to the circulation [11]. Extension of the abscess may result in necrotizing mediastinitis and pericarditis [16]. Other complications include rupture of the esophagus or trachea, internal jugular vein thrombosis, laryngeal edema with airway obstruction, laryngeal chondritis and per chondritis, and recurrent laryngeal nerve and sympathetic trunk paralysis [17].

Diagnosis

Leukocytosis, elevated ESR and CRP are usually seen in AST. The serum level of free thyroxine (T4), triiodothyronine and thyroid stimulating hormones are normal in most of the cases. Hypothyroidism or thyrotoxicosis may be seen in some cases [1,7,15]. The diagnosis is confirmed by ultrasound scan which shows hypoechoic area mostly in left lobe, perithyroidal hypoechoic space and effacement of the plane between the thyroid and parathyroid tissues. CT scan is useful in assessment of the adjacent tissue planes and spread of infection into other spaces of the neck [17,18]. Lateral soft tissue X-ray of the neck show the soft tissue edema, tracheal air column, free gas in the tissue and the presence of calcification [14,19]. Recurrent suppurative thyroiditis needs evaluation for pyriform sinus fistula with barium swallow or direct laryngoscopy [1,9].

Treatment

The thyroid abscesses need parenteral antibiotics and drainage. The initial empiric antibiotics should cover the common organism including Methicillin Resistant Staphylococcus (MRSA), streptococci, anaerobes and gram negative bacilli. The final choice depends on the result of culture and sensitivity. The antibiotics choices include Clindamycin, Amoxicillin-Clavulanate, Ampicillin-Sulbactam, Piperacillin-Tazobactam and metronidazole plus penicillins. Small

abscess can be drained under CT or ultrasound guidance. Large abscess needs surgical drainage. If there is pyriform sinus fistula, surgical excision or chemocauterization is recommended. Associated thyrotoxicosis need symptomatic treatment. The thyroid function need to be monitored as there is chance of hypothyroidism following massive destruction of the gland from large abscess [1,3,6,20].

Conclusion

The thyroid abscess is a rare disease in children. Prompt suspicion and early treatment prevent life threatening complications. The diagnosis is confirmed with ultrasonogram and CT is indicated in selected cases if there is any suspicion of complication. The pyriform sinus fistula is the common cause for recurrent thyroiditis. The thyroid functions are usually normal, but thyrotoxicosis or hypothyroidism can develop in some cases. All children with abscess should be followed for the subsequent development of hypothyroidism.

References

- Paes JE, Burman KD, Cohen J, Franklyn J, McHenry CR, Shoham S, et al. Acute bacterial suppurative thyroiditis: a clinical review and expert opinion. *Thyroid*. 2010; 20: 247-255.
- Rohondia OS, Koti RS, Majumdar PP, Vajaykumar T, Bapat RD. Thyroid abscess. *J Postgrad Med*. 1995; 41: 52-54.
- Lazarus J, Hennessey J. Acute and sub acute and Reidel's thyroiditis. Ed. Leslie J. DE Groot. *The thyroid and it's diseases*. 6th ed. New York. Elsevier. 1996.
- Greene, JN. Subacute thyroiditis. *Am J Med*. 1971; 51: 97-108.
- Chiarello P, Magnolia M, Rubino M, Liquori SA, Miniario R. Thrombocytosis in children. *Minerva Pediatr*. 2011; 63: 507-513.
- Ghaemi N, Sayedi J, Bagheri S. Acute Suppurative Thyroiditis with Thyroid Abscess: A Case Report and Review of the Literature. *Iran J Otorhinolaryngol*. 2014; 26: 51-55.
- Lough R, Ramadan H, Aronoff S. Acute Suppurative Thyroiditis in Children. *Otorhinolaryngol Head Neck Surg*. 1996; 114: 462-465.
- Sai Prasad TR, Chong CL, Mani A. Acute suppurative thyroiditis in children secondary to pyriform sinus fistula. *Pediatr Surg Int*. 2007; 23: 779-789.
- Taphey M, Pornkul R. Acute suppurative thyroiditis due to pyriform sinus fistula: a case report. *J Med Assoc Thai*. 2010; 93: 388-392.
- Brook I. Microbiology and management of acute suppurative thyroiditis in children. *Int J Pediatr Otorhinolaryngol*. 2003; 67: 447-451.
- Yu EH, Ko WC, Chuang YC, Wu TJ. Suppurative Acinetobacter baumannii thyroiditis with bacteremic pneumonia: case report and review. *Clin Infect Dis*. 1998; 27: 1286-1290.
- Ataca P, Atilla E, Saracoglu P, Yilmaz G, Civriz Bozdag S, Toprak SK et al. Aspergillus Thyroiditis after Allogenic Hematopoietic Stem Cell Transplantation. *Case Rep Hematol*. 2015; 2015: 537187.
- Yoshino Y, Inamo Y, Fuchigami T, Hashimoto K, Ishikawa T, Abe O, et al. A pediatric patient with acute suppurative thyroiditis caused by Eikenella corrodens. *J Infect Chemother*. 2010; 16: 353-355.
- Bussman YC, Wong ML, Bell MJ, Santiago JV. Suppurative thyroiditis with gas formation due to mixed anaerobic infection. *J Pediatr*. 1977; 90: 321-322.
- Rich EJ, Mendelman PM. Acute suppurative thyroiditis in pediatric patients. *Pediatr Infect Dis J*. 1987; 6: 936-940.
- Iwama S, Kato Y, Nakayama S. Acute suppurative thyroiditis extending to descending necrotizing mediastinitis and pericarditis. *Thyroid*. 2007; 17: 281-282.
- Bernard PJ, Som PM, Urken ML, Lawson W, Biller HF. The CT findings of acute thyroiditis and acute suppurative thyroiditis. *Otolaryngol Head Neck*

- Surg. 1988; 99: 489-493.
18. Masuoka H, Miyauchi A, Tomoda C, Inoue H, Takamura Y, Ito Y, et al. Imaging studies in sixty patients with acute suppurative thyroiditis. *Thyroid*. 2011; 21:1075-1080.
19. McCarty M, Coker R, Claydon E. Case report: disseminated *Pneumocystis carinii* infection in a patient with the acquired immune deficiency syndrome causing thyroid gland calcification and hypothyroidism. *Clin Radiol*. 1992; 45: 209-210.
20. Brook I. Role of methicillin resistant *Staphylococcus aureus* in head and neck infections. *J Laryngol Otol*. 2009; 123: 1301-1307.