

## Short Communication

# Selective Destruction of Capillaries in Pancreatic Islets Induced by Diabetogenic Zinc Binding Chemicals as Possible Cause of Aggravation of Diabetes

Meyramov GG<sup>1\*</sup>, Kartbaeva GT<sup>1</sup>, Shaybek AS<sup>1</sup>, Laryushina EM<sup>2</sup>, Dupont ON<sup>1</sup>, Alina AR<sup>2</sup>, Andreeva AP<sup>1</sup> and Abraimova AG<sup>2</sup>

<sup>1</sup>Buketov Karaganda State University, Kazakhstan

<sup>2</sup>Karaganda State Medical University, Kazakhstan

\*Corresponding author: Meyramov GG, Buketov Karaganda State University, Kazakhstan

Received: August 16, 2017; Accepted: August 28, 2017;

Published: September 04, 2017

## Background

Administration of Diabetogenic Zinc-Binding Chelat Active Chemicals (DZC) as Dithizon (DZ) and more that 10 derivatives of 8-Oxyquinolin (8OXY) forming in B-cells of pancreas (rabbits, mice, cats, dogs, hamsters, human embryo) of toxic complexes “Zn-chelator” which result destruction of 90-100% of B-cells within 15-30 min [1-5]. It was established that diabetes caused by DZC accompanied by fragmental destruction in islets of capillaries wall and developing of disturbances of blood circulation in islets [6]. Previously these changes were explained as vascular changes typical for diabetes and developed as late vascular complication not as result of local direct influence of “Zn-chelator” complex on wall.

## Aim of Work

To study a possible role formation of “Zn-chelator” complexes in B-cells contacted with wall of capillaries in the pathogenesis of alteration of capillaries.

## Methods

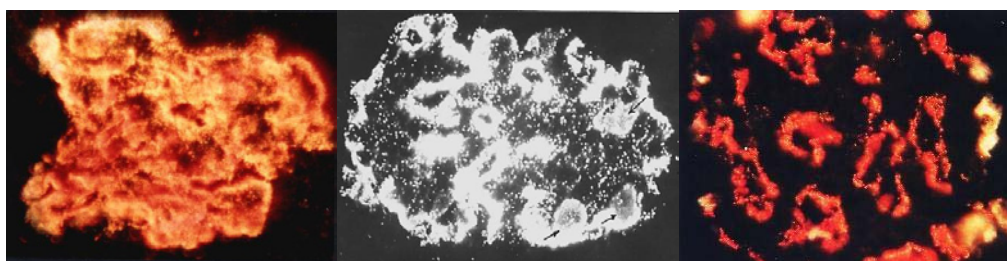
Various dosed of water-ammonium solution of Dithizon were injected to 14 rabbits: group 1 (4 animals) - 48, 8-51, 9mg/kg, a maximal dose result binding of all amount of Zn in B-cells and developing of diabetes in all animals; group 2 (6 animals) - 35-40 mg/

kg: maximal binding of Zn-ions in B-cells contacted capillaries wall and partial binding in other B-cells; diabetes developed in majority of animals; group 3 (6 animals) - 12-16 mg/kg: binding of Zn-ions in B-cells located around capillaries only. 2 animals of group 1 groups and 3 from groups 2 and 3 were killed 10-15 min past injection of DZ; frozen sections of pancreas tissue animals were investigated using microscopy with dark condenser and other animals were killed 10-11 days past injection of DZ (groups 1 and 2) and at 17-18<sup>th</sup> day (group 3). Blood Glucose Control (BG) - before and at 3<sup>rd</sup>, 6<sup>th</sup> and 9-10<sup>th</sup> days; sections of fixed pancreas tissue after staining by aldehyde-fuchsine were investigated [7,8].

## Results

**Group 1:** a large amount of granule of complex “Zn-Dithizon” in cytoplasm of B-cells (Figure1a). Concentration of “Zn-Dithizon” complex concentrated in B-cells contacted capillarie’s wall (K<sup>1</sup>) (Figure 1b) in compared with photometry [9] of other B-cells (K<sup>2</sup>): K<sup>2</sup>/K<sup>1</sup> =0, 78±0, 18; BG level 4, 9mM, 10, 7mM, 13, 4m Mand 18, 8mM. **Group 2:** maximal concentration of “Zn-Dithizon” complex concentrated in B-cells contacted capillaries wall (K<sup>1</sup>) (Figure 1b) in compared with photometry of other B-cells (K<sup>2</sup>): K<sup>2</sup>/K<sup>1</sup> =0, 34±0, 04; diabetes was developed in all animals; BG level: 5, 2±0, 5mM, 11, 6±1, 1mM, 10, 8±1, 4mM and 17, 2±2, 6mM fragmental destruction and death of endothelium; microcirculation: blood hyperemia and stasis, exocytosis of erythrocytes.

**Group 3:** “Zn-Dithizone” complex formed only in B-cells contacted capillarie’s wall (Figure 1c) (K<sup>2</sup>/K<sup>1</sup> = 0,04±0,01); marked diabetes was developed in 1 animal from 3; BG level of other 2 animals: 4, 7±0, 4mM, 9, 2±1, 9mM, 6, 2±1, 3mM and 9, 6±0, 7mM at 16<sup>th</sup> day; marked destruction and necrosis of endothelium of capillaries in islets of all animals; microcirculation: marked blood hyperemia and stasis, exocytosis of erythrocytes.



**Figure 1(a-c):** Pancreatic islets of Rabbits after injection of maximal (Figure 1a), middle (Figure 1b) and low (Figure 1c) doses of Dithizon. Red complex “Zn-Dithizon” (at Figure 1b- black-white foto) in B-cells. Frosensections of pancreas. Dark microscopy; x280.

(Figure 1a: histological section staining and microphoto – by Meyramov G.G. 2012;

Figure 1b: histological section staining and microphoto – by Meyramov G.G.1970;

Figure 1c: histological section staining and microphoto – by Meyramov G.G. 2015).

## Conclusion

We suppose that primary cause of alteration and destruction of islet's capillaries wall in animals without diabetes past injection of low doses of DZ, may be determined by contact of high concentration of toxic "Zn-Dithizon" complex with wall of capillaries in part of cell membrane of B-cells contacted capillaries.

## References

1. Okamoto K. Experimental production of diabetes. Diabetes mellitus: Theory and Practice, McGraw-Hill Book company. NY. 1970: 230-255.
2. Kawanishi H. Secretion of B-granules in islets of Langerhans in association with intracellular reactive zinc after administration of Dithizone in rabbits. Endocrinol. Jap. 1966; 13: 384-408.
3. Lazaris YA, Meyramov GG. On the machanisms of destruction of pancreatic islets in diabetes caused by Dithizon. Bull.Exp.Biol.Med. Moscow. 1974: 19-22.
4. Meyramov GG, Truchanov NI. Ultrastructure of pancreatic B-cells in diabetes caused by Dithizone and its prevention by Diethyldithiocarbamic acid. Problems of Endocrinology. Moscow. 1975: 92-95.
5. Meyramova AG. DiabetogenicZincbinding B-cytotoxic Chemicals. Problems of Endocrinology. Moscow. 2003; 49: 8-16.
6. Meyramov G.G, Kikimbaeva AA, et al. Vascular and Histological Changes in Pancreatic Islets in Diabetes Caused by Xanthurenic Acid//Diabetes. 2013; 62: 727.
7. Kvistberg D, Lester G, Lasarov A. Staining of insulin with aldehyde fuchsin. J. Histochem. Cytotochem -1966; 14: 609-611.
8. Ortman R, Forbes W, Balasubramanian A. Concerning the staining properties of aldehyde basic fuchsin. J. Histochem. 1966; 14: 104-111.
9. Meyramov GG, Tusupbekova GT, Meyramova RG. Histofluorimetric method for measuring insulin content in pancreatic B-cells. Problems of Endocrinology, Moscow. 1987; 33: 49-51.