

Special Article – Fungal Sinusitis

Fungal Sinusitis: Sudanese Experience

Mahgoub ES, Ismail MAI and Gabr A*

Department of Microbiology, Faculty of Medicine, University of Khartoum, Sudan

*Corresponding author: Mahgoub ES, Department of Microbiology, Faculty of Medicine, University of Khartoum, Sudan

Received: October 24, 2016; Accepted: December 06, 2016; Published: December 08, 2016

Abstract

Chronic Invasive Fungal Sinusitis (CIFS) is frequently seen in otolaryngology clinics in Sudan. Patients presented late with maxillary sinus swelling and unilateral proptosis. Surgical removal was used to be the sole management approach and was often associated with recurrence. The causative organism used to be *Aspergillus flavus*. A total of 579 operative specimens were received in the mycology laboratory, faculty of medicine, university of Khartoum between 2010 and 2015. These were studied by culture and Counter Immuno Electrophoresis (CIE).

Clinical information of eight patients was available. Only 280 operative specimens (46.3%) gave positive growth of fungi and positive CIE test. *A. flavus* constituted the majority of fungi isolated but there were a few ones due to *A. terreus* and *Bipolaris specifera*. In addition to surgery the former was treated with Itraconazole and the latter with Voriconazole. An appreciable number of specimens were from nasal polyps.

In conclusion:

- CIFS constitutes an important problem in otolaryngology clinics in Sudan.
- The dry dusty weather of Sudan may constitute a predisposing risk factor for infection.
- *A. flavus* constitutes the major causative fungus but there are other moulds as well.
- Combined surgical and medical treatment is recommended.

Keywords: Fungal sinusitis; Paranasal *Aspergillus granuloma*; *Aspergillus flavus*; *A. fumigatus*; *A. terreus*; *Bipolaris specifera*

Introduction

Fungal sinusitis is inflammation of the membrane of the nasal sinuses by different fungi mostly *Aspergillus* species. Fungal sinusitis, formerly described as Paranasal *Aspergillus Granuloma* (PNAG) because the sinus affected most was the Maxillary sinus, the histopathological reaction was typical granuloma and the fungus isolated was an *Aspergillus* the term Paranasal *Aspergillus Granuloma* (PNAG) was used for many years in Sudan [1,2].

Fungal sinusitis is a relatively common disease frequently reported from Sudan and India [3-5]. Since the advent of AIDS interest developed in cases in both immunocompromised and immunocompetent individuals in relation to treatment of the causative fungi. Cases were reported from Japan, Saudi Arabia, Taiwan and USA [6-9].

Reports on fungal sinusitis (Paranasal *Aspergillus Granuloma*) in Sudan date back to 1967 when the first patient reported with unilateral proptosis was wrongly diagnosed as cancer of the eye and consequently the eye was removed [10]. When the specimen was sent to Edinburgh University *Aspergillus flavus* was isolated.

At the beginning cases seen involved Paranasal sinuses particularly the maxillary sinus and causing unilateral proptosis. However in recent years more patients reported with nasal polyps.

This paper describes the clinical findings, diagnosis, causative organisms and treatment of cases or specimens that presented to the Mycology unit of the department of microbiology, faculty of medicine, and university of Khartoum in the last five years.

Patients & Materials

Details of eight patients whose laboratory request forms included clinical information are shown in (Table 1). Specimens received were either tissue or serum. The former were divided in two, one half was used for culture by grinding it first in saline using a 10-Broeck tube. Suspension was placed on glucose nutrient agar with chloramphenicol at 26°C for 10 days. The other half was sent for histopathology. Histological slides were stained with H/E and Gomori Methenamine silver. Serum was tested against *Aspergillus* antigens in the Counter Immuno Electrophoresis (CIE) for diagnosis and follow up [11].

Results

Particulars of eight patients whose laboratory request forms contained clinical information and methods of diagnosis are shown in Table 1.

Still many patients presented with maxillary sinus swelling (Figure 1) with or without proptosis. An appreciable number is now coming with nasal polyps only.

Results of specimens identification are shown in Table 2.

Table 1: Patients details, diagnosis and treatment.

Name	Sex	Age	Site of Infection	Duration	Diagnosed by	Organism	Treatment and Response
1. T.R.A	F	32yrs	Paranasal <i>Aspergillus Granuloma</i> (Rt. maxillary sinus)	14 years	CIE	<i>A. flavus</i>	Itraconazole 3 relapses
2.K.M.B	F	68yrs	Paranasal <i>Aspergillus Granuloma</i> (Rt. maxillary sinus)	1 year	Culture	<i>A. flavus</i>	Itraconazole (lost for Follow up)
3.M.H.M	F	28yrs	Retromolar <i>Aspergillus Granuloma</i>	3 years	Histopathology	<i>Aspergillus spp.</i>	Itraconazole (Greatly improved)
4..A.S.S	M	20yrs	Nasal polyp	3 yrs	Culture	<i>Bipolaris specifera</i>	Voriconazole (cured)
5. S.I.A	F	22Yrs	Maxillary sinus	3 yrs	Culture	<i>Bipolaris specifera</i>	Voriconazole (cured)
6. A.A.R	M	25yrs	Maxillary sinus & nasal polyp	3 yrs	Culture & serology	<i>A. flavus</i>	Surgery and Itraconazole
7.Sh.MS	F	23yrs	Nasal polyp	3yrs	Culture & serology	<i>A. terreus</i>	Itraconazole & voriconazole
8.A. G	F		Maxillary	1yr	Culture & serology	<i>A. flavus</i>	sqrted itraconazole

Table 2: Frequency of fungi isolated.

year	Total no	<i>A. flavus</i>	<i>A. terreus</i>	<i>A. fumigatus</i>	<i>Bipolaris sp.</i>	<i>Demat. fungi</i>	Total positive
2010	72	36/90%	1/2.5%	0	0	3/7.5%	40
2011	85	47/85.5%	3/5.5%	0	2/3.6%	3/5.5%	55
2012	104	49/83%	6/10%	2/3.4%	0	2/3.4%	59
2013	104	24/85.7%	3/10.7%	0	0	1/3.6%	28
2014	72	30/78.9%	0	5/13.2%	2/5.3%	1/2.6%	38
2015	142	50/83.3%	5/8.3%	3/5%	0	2/3.3%	60
Total	579	216	18	10	4	12	280



Figure 1: Maxillary sinus swelling Pt.6.



Figure 2: *Aspergillus flavus* culture.

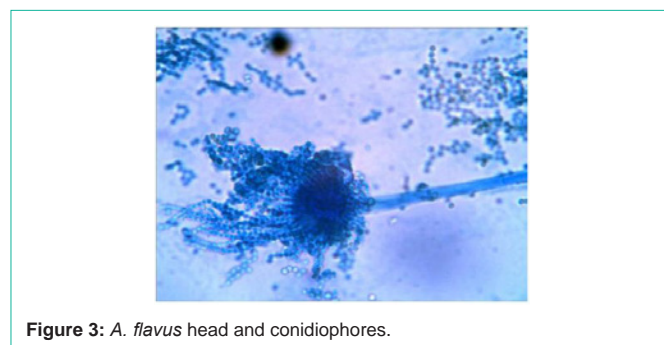


Figure 3: *A. flavus* head and conidiophores.

Fungi isolated were identified by morphological appearance, slide culture stained by lacto phenol blue. Positive sera development of precipitation lines opposite the homologous antigen. A total of 579 specimens were received between 2010 and 2015. Only 280 specimens (48.4%) gave positive cultures. Organisms isolated were *Aspergillus flavus* Figure 2, 3, *A. fumigatus*, *A. terreus* and *Bipolaris specifera* (Figure 4, 5) (Table 2).

Discussion

Chronic Invasive Fungal Sinusitis (CIFS) still constitutes an important health problem in otolaryngology clinics in Sudan. The last report [2] was published 17 years ago. The Increasing number of specimens (579) received in the mycology laboratory of the Faculty of Medicine University of Khartoum indicates that the problem is on the increase (the average of specimens for the years 2002-2008 is 93 per anum) S. This is attributed to the increasing awareness of doctors in these clinics and that of the community as well as the continued

interest in the mycology unit. Environmental factors such as the dusty spells in the weather of Sudan may play a pivotal role for infection. This was demonstrated in a study of risk factors from Egypt [12].

All patients reported before from Sudan were immunocompetent while in the small series reported here patient number 6 and number 8 are immunocompromised because they are diabetic. In a recent

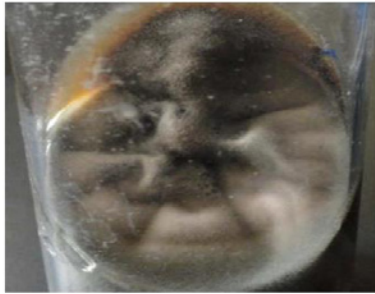


Figure 4: *Bipolaris specifera* culture.

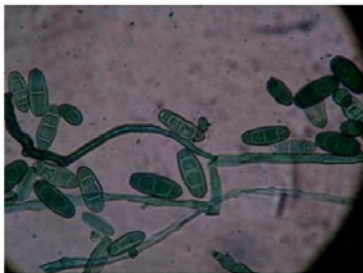

Figure 5: *B. Specifera* microscopy showing Macroconidia.

study from Iran [13] all patients with acute invasive form of sinusitis had an underlying disease, diabetes (71.4 %) or malignancy (28.6%).

It is interesting to note that while *A. flavus* was the sole causative agent in previous studies, in this series other fungi were isolated, namely *A. terreus*, *Bipolaris specifera* and unidentified dematiaceous fungi.

Conclusion

This study shows that there is an appreciable increase in cases of fungal sinusitis presenting either as nasal sinus swelling or nasal polyp. Patients with *A. flavus* were treated with Itraconazole while those caused by *Bipolaris specifera* responded very well to Voriconazole. Mycological diagnosis is therefore important since Itraconazole may cure the Aspergillus ones after surgery; However in our experience with few cases, Voriconazole will cure both.

Reference

1. Veress B, Malik OA, El Tayeb AA, El Daoud S, Mahgoub ES, El Hassan AM. Further observations on the primary paranasal aspergillus granuloma in the Sudan: a morphological study of 46 cases. *The American journal of tropical medicine and hygiene*. 1973; 22: 765-772.
2. Yagi HI, Gumaa SA, Shumo AI, Abdalla N, Gadir AA. Nasosinus aspergillosis in Sudanese patients: clinical features, pathology, diagnosis, and treatment. *Journal of Otolaryngology-Head & Neck Surgery*. 1999; 28: 90-94.
3. Panda NK, Sharma SC, Chakrabarti A, Mann SB. Paranasal sinus mycoses in north India. *Mycoses*. 1998; 41: 281-286.
4. Ramani R, Hazarika P, Kapadia RD, Shivananda PG. Invasive maxillary aspergillosis in an otherwise healthy individual. *Ear, nose, & throat journal*. 1994; 73: 420-422.
5. Krishnan KU, Agatha D, Selvi R. Fungal rhinosinusitis: A clinicomycological perspective. *Indian journal of medical microbiology*. 2015; 33: 120-124.
6. Nakaya K, Oshima T, Kudo T, Aoyagi I, Katori Y, Ota J, et al. New treatment for invasive fungal sinusitis: Three cases of chronic invasive fungal sinusitis treated with surgery and voriconazole. *Auris Nasus Larynx*. 2009; 37: 244-249.
7. Alrajhi AA, Enani M, Mahasin Z, Alomran K. Chronic invasive aspergillosis of the paranasal sinuses in immunocompetent hosts from Saudi Arabia. *The American Journal of tropical medicine and hygiene*. 2001; 65: 83-86.
8. Jhuo SJ, Wang WS, Kuo JY. Successful treatment of aspergillus: A case report. *Journal of internal medicine Taiwan*. 2011; 22: 63-68.
9. Mylonakis E, Rich J, Skolink PR, De Orchis DF, Flanigan T. Invasive aspergillus sinusitis in patients with human immunodeficiency virus infection: Report of 2 cases and review. *Medicine*. 1997; 76: 249-255.
10. Sandison AT, Gentles JC, Davidson CM, Branko M. Aspergilloma of paranasal sinuses and orbit in northern Sudanese. *Sabouraudia: Journal of Medical and Veterinary Mycology*. 1968; 6: 57-69.
11. Gumaa SA, Mahgoub Es. Counterimmunophoresis in the diagnosis of mycetoma and its sensitivity as compared to immunodiffusion. *Sabouraudia*. 1975; 13: 309-315.
12. Mostafa BE, El Sharnoubi MM, El-Sersy HA, Mahmoud MS. Environmental Risk Factors in Patients with Noninvasive Fungal Sinusitis. *Scientifica*. 2016.
13. Nazeri M, Hashemi SJ, Ardehali M, Rezaei S, Seyedmousavi S, Zareei M, et al. Fungal Rhino Sinusitis in Tehran, Iran. *Iranian journal of public health*. 2015; 44: 374-379.