

## Research Article

# Cochlear Implant in Labyrinthitis Ossificans

Carvalho GM\*, Lavor M, Beltrame Onuki LC, Paschoal JR, Bianchini WA and Guimarães AC  
Department of Ear, Nose, Throat and Head & Neck Surgery, Otolaryngology, Audiology and Implantable Ear Prostheses, São Paulo, Campinas University, UNICAMP, Brazil

\*Corresponding author: Carvalho GM, Department of Ear, Nose, Throat and Head & Neck Surgery, Otolaryngology, Audiology and Implantable Ear Prostheses, São Paulo, Campinas University, UNICAMP, Brazil

Received: June 12, 2016; Accepted: August 19, 2016;

Published: August 22, 2016

## Abstract

**Introduction:** Labyrinthitis ossificans is a pathologic ossification in the otic capsule due to an inflammatory or destructive process. The main causes are meningitis, trauma and otosclerosis. A Cochlear ossification result in sensorineural hearing loss, and its presence is associated with technical difficulties and poorer functional results. Advances in surgical techniques and bioengineering provided the development of special electrodes for this condition. This study aimed to evaluate the functional results with partial standard and double-array cochlear implantation in ossified cochlea and describe the performance using the device.

**Methods:** A retrospective and transversal analysis of data on demographic aspects, auditory performances and surgical findings was made. A transorbital radiograph was used to evaluate electrode migration and insertion depth and the position of the internal component. All patients who underwent either partial insertion of a standard electrode array or double-array electrode insertion for their cochlear implantation in a quaternary centre in the last five years were included.

**Results:** Eight patients (six adults and two children) were included. The cause of labyrinthitis ossificans was bacterial meningitis in six cases, Cogan's syndrome in one patient and trauma in another patient. Most patients were implanted in adulthood and the average duration of deafness was 104.5 months. Displacement in the basal electrode was observed in one patient, who went through a new surgical procedure with successfully repositioning.

**Discussion:** Bacterial meningitis was the most common cause of cochlear ossification in the sample. In adult patients, meningitis acquired in childhood resulted in a longer deafness than in children, which may explain poorer auditory results.

**Conclusion:** Patients with ossified cochlea benefits significantly from double-array and compressed short array cochlear implantation.

**Keywords:** Cochlear implant; Labyrinthitis ossificans; Hearing loss

## Introduction

Labyrinthitis ossificans can be defined as a pathological ossification within the otic capsule in response to an inflammatory or destructive process. The main causes of cochlear ossification include meningitis, trauma, malignant infiltration, otosclerosis, tumors, ototoxicity or other infections affecting the internal ear [1,2]. Labyrinthitis ossificans is cause of sensorineural hearing loss of varying degrees and, when occurs bilaterally, there is an indication of cochlear implant in the failure of treatment with sound amplification therapy. Bacterial meningitis is a major cause of bilateral profound sensorineural hearing loss in children, with prevalence ranging from 60% to 90% [2-5].

*Streptococcus pneumoniae* is the etiologic agent most associated with high mortality and high risk of developing deafness [5-8].

Bacterial infection in the subarachnoid space, which usually reaches the cochlea by the cochlear aqueduct, may also occur via blood or the internal auditory canal. As a result, there is an ossification and partial or total of scala tympani obliteration of the basal turn of the cochlea in up to 80% of cases of labyrinthitis ossificans after meningitis [1,4,9,10].

The infection ascends from the basal turn to intracochlear structures, especially the organ of Corti, often causing profound and irreversible hearing loss [7].

It is known that the number of electrodes activated postoperatively is an essential factor for the presence of good audiological results. The presence of cochlear ossification hinders the full insertion of electrodes in conventional cochlear implants, resulting in a worse audiological result when compared with non-ossified cochleas [4,10].

Originally, the presence of labyrinthitis ossificans was considered a contraindication to the cochlear implant. The auditory brainstem implant can be considered an option for patients with cochlear malformations, including cochlear ossification. However, since this technique is still accompanied by high risk of complications and high morbidity, it is currently underused in these cases [2,9,11].

Advances in surgical techniques, better knowledge of the anatomy and development of specific electrodes have allowed more and more patients to become candidates for cochlear implants. Several techniques have been developed to obtain the largest possible number of electrodes implanted in totally ossified cochlea. However, these techniques allow only partial insertion, in addition to having

a high rate of postoperative complications and do not preserve the anatomy of cochlea [2].

The cochlear implant with two beams of short electrodes (cochlear nucleus double array) was developed specifically for obliterated or/with surgically inaccessible pars ascendens/2<sup>nd</sup> turn ossification of the cochlea and first used in 1995. This technique allows a greater number of electrodes implanted when compared with the technique of partial insertion, allowing better post operative audiological results [2].

Whereas a greater number of implanted electrodes imply the best audiological responses, early detection of cochlear ossification is essential to surgical success. Imaging diagnosis can be done by CT scans or high resolution MRI with good accuracy. The process of cochlear ossification in meningitis starts in the first weeks after infection and can take months for the formation of compact bone [8].

It was observed that CT has limitations for identification of early stages of cochlear ossification in the basal turn, being surpassed by MRI, which is able to identify the stage of fibrosis of the perilymphatic space, prior to ossification [4].

Thus, there is controversy regarding the time of implantation in these patients: some authors advocate the use of sound amplification therapy at least one year before the cochlear implant; others argue that the implant should be performed as early as possible, due to the risk of complete ossification and partial insertion of electrodes [12].

This study aimed to evaluate patients undergoing double array or compressed partial insertion type cochlear implant due to cochlear ossification and describe the outcomes using the device. For this purpose, the following aspects were considered: audiological performance, the type of device, duration of deafness preimplantation and the rate of postoperative complications.

## Methods

Retrospective, cross-sectional study based on analysis of data from patients with profound sensorineural hearing loss due to labyrinthitis ossificans. Patients underwent unilateral cochlear implant (compressed or double array), between 2009 and 2013, in the reference service.

The following aspects were considered: etiology of cochlear ossification, preoperative audiological evaluation and imaging, age at implantation, time between the onset of cochlear disease and surgery and complication rate. Preoperative evaluation using computed tomography and magnetic resonance imaging was performed to demonstrate the degree of cochlear ossification.

Postoperatively, transorbital radiographs were performed to evaluate the position and possible migration of internal component, as well as its electrode.

The surgical decision to use the compressed array versus the double array was by random and was followed interchangeably between these two models.

### Inclusion criteria

Inclusion criteria were: sensorineural hearing loss (severe/profound), normal otoscopy, absence of middle ear disease, absence

of acoustic reflex, absence in ABR waves and imaging (MRI / CT) showing the presence of the cochlear nerve and excluding retro cochlear disturbances.

Hearing aids were used in all subjects before treatment and when no benefits were showed it was indicated the cochlear implants (have sensorineural bilateral hearing loss with little or no benefit from HA - less than 40% of auditory discrimination in monosyllables), have pure-tone thresholds  $\geq 80$  dB hearing loss, have had stable hearing loss for at least the past two years, and lastly pass a psychological examination ensuring they had realistic expectations about the potential benefits of receiving a cochlear implant. All subjects underwent Pure Tone Audiometry (PTA) and speech tests, pre- and postoperatively.

All patients who did not complete these criteria were excluded from the study.

### Audiological evaluation

Audiological tests were performed including impedanciometry, speech and pure tone audiometry. The tests were performed using an audiometer AC30-SD25, calibrated according to ISO 389 standards / 64.

For ABR, which were repeated at least two times, we used the device AT-235 (Interacoustics).

The classification of hearing impairment by audiometry was through stratification in mild, moderate, severe or profound hearing loss [13].

### Speech perception tests

Preoperatively, all subjects took a speech perception test the same day as their implantation. We used a speech perception sentence test based on one developed by [14] from several English language tests [14]. Subjects did the test with their hearing aids on, in a quiet place.

Postoperatively, all subjects repeated the speech perception test at least one year of CI experience. Tests were done in subject's best-aided condition: CI-only. The same audiologist conducted all the pre and postoperative tests.

### Subjective ratings

Likert scale was applied in the pre operative and also in the postoperative time. In the pre operative time it was applied in the day before the surgery. When the subjects did their postoperative speech tests they were asked to rate the quality of their experience with CI over the past year on a Likert scale scored 0 to 10. A score of 0 indicated the user regretted the intervention, would not recommend it to others, and felt he/she had been better off in the past with their hearing aids. A score of 10 indicated the user was completely satisfied with the intervention and would strongly recommend it.

### Statistical analysis

The data were analyzed using descriptive analysis, with production of means, medians, standard deviation tabs.

Chi-Square was used to compare the groups of our sample. Spearman analysis and Mann-Whitney tests was also performed.

The confidence Interval was of 95% and p-value  $< 0.05$  was considered significant.

**Table 1:** Description of patients.

	Total	Double Array Electrode	Compressed Electrode
Gender	4 Female	1 Female	3 Female
	4 Male	3 Male	1 Male
Age	Mean 31 (6-49)	Mean 28 (6-46)	Mean 34 (11-49)
	STDEV: 15,24	STDEV: 15,45	STDEV: 14,30
Time of deafness	116 months (7-432)	158 months (19-432)	75 months (7-108)
	STDEV: 126,49	STDEV: 164,39	STDEV: 39,93
Type of electrode	4 Cochlear Double Array	4 Cochlear Double Array	4 Medel Compressed
	4 Medel Compressed		
Speech Processor	4 Freedom	4 Freedom	4 Opus2
	4 Opus2		
Side of CI	3 Left	1 Left	2 Left
	5 Right	3 Right	2 Right
Time of CI use	42,12 months (14-124)	63 months (37-124)	21,25 months (14-28)
	STDEV: 22,43	STDEV: 29,39	STDEV: 3,76
Etiology	6 meningitis	4 meningitis	2 meningitis
	1 trauma		1 trauma
	1 Cogan Syndrome		1 Cogan Syndrome
			1 Cogan Syndrome
Speech Test (Pre Op)	7 Subjects 0%	Mean 0% (0-0)	Mean 6% (0-22%)
	1 Subject 22%	STDEV: 0	STDEV: 0,25
Speech Test (Post Op)	4 Subjects < 10%	Mean 25,5% (0-52)	Mean 22,5% (0-56)
	1 Subject <10 & >50%	STDEV: 15,45	STDEV: 0,23
	3 Subjects > 50%		
Comorbidities	0	0	0

STDEV: Standard Deviation.

### Ethical considerations

This study was previously approved by the Research Ethics Committee of the Faculty of Medical Sciences of the University of Campinas on June of 2014, with the ID 30981814.1.0000.5404.

### Results

We collected data from eight patients, six adults and two children. The average age of the sample was 31 years. The main cause of the cochlear ossification was meningitis, observed in six patients, one patient had Cogan's syndrome and another patient had previous trauma (Table 1). All patients underwent cochlear implant between December 2009 and April 2013 in a quaternary service. The average duration of deafness was 104.5 months. Four of these patients, one child and three adults underwent cochlear implantation using double array and in the other four patients was used the short compressed.

In only one case the full insertion of electrodes was possible, when the double array was used. One patient underwent a new surgical procedure two years after the first surgery, due to a displacement of the basal electrode. The repositioning was successfully performed. We can consider that almost 90% of the electrodes were active most of the time in both groups. The intraoperative data are listed in (Table 2).

The audiological results pre and post implant are listed in (Table 3) was observed that all patients who underwent cochlear implantation with double array and short compressed electrodes had

**Table 2:** Intraoperative data.

		Total n	
		Double Array Electrode	Compressed Electrode
Insertion	Total	1	1
	Partial	3	3
Removing ossicles	No	0	3
	Stapes and Incus	4	1
Complications		1	0

improved the audiological performance, with statistical significance.

The Likert scale is demonstrated at (Figure 1). It can be noted that all patients had a great improvement comparing the pre op and post op time ( $p < .05$ ). The compressed electrode array group get better scores, but with no significant difference between the groups ( $p > .05$ ).

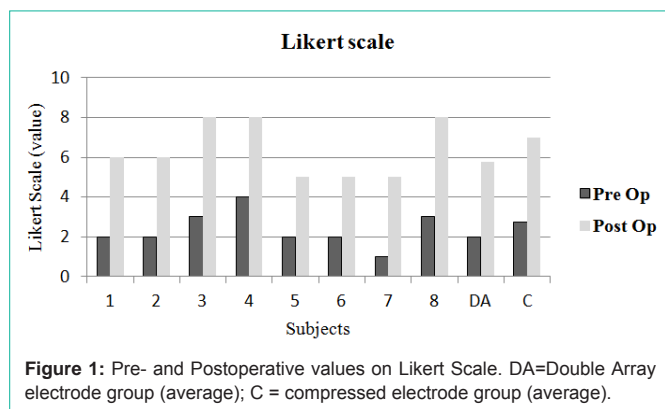
### Discussion

In this study, were assessed patients with pre- and post-lingual sensorineural deafness and cochlear ossification who underwent cochlear implant in a quaternary service, using compressed and double array type devices. The results corroborate the literature data, demonstrating an improvement in audiological performance of patients with cochlear ossification.

**Table 3:** Audiological results pre and post implant.

		Total	<i>p</i>
SPT	Pre op	0	<i>p</i> = 0,04
(median values)	Post op	17	
Hearing Thresholds	Pre op	120	<i>p</i> =0,0007
(median values)	Post op	30	

SPT: Speech Perception Test. Statistical significant *p* value <0,005.



**Figure 1:** Pre- and Postoperative values on Likert Scale. DA=Double Array electrode group (average); C = compressed electrode group (average).

The surgical decision to use the compressed array versus the double array was by random and was followed interchangeably between these two models. There were no selection criteria for choosing some electrode array model for each subject.

There are few descriptive studies showing the results of cochlear implantation using these two types of electrodes. It must be highlighted that we do not want to compare the quality between these two types of electrodes arrays, but to demonstrate that different types of electrodes with different approaches can bring benefits for patients treated with cochlear implants, concerning good audiological, speech understanding and personal satisfaction outcomes.

The cochlear ossification is a fibrotic process resulting of various pathological conditions, such as trauma or infection of the inner ear, which leads to deafness of varying degrees. Meningitis, the main cause of deafness in children, is among the most frequent causes of cochlear ossification [2,3,8].

Previous studies showed that the main etiological agent of meningitis associated with labyrinthitis ossificans is *Streptococcus pneumoniae* [3,6,7,8]. Cochlear implant is indicated for hearing rehabilitation in patients with labyrinthitis ossificans due to prior meningitis. Since it is known that the presence of labyrinthitis ossificans makes the introduction of electrodes intraoperatively difficult, several specific techniques, with varying results, are described for this condition.

A retrospective study of post-meningitis patients with and without cochlear ossification showed that there was benefit in the use of cochlear implants in these cases, but with unpredictable audiological results in both groups. The partial insertion in the first group may compromise the final audiological performance, although it is not a mandatory failure predictor.

Moreover, it is not known how cortical neural involvement in meningitis serves as an influencing factor due to the presence of

poor results reported in post-meningitis patients without cochlear ossification [7].

In another study, the technique of retrograde insertion of electrodes from an apical cochleostomy was used due to ossification of the basal turn, preventing conventional access. In this case, patients with cochlear ossification after meningitis submitted to the two techniques were compared with similar audiological results and no additional hassle [15].

The use of compressed or double array type devices allowed the full introduction of the electrodes during surgery, which often was not possible using conventional implants, resulting in a higher number of electrodes inserted and subsequently activated.

Previous studies that compared patients with labyrinthitis ossificans undergoing conventional versus double array cochlear implants showed better speech perception results in the second case [2].

In one of these studies, it was found that the age of implantation was a contributing factor to better observe audiological results, superior to the time of deafness [2]. The early deployment is justified by the lower degree of cochlear ossification observed in younger patients due to a shorter post-meningitis cochlear exposure [2,4,5,12].

The cochlear ossification often makes cochlear implants a challenge even for experienced surgeons. Intraoperative difficulties and complications are not uncommon. In the presence of cochlear ossification without obliteration, partial insertion of the electrodes can be performed with good audiological results [7].

However, due to the lower stability after insertion, the electrodes are subject to migration or extrusion even with the passage of time, as shown in a previous study [3]. In our sample, we found a case of lead migration after partial insertion, and the patient underwent a new surgical procedure for successful reintegration.

A therapeutic alternative for patients with labyrinthitis ossificans is the brainstem implantation [11]. When it was described, this technique was classically indicated for cases of profound sensorineural deafness associated with technical difficulty of insertion of electrodes, including cochlear ossification [9].

However, the audiological results of brainstem implants are still questionable and lower when compared with conventional cochlear implants. Furthermore, brainstem implants are associated with a high morbimortality, having major complications such as meningitis, hydrocephalus and subdural hematoma [9].

A retrospective study comparing patients with posttraumatic deafness who underwent cochlear implant versus brainstem implant showed better results in the first case; and the presence of cochlear ossification should not be a predictor for the choice of brainstem implant [16].

It can be considered as a limitation of this study the presence of a small and heterogeneous sample, with different ages and variable times of deafness. However, these differences were important to observe the impact factor of these aspects on audiological results. Moreover, the described surgeries were not performed by the same surgeon, which hardly happens in university services.

We demonstrated that cochlear implant surgery in those patients is highly beneficial to the hearing lives of the partially deaf—even evidenced in their extremely positive Likert scale responses—even when we fail to achieve excellent audiological hearing outcomes. It can be noted that there was no difference between the scores comparing the two groups of subjects ( $p > .05$ ). In both groups the rate of the active electrodes was very similar and near from 90%.

Once more, regarding the bias' study, the present data supports that those subjects with ossified labyrinths achieve benefit from cochlear implantation with either a double or compressed array, which is according to the medical literature. When to compare these two devices, no conclusions can be made due to differences issues, including number of patients evaluated variety of etiology, and the duration of pre-operative hearing loss, differences in the surgical approach and intraoperative findings regarding the ossification.

It must be note that imaging (CT scan) is inadequate in determining pre-operative ossification, as we used in this study, but is a challenge to determine a better way to classify the intracochlear ossification.

This study is interesting because it shows data on challenging cases of cochlear implants in ossified cochlea besides the small number of patients in this manuscript. It can be remained that are few published cases of this same topic in the literature. It would be interesting to perform a review with more cases and longer follow up to achieve more consistent results and conclusions.

Finally, one cannot say how much the neural component of deafness after meningitis influence hearing results of patients analyzed in this situation, which does not occur in patients with deafness due to other etiologies.

According to the observed results, we can state that patients with sensorineural deafness due to labyrinthitis ossificans benefit from the use of double array and compressed type cochlear implants, with good audiological results.

## Conclusion

Cochlear implants are an option for hearing rehabilitation in patients with ossificans labyrinthitis; however, it is very important to discuss prognosis with the patient and their families.

## References

- Xu HX, Joglekar SS, Paparella MM. Labyrinthitis Ossificans, *Otol Neurotol*. 2002; 30: 579-580.
- Roland Jr JT, Coelho DH, Pantelides H, Waltzman SB. Partial and Double-Array Implantation of the Ossified Cochlea, *Otol Neurotol*. 2008; 29: 1068-1075.
- El-Kashlan HK, Ashbaugh C, Zwolan T, Telian SA. Cochlear Implantation in Prelingually Deaf Children with Ossified Cochleae. *Otol Neurotol*. 2003; 24: 596-600.
- Philippon D, Bergeron F, Ferron P, Bussi eres R. Cochlear Implantation in Postmeningitic Deafness. *Otol Neurotol*. 2009; 31: 83-87.
- Durisin M, Bartling S, Arnoldner C, Ende M, Prokein J, Lesinski-Schiedat A, et al. Cochlear Osteoneogenesis After Meningitis in Cochlear Implant Patients: A Retrospective Analysis. *Otol Neurotol*. 2010; 31: 1072-1078.
- Douglas SA, Sanli H, Gibson WPR. Meningitis resulting in hearing loss and labyrinthitis ossificans – does the causative organism matter? *Cochlear Implants Int*. 2008; 9: 90–96.
- Nichani J, Green K, Hans P, Bruce I, Henderson L, Ramsden R. Cochlear Implantation After Bacterial Meningitis in Children: Outcomes in Ossified and Nonossified Cochleas. *Otol Neurotol*. 2011; 32: 784-789.
- Teissier N, Doehring I, Noel-Petroff N, Elmaleh-Berg es M, Viala P, Fran ois M, et al. Implants cochl aires dans les surdit es apr es m ningite bact rienne: suivi audiolgique de 16 enfants. *Archives de P diatrie*. 2013; 20: 616-623.
- Tan VYJ, D'Souza VD, Low WK. Acoustic brainstem implant in a post-meningitis deafened child—Lessons learned. *International Journal of Pediatric Otorhinolaryngology*. 2012; 76: 300–302.
- Boorman DG, Maggs JK, McSparran EL, Cheshire IM, Pearman K, Proops DW. Case Report: Early bilateral simultaneous cochlear implantation in a five-year-old following head injury complicated by acute bacterial meningitis. *Cochlear Implants International*. 2004; 5: 112–116.
- Colletti L, Shannon R, Colletti V. Auditory brainstem implants for neurofibromatosis type 2. *Curr Opin Otolaryngol Head Neck Surg*. 2012; 20: 353–357.
- Hassepass F, Schild C, Antje A, Laszig R, Maier W, Beck R, et al. Clinical Outcome After Cochlear Implantation in Patients With Unilateral Hearing Loss Due to Labyrinthitis Ossificans, *Otol Neurotol*. 2013; 34: 1278-1283.
- Goodman A. Reference zero levels for pure-tone audiometers. *ASHA*. 1965; 7: 262-273.
- Bevilacqua, M R. Banhara, E A. da Costa, A B. Vignoly, and K F. Alvarenga. The Brazilian Portuguese hearing in noise test. *Int J Audiol*. 2008; 47: 364-365.
- Senn P, Rostetter C, Arnold A, Kompis M, Vischer M, Hausler R, et al. Retrograde Cochlear Implantation in Postmeningitic Basal Turn Ossification. *Laryngoscope*. 2012; 122: 2043–2050.
- Medina M, Di Lella F, Trapani G, Prasad SC, Bacciu A, Aristegui M, et al. Cochlear Implantation Versus Auditory Brainstem Implantation in Bilateral Total Deafness After Head Trauma: Personal Experience and Review of the Literature. *Otology & Neurotology*. 2014; 35: 260-270.