

Case Report

Anesthetic and Surgical Considerations in Giant Vallecular Cyst with Coexistent Laryngomalacia of Neonate

Verma RK^{1*}, Panda NK¹ and Bhatia N²¹Department of Otolaryngology and Head & Neck Surgery, PGIMER, India²Department of Anaesthesia, PGIMER, India

***Corresponding author:** Roshan k Verma, Department of Otolaryngology and Head & Neck Surgery, Postgraduate Institute of Medical Education and Research (PGIMER), Chandigarh, 160012, India

Received: November 17, 2014; **Accepted:** September 05, 2015; **Published:** September 11, 2015

Abstract

Vallecular cyst in neonate is rare and can cause of respiratory obstruction and death. It may sometimes co-exist with laryngomalacia and may be cause of severe respiratory obstruction and feeding difficulty in the neonate. We report a case of 1 month old female child with giant vallecular cyst and its co-presentation with laryngomalacia. Marsupialization of the vallecular cyst was done with Laryngeal skimmer blade. Respiratory and feeding difficulty improved after surgical Intervention. The case is being presented to highlight the anesthetic and surgical problems encountered in managing such lesion in neonate.

Keywords: Giant vallecular cyst; Laryngomalacia; Stridor; Failure to thrive

Introduction

Vallecular cysts are rare but are well recognized cause of upper airway obstruction and death in infancy or immediately after birth [1]. Vallecular cyst synchronous with laryngomalacia is even rare. A mortality rate of 40% in children has been reported in the English literature [2]. Vallecular cysts are usually unilocular cystic mass of variable sizes arising from the lingual surface of epiglottis and contain clear fluid [3]. They usually present with severe inspiratory stridor and failure to thrive and require urgent surgical intervention. They may also present challenges to the anaesthetist as bag and mask ventilation and intubation might be difficult. A coordinated approach between surgeons and anaesthetist is must for successful outcome.

We report a case of large vallecular cyst in neonate and highlight the surgical and anaesthetic difficulties encountered in managing such lesions.

Case Presentation

An urgent otolaryngology consultation was sought by the NICU for a 28 day old female baby who had presented with complaints of noisy breathing and feeding difficulty since 8 days of birth. She also had weak cry. She also had history of intermittent episodes of severe respiratory distress with cyanotic spells which was relieved partly on changing to prone position. She also had difficulty in feeding with failure to thrive. There no history of fever or cough. The child was born full term cesarean delivery in local hospital with birth weight of 2 Kg.

On examination, child had inspiratory stridor; she was tachypnoeic with respiratory rate of 54/min and SPO₂-90%. There was in drawing of suprasternal notch and intercostal spaces and accessory muscles of respiration were active. Direct Laryngoscopy was done to assess the airway under sedation, showed cystic lesion in the region of vallecula obstructing the airway. Computed tomographic scan of neck region was done which showed well defined cystic lesion of 3x3 cm in the occupying the vallecula pushing the epiglottis. Rest of the airway was

normal (Figure1).

She was planned for microlaryngoscopy and marsupialization of cyst with Laryngeal microdebrider. Initially Bag and mask ventilation was tried but child was obstructing. Anticipating difficult intubation, the cyst was first aspirated under sedation with 16 gauge needle and 5 cc mucous secretions were sucked out. A guide wire was then passed below the epiglottis through glottis over which 3.5 no. endotracheal tubes was railroaded and guide wire was removed. Using skimmer laryngeal blade the cyst was de capped and marsupialization and inner surface of cyst was cauterized with electrocautery. The aryepiglottic folds were divided using micro laryngeal scissor for laryngomalacia.

The child was extubated on the same day and was kept in ICU for 48hrs for observation. The stridor subsided after 72 hrs and SPO₂ was 98-100%. She was accepting breast feeds. She was discharged after 7 days from the hospital (Figure 2). She was followed up for 6 months and there was no stridor and had started gaining weight.

Discussion

Cysts of larynx and vallecula are rare lesion but they are recognized causes of airway obstruction and death in neonatal and infants. Vallecular cysts have been reported in literature as mucous retention cyst, epiglottic cyst, and as ductal cysts [3]. Vallecular cysts are mucous retention cyst arising due to obstruction of mucous

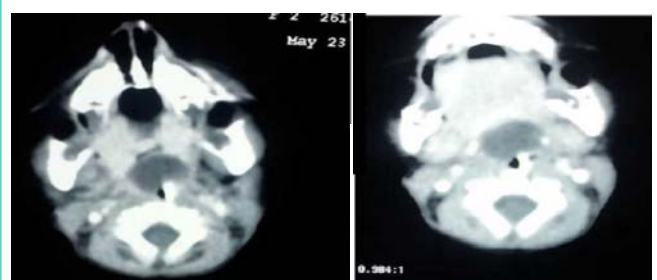


Figure 1: Computed tomography scan of neck showing cystic lesion 3x3 cm in the vallecula.

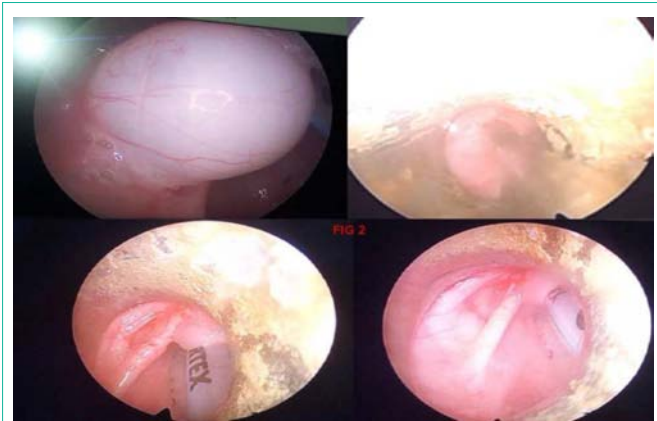


Figure 2: Showing giant vallecular cyst and its removal with laryngeal skimmer blade.

glands at the base of tongue. Vallecular cysts are unilocular cyst lined by squamous epithelium and rarely columnar epithelium. Vallecular cysts commonly occur in the lingual surface of epiglottis, vallecula or aryepiglottic folds.

Differential diagnosis of cyst in vallecula includes lymphatic venous malformation of neck which includes cystic hygroma [4], capillary and cavernous hemangioma of the neck, branchial cleft cyst [5], thyroglossal duct cyst [6] and lingual teratoma, congenital epulis and congenital Ranula. Ultrasound of the neck and MRI can help to differentiate these lesions preoperatively. The widespread use of antenatal ultrasound examination at 28 weeks can lead to earlier diagnosis of vallecular cysts and allows for appropriate counseling and preparation of delivery at higher centre with facilities emergency tracheostomy and ventilation of neonate are available [7].

Vallecular cyst in neonates and infants present with respiratory stridor and failure to thrive. Careful evaluation of the child should be done to assess the airway. Flexible fiberoptic laryngoscopy can be done to look for the size and site of cyst and to evaluate the rest of laryngeal structures. We did not resort to flexible fiberoptic laryngoscopy in our case as the child was in severe stridor and there was risk of further airway compromise. So computed tomography of the neck was done to assess the rest of airway.

Vallecular cyst in neonate and infants can be challenging for anesthetist. It is important to expect difficulty with the airway and be prepared to overcome lesions that may make bag mask ventilation

and endotracheal intubation difficult. The cyst may rupture during intubation and may lead to aspiration. Various options in such cases could be prior decompression of cyst by aspirating, positioning the patient favorably prior to intubation, guided intubation, awake fiber optic intubation [8].

The treatment of choice of vallecular cyst is marsupialization, a relatively simple surgical procedure with an excellent cure rate and minimal morbidity [9]. Marsupialization of cyst is best done with CO₂ Laser. However cyst can also be marsupialized with electrocautery unit. In our case the cyst was decapped and marsupialized with laryngeal skimmer blade. Co existent laryngomalacia was managed by excising the aryepiglottic folds. There have been reports in literature of vallecular cyst with coexistent laryngomalacia which improved after removal of the cyst [10].

References

1. Wong KS, Li HY, Huang TS. Vallecular cyst synchronous with laryngomalacia: presentation of two cases. *Otolaryngol Head Neck Surg.* 1995; 113: 621-624.
2. LaBagnara J Jr. Cysts of the base of the tongue in infants: an unusual cause of neonatal airway obstruction. *Otolaryngol Head Neck Surg.* 1989; 101: 108-111.
3. Gutiérrez JP, Berkowitz RG, Robertson CF. Vallecular cysts in newborns and young infants. *Pediatr Pulmonol.* 1999; 27: 282-285.
4. Mahboubi S, Gheyi V. MR imaging of airway obstruction in infants and children. *Int J Pediatr Otorhinolaryngol.* 2001; 57: 219-227.
5. LaBagnara J Jr. Cysts of the base of the tongue in infants: an unusual cause of neonatal airway obstruction. *Otolaryngol Head Neck Surg.* 1989; 101: 108-111.
6. Urao M, Teitelbaum DH, Miyano T. Lingual thyroglossal duct cyst: a unique surgical approach. *J Pediatr Surg.* 1996; 31: 1574-1576.
7. Cuillier F, Samperiz S, Testud R, Fossati P; Department of Obstetrics and Gynecology, Félix Guyon Hospital, Reunion Island. Antenatal diagnosis and management of a vallecular cyst. *Ultrasound Obstet Gynecol.* 2002; 20: 623-626.
8. Kariya N, Nishi S, Funao T, Nishikawa K, Asada A. Anesthesia induction for a difficult intubation infant with a laryngeal cyst. *J Clin Anesth.* 2003; 15: 534-536.
9. LaBagnara J Jr. Cysts of the base of the tongue in infants: an unusual cause of neonatal airway obstruction. *Otolaryngol Head Neck Surg.* 1989; 101: 108-111.
10. Manor Y, Buchner A, Peleg M, Taicher S. Lingual cyst with respiratory epithelium: an entity of debatable histogenesis. *J Oral Maxillofac Surg.* 1999; 57: 124-127.