

Research Article

Improvements in Sleep Disordered-Breathing after Surgical Removal of Adenoids and/or Tonsils

Motiee-Langroudi M, Saedi B*, Safavi A, Amali A and Jahandideh H

Department of Otolaryngology, Tehran University of Medical Sciences, Iran

*Corresponding author: Babak Saedi, Department of Otolaryngology, Otolaryngology Research Center, Imam Khomeini Medical Center, Tehran University of Medical Sciences, Bagherkhan Street, Chamran Highway, Postal Code: 141973141, Tehran, Iran

Received: November 07, 2014; Accepted: September 08, 2015; Published: September 11, 2015

Abstract

Introduction: Sleep disordered-breathing, with snoring as a problem in this category, is caused by elevated upper airways resistance, which is usually due to airways narrowing or collapse. Adenoid and tonsils, as lymphoid components of nasopharynx and oropharynx respectively, can narrow airways while hypertrophied and this may cause obstruction. In this study we aimed to investigate that how effectively the surgical removal of these components would improve sleep disordered-breathing.

Materials and Methods: Ninety-six children, all positive for snoring and/or mouth breathing due to adenotonsillar hypertrophy that have indication of adenoidectomy or tonsillectomy entered to the study. A VAS (visual analogue scale) with scoring from 0 (for no snoring) to 10 (severe snoring that can be heard from next room) was used for snoring evaluation while mouth-breathing was evaluated based on the frequency of presence (0 for negative, 1 for occasional and 2 if it is permanent). The patients were assessed for their symptoms once at the pre-op visit and twice at three weeks and three months after operation and the results were compared. Their baseline-characteristics, presenting symptoms, the surgical procedures, complications and days of hospitalization were also taken into account.

Results: With a mean age of 5.84 (SD=1.2) and a 1.6:1 male to female ratio, the surgical removal of adenoids/tonsils could significantly improve both snoring and mouth-breathing ($p=0.023$) and ($p=0.037$) at 3 months after operation, averagely making a six unit improvement in snoring scores and reducing mouth-breathing from over 70% positive cases to less than 34%. Of course improvement of snoring happened sooner ($p=0.031$ at 3 weeks for snoring, but mouth breathing needed more time to reduced ($p=0.247$ at 3 weeks).

Conclusion: Surgical removal of adenoids/tonsils in symptomatic patients can significantly improve both snoring and mouth-breathing in sleep disordered-breathing children.

Keywords: Sleep disordered-breathing; Surgical removal; Adenoids; Snoring; Tonsils

Introduction

“Snoring”, defined as the noise made by the vibration of upper airways components [1] during sleep, represents a problem from a variety of sleep-related respiratory problems known as “sleep disordered-breathing”. In sleep disordered-breathing, the resistance of upper airways is elevated [2] which disturbs the normal airflow, and according to the location where the airflow is disturbed [3], patients may present with a wide range of symptoms from simple snoring to severe forms of obstructive sleep apnea [4]. Although simple snoring may not cause serious physical health issues [5] in adults, more severe forms of sleep disordered-breathing have been reported to have deleterious effects on general health and leading to multi-organ morbidity [2,6]. That's while snoring in children is suspicious to cause neurocognitive deficits, language and verbal skills problems, impaired attention, low memory and intelligence, and also raising concerns about successful academic and developmental progress [4,7-9]; furthermore, children who snore are at increased risk for pulmonary hypertension [10]. Thus, with these vast morbidities, sleep

disordered-breathing seems to be of enough importance to undergo detailed investigation. Pathophysiologically, two general processes are addressed to alter breathing during sleep:

Airway collapse: In oropharynx, as a unique anatomical feature in humans [11], with a muscular wall, soft palate and intra-luminal components like the tongue and uvula [12], the airway sustainment requires a specific muscular tonus all the time. This tonus is usually preserved while awake, maybe via a conscious process; but the fact that these problems occur during sleep [13] implies that there may be a problem in non-conscious airways sustainment. There are mechanical receptors in the upper airways [13,14] to sense the pressure, and while stimulated, with a certain delay, they activate the reflex muscles. This keeps the upper airways open. Accordingly, impairments in detection of mechanical stimuli [14], increased latency of the reflex muscle activation, reduced strength of the reflex [13], and inability of muscular control [15], all can lead to airway collapse which represents ineffective neuromuscular functioning during sleep.

Airway narrowing: Narrowing of upper airways may be due to abnormalities of upper airways [16]. Many factors can impact on the upper airways calibrations. The supine position that significantly reduces retro-palatal space [17]; the para-pharyngeal fat pads affect on the airways calibration [18], the respiration process itself alters the airways, while narrowing of the airways (predominantly lateral walls) at the end of expiration and beginning of inspiration has been thought to have a role in snoring [18]. By the way specific areas of the pharynx (particularly the tip of soft palate and 1cm distal to it) have been reported to be significantly associated with snoring [17]. Pharyngeal masses, on the other hand, with any origin, like tonsils, adenoids, malignancies, etc., basically narrow the upper airways unless compensatory processes overcome the space shortage.

Based on the pathological processes, the appropriate treatments may be indicated. Oral appliances or implant-retained appliances in edentulous patients [19,20] (sometimes with orofacial complications) [12,21], electrical stimulation of mouth floor muscles, reconstructive surgeries, radiofrequency, uvulopalatopharyngoplasty (UPPP), laser assisted uvuloplasty (LAUP), palatal implants, NCPAP (nasal continuous positive airway pressure), hyoid suspension, mandibular osteotomy, and multi-level surgery concepts [3,5,22] in adults; while adenotomies, tonsillotomies, tonsillectomies or adenotonsillectomies are the treatments with most benefits for children [23,24].

Although surgical removal of adenoids and tonsils are accepted or even indicated treatments in children with symptomatic hypertrophies of these structures [23,24] and these treatments have been reported to appropriately resolve majority of their symptoms [23,25], there are suggestions that tonsillectomy (with or without adenoidectomy) does not necessarily reduce the likelihood of snoring and their effect on mouth breathing is unclear [24]. In this study, we conducted a large prospective survey in which snoring children with hypertrophied adenoids and tonsils underwent surgical removal of these components, and were evaluated at intervals for improvements in their baseline symptoms, so that we could investigate the short-term efficacy of these surgeries to improve sleep disordered-breathing.

Materials and Methods

Through a prospective cross-sectional study from 2010 to 2011, 96 children – aged 3 to 15 yrs - with symptomatic hypertrophy of adenoids and/or tonsils were selected among those referred to ENT clinic of Imam Khomeini hospital (a tertiary healthcare center and an affiliate of Tehran University of Medical Sciences (TUMS)) and entered to the study. All the participants had positive history of severe snoring and/or mouth breathing and indicated to undergo surgical resection of their adenoids/tonsils. Cases with reactive adenitis/tonsillitis responding to medical treatments, upper airways malignancies, prior surgical manipulations of adenoids/tonsils, patients with Down's syndrome or Mucopolysaccharidosis and those beyond the qualified age limits of the study (3-15y) were excluded. The study was approved by ethics board of the TUMS and all the aspects were conducted according to declaration of Helsinki. Patients' parents also agreed that their children participate in the study by signing our printed informed consent. A 0 to 10 scoring scale was presented to the participants or their parents and they were asked to appropriately give a score to the severity of their snoring. In this scale, 0 stood for the absence of snoring (which according

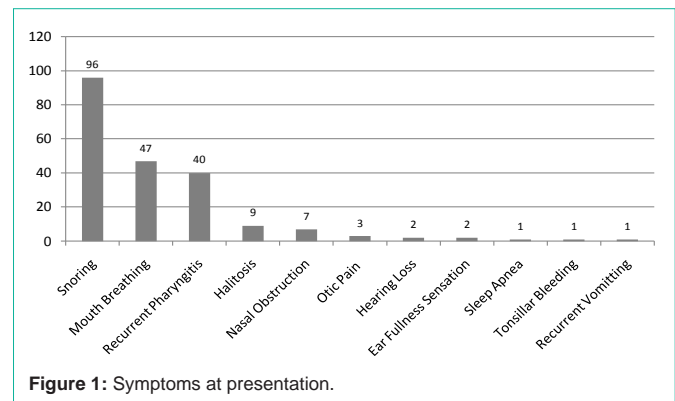


Figure 1: Symptoms at presentation.

to our inclusion criteria no one would earn that), and 10 stood for the most severe form of snoring which had to be audible by parents from a next-door room. Mouth-breathing was also evaluated based on the frequency of its presence. The patients were categorized into three groups: those without (score 0), those with occasional presence (score 1) and those with permanent presence of mouth-breathing (score 2). Adenoidectomy, tonsillectomy, or adenotonsillectomy due to hypertrophy of their adenoids/tonsils; was performed in patients. By the way, further procedures were indicated in some patients (like myringotomy ...) in addition to their adenoids/tonsils removal. Both snoring scores and mouth-breathing severity were evaluated at three weeks and three months postoperative sessions. The patients were evaluated for both intra-operative and post-operative complications. The data were analyzed using SPSS 19. Comparative results were tested by (t-test and *Chi-2*) and *P*-values of or less than 0.05 were considered to be significant.

Results

A total of 96 children, aged 3 to 15 yrs (mean=5.84; SD=1.2) entered to the study; of them, 60 (62.5%) were male and 36 (37.5%) were female. Majority of our patients were aged less than five, as 67 (69.8%) were between three and five; 17 (17.7%) were between six to 10; and 12 (12.5%) were over 10. Snoring history was positive in all participants, while mouth-breathing and recurrent pharyngitis were the next frequent complaints. Figure 1 shows the variety of presenting symptoms. Eighty one patients (84.3%) had only adenoidectomy, tonsillectomy, or adenotonsillectomy procedures, while 15 (15.7%) had further operations in addition to their adenoids/tonsils removal. Table 1 outlines the scope of procedures performed on our case-series.

As shown in Table 2, snoring scores were improved from pre-op status to post-op intervals, at 3 weeks ($p=0.031$) and 3 months ($p=0.023$) meaning that surgical resection of adenoids/tonsils could significantly improves snoring. But the rate of snoring improvement was not significant between 3 weeks and 3 months ($p=0.769$).

Mouth-breathing also was significantly improved after the surgery ($p=0.037$ at 3 months after surgery). In contrast to snoring, improvement of mouth-breathing took longer ($p=0.247$ at 3 weeks and $p=0.037$ at 3 months after surgery). Table 3 explains how these changes have happened.

Four cases (4.16%) ended up in complications; one with hypernasal speech, one with mild hemorrhage at the surgery site (no

Table 1: The variety of surgical procedures performed on this case series.

Procedure	Frequency (%)
Adenotonsillectomy	66 (68.75)
Tonsillectomy	8 (8.33)
Adenoidectomy	7 (7.29)
Tonsillectomy + Bilateral VT Insertion	5 (5.20)
Adenotonsillectomy + Myringotomy	5 (5.20)
Adenoidectomy + Septoplasty	2 (2.08)
Adenotonsillectomy + Septoplasty	1 (1.04)
Tonsillectomy + FESS	1 (1.04)
Adenoidectomy + Bilateral VT Insertion	1 (1.04)
Total	96 (100)

FESS: Functional Endoscopic Sinus Surgery; VT: Ventilation Tube

further operation needed), and two with severe post-surgical pain.

Eighty nine patients (92.7%) stayed at the hospital for only 24 hours, while four (4.16%) stayed for two days, and three (3.12%) for more than two days. The latter group with longer hospital stays had either a post-surgical complication or had undergone a further procedure in addition to their adenoids/tonsils removal.

Discussion

Adenoids and tonsils, as upper airways components, are respectively located in the nasopharynx and oropharynx. While hypertrophied, these structures can narrow their local airways due to their space-occupying nature. The effect of nasopharyngeal lesions on airways function may cause a shift in normal air passage, particularly leading to mouth-breathing, and though with its own orofacial and cosmetic consequences (due to chronic mouth breathing) [26]. Contrary to nasopharynx structure, oropharynx is an area surrounded by a muscular wall and few intra-luminal components (tongue, uvula, and partially the soft palate) giving the area the propensity to collapse if muscular tonus is impaired; this may occur during sleep [13]. The surgical removal of tonsils, with or without adenoidectomy, theoretically can widen the airway, facilitating the airflow, breathing, and resolving majority of symptoms, but the surgery does not necessarily correct the local neuromuscular functioning, meaning that these procedure do not reduce the likelihood of becoming a snorer [24]. This conveys that sleep disordered-breathing is more a multi-factorial problem than a simple altered airway calibration.

In this study, with all our patients being positive for snoring, and also all medically indicated for adenoidectomy, tonsillectomy, or adenotonsillectomy (some with concomitant procedures), we had a large sample to investigate whether the surgical removal of these space-occupying lesions could improve the snoring status in children with sleep disordered-breathing. Our study confirms the fact that the surgery can significantly reduce sleep disordered-breathing, as over 87% of our patients had scores ≤ 3 while they (or their parents) evaluated their snoring status three months after the surgery, meaning that the surgery could reduce the mean snoring score approximately up to 6 units (Table 2). The surgery also could significantly improve mouth-breathing, as over 70% of patients were reported to have episodes of mouth-breathing preoperatively, while over 66% reached to a negative condition for mouth-breathing episodes three months

Table 2: Pre- and post-op snoring scores for snoring.

Snoring Score Range	Frequency (%)	Mean
Pre-Op		
0 to 3	7 (7.29)	7.35
4 to 7	15(15.62)	
8 to 10	74 (77.08)	
Post-Op Week 3		
0 to 3	71 (73.95)	2.6
4 to 7	6 (6.25)	
8 to 10	19 (19.79)	
Post-Op Month 3		
0 to 3	84 (87.5)	1.4
4 to 7	5 (5.20)	
8 to 10	7 (7.29)	

Table 3: Pre- and post-op mouth-breathing status.

Mouth-Breathing Status(score)	Frequency (%)
Pre-Op	
Permanent(2)	34 (35.41)
Occasional(1)	34 (35.41)
Negative(0)	28 (29.16)
Post-Op week 3	
Permanent(2)	28 (29.16)
Occasional(1)	39 (40.62)
Negative(0)	29 (30.20)
Post-Op month 3	
Permanent(2)	20 (20.83)
Occasional(1)	12 (12.50)
Negative(0)	64 (66.66)

after the surgery (Table 3). Our study also showed that improvement of mouth-breathing took longer than snoring. So the patient's parents must be patient for elimination of mouth-breathing and sometimes it will continue.

Although we emphasize that snoring in children is more likely to be a multi-factorial phenomenon, because some children still snored after surgery, this study showed that the surgical removal of adenoids and tonsils can significantly improve disordered-breathing during sleep.

Lower rates of pharyngeal neuromuscular malfunctioning in children, somehow purified our study sample to focus on the absolute role of adenoids/tonsil hypertrophy in development of snoring, but it should be noted that the presence of snoring during sleep and its absence while being awake, signals that there may be degrees of neuromuscular malfunctioning even in children at early ages. In addition to this, maybe degrees of pharyngeal muscle relaxation during sleep can be considered as a natural phenomenon normally not precipitating in airways collapse, but the existence of hypertrophied adenoids/tonsils in the airway, more effectively narrows the airways which are already relaxed for sleep conditions. Furthermore, snoring and adenotonsillar hypertrophy seem to have a binary effect on each other, as the vibration made by snoring triggers local inflammatory processes [27] which contributes to adenotonsillar hypertrophy and also by alteration of muscular reflexes increases the propensity of airway to obstruct during sleep [2]; that's while snoring itself is sometimes caused by the hypertrophied adenoids or tonsils. Such an effect can also be observed about some of the concomitant surgical procedures with adenoid/tonsil removal, as the tympanostomy tube insertion (TTI) is occasionally indicated in otitis media cases with effusion; this procedure is usually accompanied by the surgical removal of adenoids/tonsils, while there are reports that isolated TTI in children increases the risk for adenotonsillectomy and even snoring [28].

All these facts necessitate meticulous examination of snoring patients by appropriate diagnostic modalities. Nasopharyngeal endoscopy is very useful and should be done in every patient if he or she is cooperative. Lateral encephalography or adenoid view also helps in some patients. Fujioka [29] and Close [30] mentioned that adenoid-nasopharyngeal ratio in these plain X-ray graphics correlated with patient's syndromes. Computed tomography (CT), magnetic resonance imaging (MRI) maybe used but are not routine imaging modalities [31,32].

While the diagnosis is established, early management of sleep disordered-breathing should be considered and emphasized in children, because these problems put them at risk for neurocognitive deficits [4,7-9]. Several processes through which neurocognitive deficits may occur are proposed; mild changes in oxygen saturation or increased respiratory arousals are thought to have a great effect on neurocognitive function [8], on the other hand these deficits may be due to the chronicity of disrupted sleep during the ages of rapid neurological development [8]. In a study, snoring children, without a significant change in oxygen saturation rates showed lower scores on a standard development assessment [9] meaning that snoring deleterious effects are not necessarily attributable to the oxidative stress due to disturbed breathing itself, and that conveys other processes may also play a role. Another study described that certain physiological disturbances in these children lead to prefrontal cortex dysfunction [7] which subsequently alters their language and verbal skills. Furthermore, increased risk for development of otitis media with effusion (OME) due to hypertrophied adenoids/tonsils, can lead to impaired voice conduction, and chronic presence of effusion in the middle ear can alter voice perception which also would impact on their language and verbal skills if left untreated. To rule out hearing alterations due to middle ear effusions, pure tone audiometry or tympanometry should be considered [33-35].

Although the reversibility of these neurocognitive deficits in children is questionable even after appropriate treatments [8], we strongly recommend the early treatment and intervention, since even if the treatment does not improve the already altered neurocognitive condition, it prevents its further progress.

Conclusion

Although sleep disordered-breathing seems to be a multi-factorial problem, surgical removal of hypertrophied adenoids/tonsils in children with sleep disordered-breathing can significantly improve both snoring and mouth-breathing.

References

- Valbuza JS, Oliveira MM, Conti CF, Prado LB, Carvalho LB, Prado GF. Methods to increase muscle tonus of upper airway to treat snoring: systematic review. *Arq Neuropsiquiatr*. 2008; 66: 773-776.
- Gozal D, Kheirandish L. Oxidant stress and inflammation in the snoring child: confluent pathways to upper airway pathogenesis and end-organ morbidity. *Sleep Med Rev*. 2006; 10: 83-96.
- Utley DS, Shin EJ, Clerk AA, Terris DJ. A cost-effective and rational surgical approach to patients with snoring, upper airway resistance syndrome, or obstructive sleep apnea syndrome. *Laryngoscope*. 1997; 107: 726-734.
- Blunden S, Lushington K, Kennedy D, Martin J, Dawson D. Behavior and neurocognitive performance in children aged 5-10 years who snore compared to controls. *J Clin Exp Neuropsychol*. 2000; 22: 554-568.
- Verse T. Reconstructive procedures for disturbed functions within the upper airway: pharyngeal breathing/snoring. *GMS Curr Top Otorhinolaryngol Head Neck Surg*. 2005; 4: Doc08.
- Coleman J. Complications of snoring, upper airway resistance syndrome, and obstructive sleep apnea syndrome in adults. *Otolaryngol Clin North Am*. 1999; 32: 223-234.
- Andreou G, Agapitou P. Reduced language abilities in adolescents who snore. *Arch Clin Neuropsychol*. 2007; 22: 225-229.
- Kennedy JD, Blunden S, Hirte C, Parsons DW, Martin AJ, Crowe E, et al. Reduced neurocognition in children who snore. *Pediatr Pulmonol*. 2004; 37: 330-337.
- Montgomery-Downs HE, Gozal D. Snore-associated sleep fragmentation in infancy: mental development effects and contribution of secondhand cigarette smoke exposure. *Pediatrics*. 2006; 117: e496-502.
- Wilkinson AR, McCormick MS, Freeland AP, Pickering D. Electrocardiographic signs of pulmonary hypertension in children who snore. *Br Med J (Clin Res Ed)*. 1981; 282: 1579-1581.
- Goldberg R, Grandi E. When a snore means more. *AHIP Cover*. 2008; 49: 50-51.
- Moghadam BK, Yousefian JZ. Orofacial complications associated with forward repositioning of the mandible in snore guard users. *Gen Dent*. 2003; 51: 544-547.
- Huang L, Williams JE. Neuromechanical interaction in human snoring and upper airway obstruction. *J Appl Physiol* (1985). 1999; 86: 1759-1763.
- Kimoff RJ, Sforza E, Champagne V, Ofiara L, Gendron D. Upper airway sensation in snoring and obstructive sleep apnea. *Am J Respir Crit Care Med*. 2001; 164: 250-255.
- Boot H, van der Meche FG, Poublon RM, Bogaard JM, Gainai AZ, Schmitz PI. Upper airway patency and nocturnal desaturation in habitual snoring and obstructive sleep apnea: pathogenesis of sleep-related breathing disorders. *Eur Neurol*. 1996; 36: 206-210.
- Hoffstein V, Chaban R, Cole P, Rubinstein I. Snoring and upper airway properties. *Chest*. 1988; 94: 87-89.
- Hoffstein V, Weiser W, Haney R. Roentgenographic dimensions of the upper airway in snoring patients with and without obstructive sleep apnea. *Chest*. 1991; 100: 81-85.
- Akan H, Aksöz T, Belet U, Sesen T. Dynamic upper airway soft-tissue and caliber changes in healthy subjects and snoring patients. *AJNR Am J Neuroradiol*. 2004; 25: 1846-1850.
- Flanagan D. A dual-laminate snore reduction appliance: a report of four cases. *Gen Dent*. 2010; 58: e156-161.
- Lindblom SS. Adults who snore. *Postgrad Med*. 1997; 101: 171-172, 174, 183-4 passim.
- Battagel JM, Kotecha B. Dental side-effects of mandibular advancement splint wear in patients who snore. *Clin Otolaryngol*. 2005; 30: 149-156.
- Pépin JL, Veale D, Mayer P, Bettiga G, Wuyam B, Lévy P. Critical analysis of the results of surgery in the treatment of snoring, upper airway resistance syndrome (UARS), and obstructive sleep apnea (OSA). *Sleep*. 1996; 19: S90-100.
- [No authors listed]. Snoring children, sleep apnoea, and tonsillectomy. *Drug Ther Bull*. 1992; 30: 6-7.
- Tzifa KT, Shehab ZP, Robin PE. The relation between tonsillectomy and snoring. *Clin Otolaryngol Allied Sci*. 1998; 23: 148-151.
- Stradling JR, Thomas G, Warley AR, Williams P, Freeland A. Effect of adenotonsillectomy on nocturnal hypoxaemia, sleep disturbance, and symptoms in snoring children. *Lancet*. 1990; 335: 249-253.
- Cattoni DM, Fernandes FD, Di Francesco RC, De Latorre Mdo R. Quantitative evaluation of the orofacial morphology: anthropometric measurements in healthy and mouth-breathing children. *Int J Orofacial Myology*. 2009; 35: 44-54.

27. Almendros I, Acerbi I, Puig F, Montserrat JM, Navajas D, Farré R. Upper-airway inflammation triggered by vibration in a rat model of snoring. *Sleep*. 2007; 30: 225-227.
28. Tauman R, Derowe A, Ophir O, Greenfeld M, Sivan Y. Increased risk of snoring and adenotonsillectomy in children referred for tympanostomy tube insertion. *Sleep Med*. 2010; 11: 197-200.
29. Fujioka M, Young LW, Girdany BR. Radiographic evaluation of adenoidal size in children: adenoidal-nasopharyngeal ratio. *AJR Am J Roentgenol*. 1979; 133: 401-404.
30. Close HL, Kryzer TC, Nowlin JH, Alving BM. Hemostatic assessment of patients before tonsillectomy: a prospective study. *Otolaryngol Head Neck Surg*. 1994; 111: 733-738.
31. Faber CE, Grymer L. Available techniques for objective assessment of upper airway narrowing in snoring and sleep apnea. *Sleep Breath*. 2003; 7: 77-86.
32. Suzuki M, Saigusa H, Chiba S, Hoshino T, Okamoto M. Prevalence of upper airway tumors and cysts among patients who snore. *Ann Otol Rhinol Laryngol*. 2007; 116: 842-846.
33. [No authors listed]. Sensitivity, specificity and predictive value of tympanometry in predicting a hearing impairment in otitis media with effusion. MRC Multi-Centre Otitis Media Study Group. *Clin Otolaryngol Allied Sci*. 1999; 24: 294-300.
34. Dempster JH, MacKenzie K. Tympanometry in the detection of hearing impairments associated with otitis media with effusion. *Clin Otolaryngol Allied Sci*. 1991; 16: 157-159.
35. Kazanas SG, Maw AR. Tympanometry, stapedius reflex and hearing impairment in children with otitis media with effusion. *Acta Otolaryngol*. 1994; 114: 410-414.