

## Research Article

# A Cause of Reversible Deafness: Silicone Earplugs

Shakeel M<sup>1\*</sup>, Keh S<sup>1</sup>, Maini S<sup>2</sup> and Jones S<sup>1</sup><sup>1</sup>ENT Department, Ninewells Hospital, UK<sup>2</sup>ENT Department, Aberdeen Royal Infirmary, UK

**\*Corresponding author:** Muhammad Shakeel, Department of Otolaryngology-Head & Neck surgery, Ninewells Hospital, Dundee, DD1 9SY, UK

**Received:** February 07, 2015; **Accepted:** March 04, 2015; **Published:** March 06, 2015

**Abstract**

**Introduction:** Because of the tortuous nature of the EAC, a broken earplug may become impacted and result in reduced hearing along with other symptoms. Our aim is to raise awareness that impacted earplugs can be a cause of both acute and chronic hearing loss.

**Materials and Methods:** We have managed 15 patients presenting with hearing loss secondary to an impacted earplug in the EAC over a 3 years period. Prospectively, the information was collected on demographics, symptomatology, indication for earplug use, laterality of the affected ear, examination findings, earplug type, prior attempts to remove the earplug and the outcome of our interventions. Thirteen patients became aware of the hearing loss soon after the earplug impaction. The earplug was removed by an experienced otolaryngologist and the patients reported resolution of their symptoms. Two of the patients complaining about ongoing hearing loss affecting one ear were unaware of the fact that they had part of the earplug impacted in the external canal.

**Discussion:** Once a patient is found to have an earplug impaction, an experienced otolaryngologist should attempt its removal as their removal can be difficult without adequate equipment which includes microscope and fine ear instruments. The dough like consistency of these plugs means that they are difficult to remove with forceps or suction.

**Conclusion:** Broken earplugs forgotten in the EAC can lead to chronic hearing loss and may pose a diagnostic challenge. If suspected to have an impacted earplug referral to an otolaryngologist would be appropriate.

**Keywords:** External auditory canal; Silicone; Ear plugs; Microscope

## Introduction

Earplugs are devices often used by patients to block the external auditory canal (EAC) to avoid annoying noise. Earplugs are also used to prevent water intrusion in the ears during swimming. They may be broadly grouped into three categories based on the material used to make it: foam plugs, silicone plugs and wax and cotton fibre plugs. Silicone earplugs can be mouldable or pre-moulded and are available in different colours. These offer a noise reduction rating (NRR) of 22 to 33, which is effective in most demanding noise situations. Because of the tortuous nature of the EAC, a broken earplug may become impacted and result in reduced hearing along with other symptoms. The general practitioners unfamiliar with silicone ear plugs may not recognize the impacted plugs in the ear canal. Similarly, an attempted removal of an impacted silicone ear plug without the use of microscope and fine ear instruments may lead to complications. So the aim of this educational article is to raise awareness among general practitioners that impacted earplugs can be a cause of both acute and chronic hearing loss. We also recommend that an experienced otolaryngologist should remove a deeply impacted earplug to minimize trauma to the EAC.

## Materials and Methods

The authors have managed 15 patients presenting with hearing loss secondary to an impacted earplug in the EAC over a 3 years period (Table 1). Prospectively, the information was collected on demographics, symptomatology, indication for earplug use, laterality

of the affected ear, examination findings, earplug type, prior attempts to remove the earplug and the outcome of our interventions. The data was collected and analysed using Microsoft Excel. We describe some of the cases in detail below.

Thirteen patients became aware of the hearing loss soon after the earplug impaction. Three patients also complained of slight dizziness. The earplug was removed by an experienced otolaryngologist and the patients reported resolution of their symptoms.

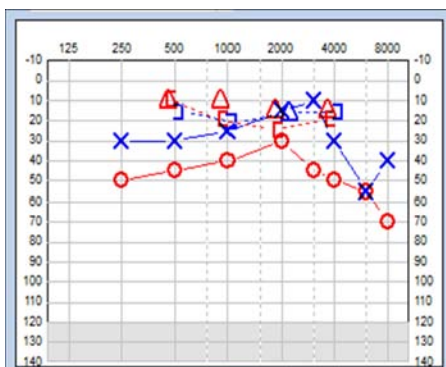
Two of the patients attended their GP complaining about hearing loss affecting one ear, believing some sinister cause for their problem. They were unaware of the fact that they had part of the earplug impacted in the external canal.

One young lady presented with a 2 months history of hearing loss which had failed to improve even after the use of over the counter ear drops aimed at softening the ear wax. On otoscopic examination the GP identified a red foreign body in the EAC of this patient. The impacted silicone earplug was removed under microscopic guidance leading to resolution of her hearing loss.

The second patient had been struggling with impaired hearing loss for 4 months; she had used ear drops to soften suspected wax and undergone syringing with no beneficial effect on hearing loss. When reviewed by her GP, the tympanic membrane was recorded as greyish, featureless and protuberant in the canal. A middle ear or mastoid pathology was suspected. This patient was routinely

**Table 1:** Summary of patients with earplug impaction in the ear (EAC: External auditory canal).

Serial No.	Age	Gender	Side	Previous attempt at plug removal	GA needed	Type of plug	Inflammation of EAC	Topical antibiotics
	24	F	R	Yes	No	Foam	Yes	Yes
	25	M	R	Yes	No	Silicone	Yes	Yes
	28	M	L	Yes	No	Wax	Yes	Yes
	29	F	L	Yes	Yes	Silicone	Yes	Yes
	34	F	L	Yes	Yes	Silicone	No	No
	35	M	R	Yes	No	Silicone	No	No
	56	F	R	Yes	No	Silicone	No	No
	59	F	L	Yes	No	Wax	No	No
	23	M	R	Yes	No	Silicone	No	No
	30	M	R	Yes	No	Silicone	No	No
	24	F	L	Yes	No	Wax	No	No
	20	F	L	No	No	Silicone	Yes	Yes
	66	F	R	No	No	Silicone	Yes	Yes
	59	F	L	No	No	Silicone	No	No
	13	M	R	No	No	Wax	No	No



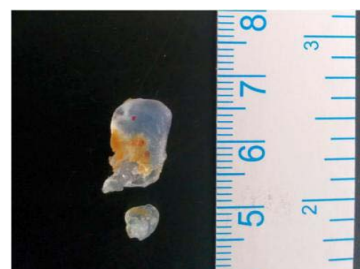**Figure 1:** Pure tone audiogram showing moderate conductive hearing loss affecting the right ear.

referred to our otology clinic where she was found to have moderate conductive hearing loss on pure tone audiometry (PTA) (Figure 1). On otoscopy, a transparent silicone earplug was identified completely occluding the EAC. The earplug was removed in the clinic under microscopic guidance (Figure 2). The patient reported improvement in her hearing, which was confirmed on repeat PTA (Figure 3).

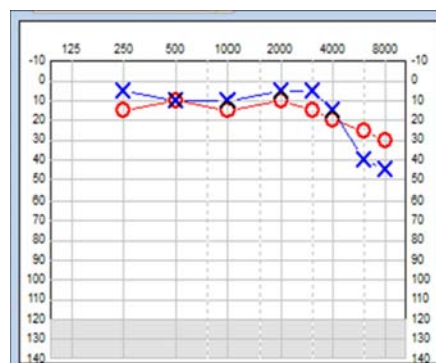
**Discussion**

Acute conductive hearing loss in adults can occur secondary to foreign body impaction in the EAC and commonly reported objects include button batteries, cotton buds, and insects in the EAC. Chronic conductive hearing loss most commonly occurs because of the middle ear pathology. We present a unique aural foreign body “earplug” which caused acute and chronic conductive hearing loss in our series of patients. The majority of impactions are related to silicone plugs which are increasingly used by patients in western hemisphere. All these cases originated in the primary care where our colleagues struggled to identify the underlying pathology but very rightly they referred these patients to our department. Some of these patients had undergone attempted removal of the impacted ear plugs without any success but led to increased patient discomfort, EAC bruising and further displacement of the ear plugs into the deeper part of the ear canal.

A retained earplug in the canal can produce an occlusive effect,



**Figure 2:** Transparent silicone earplug removed from the external auditory canal.

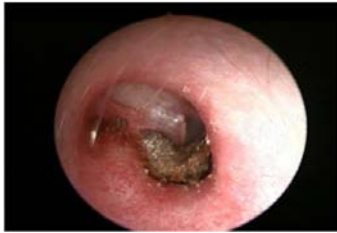

**Figure 3:** Pure tone audiogram confirming normal hearing threshold in the right ear after earplug removal.

leading to conductive hearing loss. This has been demonstrated in a recent study on the effects of foam earplugs inducing a mild, frequency-dependent, conductive hearing loss of 10-38 dB [1]. Unfortunately, 2 of our patients suffered for few months before the right diagnosis of ear plug impaction in the ear canal was made. Both of them reported improvement in hearing after ear plug removal and we believe that an earlier diagnosis and timely intervention would have avoided this unnecessary suffering for our patients.

Not surprisingly, impacted material may push ear wax and other debris deeper into the EAC, creating a favourable environment for otitis externa (Figure 4).

Most of our patients were aware of earplug impaction giving rise



**Figure 4:** Endoscopic view of the right ear showing wax impaction against the tympanic membrane seen after removal of an earplug.

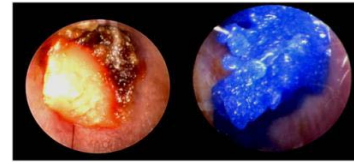
to hearing impairment but two of our patients did not recall having had any problems removing their earplugs. Hence our assertion that patients presenting with hearing impairment with no previous history of ear problems should undergo otoscopic examination and use of earplugs should be established during consultation as some patient might not divulge history of earplug use unless asked specifically.

The majority of earplugs in our cohort of patients were made of silicone. Silicone earplugs can be transparent or coloured (Figure 5). If the earplug is coloured, it is easier to identify during otoscopic examination compared to the transparent earplug.

Once a patient is found to have an earplug impaction, an experienced otolaryngologist should attempt its removal as their removal can be difficult without adequate equipment. The dough like consistency of these plugs means that they are difficult to remove with forceps or suction. Most of the time it will be possible to remove the earplug in an ENT clinic setting but the patient should be counseled about the possible need for general anaesthetic [2].

Ideally, untrained personnel should not attempt removing the aural foreign body. If there have been previous failed attempts at removal patients with an aural foreign body should be referred directly to an otolaryngologist as they are more likely to be managed without general anaesthesia [3]. Another study had reported a complication rate of as high as 77% and 10% of the cases required a general anaesthetic for aural foreign body removal in patients treated by health care professionals other than otolaryngologists [4].

The patients normally report resolution of hearing impairment after earplug removal, as was the case in our cohort study. No other treatment is required following removal of the earplug. However, if



**Figure 5:** Endoscopic view of a pink silicone and a blue wax earplug lodged in the external auditory canals.

there is inflammation of the EAC or tympanic membrane, a short course of topical antibiotic/steroid treatment may be required; 6 of our patients needed topical treatment. All patients settled without any long term sequelae.

## Conclusion

Earplugs are commonly used to block the EAC. The silicone and wax earplugs develop a dough-like consistency because of the increased temperature of the EAC. At times, these earplugs can become lodged in the EAC and lead to acute hearing loss along with other symptoms. Broken earplugs forgotten in the EAC can lead to chronic hearing loss and may pose a diagnostic challenge to a physician unfamiliar with the possible complication. If suspected to have an impacted earplug referral to an otolaryngologist would be appropriate.

## Acknowledgement

We are grateful to our colleagues in the Audiology department for providing us with pure tone audiograms.

## References

1. Eric Lupo J, Koka K, Thornton JL, Tollin DJ. The effects of experimentally induced conductive hearing loss on spectral and temporal aspects of sound transmission through the ear. *Hear Res.* 2011; 272: 30-41.
2. Shakeel M, Carlile A, Venkatraman J, Mountain RE, Maini S. Earplugs presenting as an impacted foreign body in the ear canal. *Clin Otolaryngol.* 2013; 38: 280-281.
3. Thompson SK, Wein RO, Dutcher PO. External auditory canal foreign body removal: management practices and outcomes. *Laryngoscope.* 2003; 113: 1912-1915.
4. Singh GB, Sidhu TS, Sharma A, Dhawan R, Jha SK, Singh N. Management of aural foreign body: an evaluative study in 738 consecutive cases. *Am J Otolaryngol.* 2007; 28: 87-90.