

Review Article

A Systematic Review of the Routine Removal of Syndesmosis Screws in Traumatic Ankle Fractures

Shaunak S^{1*}, Ahmed N² and Singh S²¹Department of Trauma & Orthopaedics, Medway NHS Foundation Trust, United Kingdom²Hichingbroke Hospital, Parkway Hinchbrook, Huntingdon PE29 6NT, United Kingdom***Corresponding author:** Shalin Shaunak, Department of Trauma & Orthopaedics, Medway NHS Foundation Trust, Windmill Road, Gillingham, Kent, ME7 5NY, United Kingdom**Received:** August 08, 2022; **Accepted:** September 01, 2022; **Published:** September 08, 2022

Introduction

The ankle syndesmosis is a critical structure, conferring a great degree of stability to the ankle mortise comprising part of a complex framework of ligaments responsible for 90% of the resistance to lateral displacement of the fibula [1]. The components of the syndesmosis are the Anterior-Inferior Tibiofibular Ligament (AITFL), Posterior-Inferior Tibiofibular Ligament (PITFL), Transverse Tibiofibular Ligament (TTFL) and Interosseous Ligament (IOL).

With approximately one in seven ankle fractures associated with a syndesmotom injury it is a common pattern [2]. The injury itself is most often found intra-operatively after stable fixation of malleolar fractures, indicated by persistent instability. This instability is often dealt with through the use of a bridging syndesmotom screw which restores the ankle mortise, confers stability but leaves the original syndesmotom injury relatively untouched.

There have been numerous biomechanical studies looking at various techniques and methods of fixation. In terms of material used, there does not appear to be a significant difference between titanium, stainless steel or bioabsorbable screws [3]. There does not appear to be a significant difference, biomechanically in terms of level of placement [4], three cortical vs 4 cortical fixation [5] or indeed 3.5mm vs 4.5mm screws [6,7]. There is, however, a biomechanical advantage to two vs one screw fixation [8] particularly in more proximal fracture patterns, i.e. Weber C variants. The biggest prognostic indicator of the efficacy of fixation remains proper anatomical reduction of the syndesmosis prior to fixation, with up to 52% of cases having inadequate reduction on post-operative CT [9,10].

Irrespective of the above, a common technical consideration for syndesmotom screw fixation is whether to remove or retain screws post fixation. Historically, screws were considered to hamper full movement across the tibiofibular articulation as well as potentially restricting full dorsiflexion. This was proposed due to an impairment of normal fibular rotation occurring secondary to syndesmotom widening. Later studies have suggested that this may not be the case, irrespective of retention of either intact or broken screws. This systematic review aims to look in more detail at the need for removal

of screws and consider what the best practise is going forward.

Materials and Methods

A systematic review was conducted on the 10/03/2020 using PRISMA guidelines [11].

The following search terms were used: Ankle fractures; syndesmosis; ankle ligament; bone screws, ankle fixation; transyndesmosis; removal; retention.

These were used in the following databases: Embase, Medline and Conchrane library.

Exclusion criteria: not written in English, duplicate articles.

Inclusion criteria: articles containing ankle syndesmosis fixation with screws with direct comparison of retention vs removal.

These were then scrutinised to evaluate to exclude any articles which did not include Patient Related Outcome Measures (PROM) or review articles and case reports.

Results

The search yielded a total of 512 papers. Of these, 140 were duplicates across the search engines and were removed. Of the remaining articles the above inclusion and exclusion criteria were applied leaving 47 papers in total. These papers were then fully scrutinised as above leaving a total of 17 papers for use in the systematic review.

The papers were then reviewed to ascertain their level of evidence, according to the Oxford Level of Evidence criteria (OLOE). Each was then investigated to reveal the total numbers of both the retention and removal arms. Mean follow-up was also analysed as was mean outcome, looking at functional outcomes via either standardised OMAS (Olerud-Molander Ankle Score) or AOFAS (American Orthopedic Foot Ankle Score) scoring, bar one study where Baird and Jackson scores were available. The Conclusion, looking for functional differences across arms was also scrutinised.

Comparison of OMAS scores: This was discussed in 9 studies but the actual numbers were only provided for 6. The overall primacy differed between studies, with 5 demonstrating favourable results for screw removal a, 2 favouring retention and the others not providing numbers, but stating that the outcomes were not significant. The only paper that demonstrated a statistically significant result (miller) favoured removal, although the exact figures are not revealed.

Comparison of AOFAS scores: These were provided in 8 studies. Across the board, there were no statistically significant differences between the removal and retention arms. In terms of raw numbers, 3 favoured removal, 4 favoured retention and 1 had no difference across arms. One study (Francesco) had results that functional results that contradicted each other, with OMAS favouring removal and

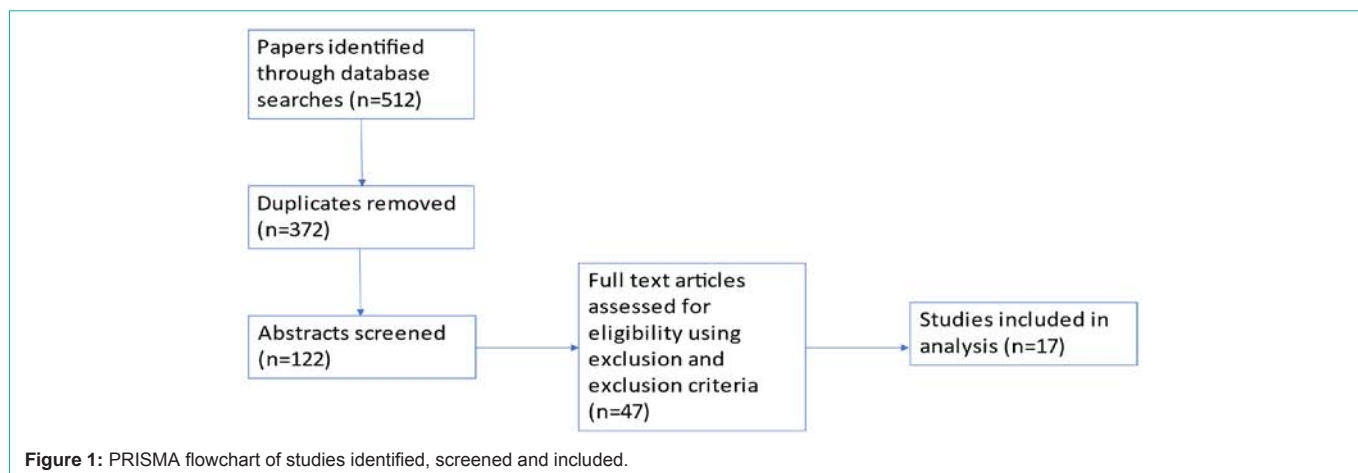


Table 1:

Author & Year Published	Study type	OLOE	Screws Removed	Screws Retained	Mean F/U time (mths)	Mean outcome	Conclusion
Bell et al 2006	Prospective Cohort Study	4	Removal 6-12/52 N = 23	Retention, N = 7 Broken, N = 2 Intact N = 5	15	Baird and Jackson score 88 vs 86 (p = 0.79)	No statistically significant difference
Boyle et al 2014	Randomised Control Trial	2b	Removal >12/52 N = 26	Retention, N= 25 Broken, N = 9 Intact, N = 16	12	OMAS 86.7 vs 82.4 (p = 0.367)	No statistically significant difference
Egol et al 2010	Retrospective Cohort Study	4	Removal >12/52 N = 11	Retention, N= 68 Broken, N = 15 Intact, N = 53	12	AOFAS NP (p = 0.82)	No statistically significant difference
Francesco et al 2019	Retrospective Cohort Study	4	Removal 6-8/52 N = 65	Retention, N = 25 Broken, N = 8 Intact, N= 17	12	AOFAS 94 vs 99 (P = 0.56) OMAS 95 vs 92.5 (p = 0.081)	No statistically significant difference
Heck et al. 2017	Retrospective Cohort Study	4	Removal 12/52 N = 11	Retention, N = 24	6	AOFAS 90.3 vs 87.7 (p = 0.340)	No statistically significant difference
Hamid et al. 2009	Cross-sectional Cohort Study	4	Removal 11-20/52	Retention, N= 37 Broken, N = 10 Intact, N = 27	30	AOFAS 85.8 vs 85.59 (p 0.96)	No statistically significant difference
Hoiness et al 2004	Randomised Control Trial	2b	Removal 9.5/52 N = 30	Retention, N= 34 Broken, N = 3 Intact, N = 31	12	OMAS 83.3 vs 88.8 (p= 0.192)	No statistically significant difference
Kaftandziev et al 2015	Cross Sectional Cohort Study	4	Removal 8-12/52 N = 23	Retention, N= 59 Broken, N = 13 Intact, N = 46	12	AOFAS 83 vs 88.03 (p = 0.043)	Patients with retained screws had PROMs
Kim et al 2016	Randomised Control Trial	2b	Removal 3/12 N = 56	Retention, N = 56 Broken, N = 8 Intact, N = 48	12	AOFAS 75.1 vs 77.07 (p = 0.487)	No statistically significant difference
Kolodziej et al 2010	Cross Sectional Cohort Study	4	Removal 7-22/52 N = 13	Retention, N= 20 Broken, N = 8 Intact, N = 12	37	AOFAS 89 vs 86.2	No statistically significant difference
Manjoo et al 2010	Cross Sectional Cohort Study	4	Removal >40/52 N = 12	Retention, N= 64 Broken, N = 44 Intact, N = 20	23	OMAS 66.80 vs 57.29 (p < 0.001)	Patients with intact screws have worse outcomes than those with removed or broken screws
Miller et al. 2010	Prospective cohort study	4	Removal 12/52 N = 42	Retention, N = 42 (all removed after assessment with screws <i>in situ</i>)	13	OMAS NP but suggested significant improvement after removal (p = 0.003)	Significant improvement after removal of screws
Moon et al. 2020	Retrospective cohort study	4	Removal 12/52 N = 28	Retention, N = 28 Broken, N = 1 Intact, N = 27	>24	AOFAS 75.1 vs 77.07 (0.487)	No statistically significant difference
Moore et al. 2006	Randomised Control trial	2b	Removal 8/52 N = 7	Retention, N= 113 Broken, N = 9 Intact, N = 104	5	OMAS: N/E	No statistically significant difference
Schepers et al 2014	Cross Sectional Cohort Study	4	Removal 8-12/52 N = 44	Retention, N= 12	51	OMAS 73.22 vs 72.92 (p = 0.971)	No statistically significant difference
Tucker et al. 2013	Cross Sectional Cohort Study	4	Removal 10-12/52 N = 43	Retention, N= 20	31	OMAS 75 vs 81.5 (p = 0.107)	No statistically significant difference

Weening et al. 2005	Cross Sectional Cohort Study	4	Removal >9/52 N = 30	Retention, N= 20	18.1	OMAS: N/E	No statistically significant difference
---------------------	------------------------------	---	----------------------	------------------	------	-----------	---

AOFAS vice versa.

Comparison of Baird and Jackson Scores: Only one paper provided this score, favouring removal but with no statistical significance.

Discussion

The decision on whether to remove or retain syndesmosis screws remains a contentious topic. Proponents of screw removal argue that the syndesmosis should have healed by 12 weeks [12] and therefore removal of the screw will allow anatomical restoration of the fibular rotation and syndesmosis widening during the gait cycle.

The reverse arm argues that, given the above is the case, the screw will most likely break at the point where it restricts these movements and not in cases where there is no ongoing restriction and therefore removal is deemed unnecessary [15].

Given that removal involved further operative intervention, with complication rates of up to 22.4% [13], an argument can be made that this should only be undertaken with evidence to substantiate it. Even without the inherent risks of further intervention, the second operation also adds an economic burden [14].

With this in mind the above data suggests that in the majority of cases there is no indication for the routine removal of syndesmosis screws, from a purely functional point of view. Whilst there are radiological differences, such as diminished tibiofibular clear space, with narrowing in some cases of retained screws [15], this does not correlate to a functional impairment.

With this in mind, this review does not support the routine removal of syndesmosis screws postoperatively. The caveat to this remains patients who remain symptomatic through screw breakage or loosening, but these must be judged on a clinical basis and do not fall under the remit of routine removal.

Conclusion

Whilst controversy exists, this exhaustive and up-to-date analysis of the literature demonstrates there is no significant difference across both arms. When this is compounded with the added burdens, both financial and in terms of complications, there is evidence to suggest that routine removal of syndesmosis screws should not be undertaken and that this should be reserved for symptomatic patients only.

References

- Ogilvie-Harris DJ, Reed SC, Hedman TP. Disruption of the ankle syndesmosis: biomechanical study of the ligamentous restraints. *Arthroscopy : the journal of arthroscopic & related surgery : official publication of the Arthroscopy Association of North America and the International Arthroscopy Association.* 1994; 10: 558-560.
- Dattani R, Patnaik S, Kantak A, Srikanth B, Selvan TP. Injuries to the tibiofibular syndesmosis. *The Journal of bone and joint surgery. British volume.* 2008; 90-B: 405-410.
- Beumer A, Valstar ER, Garling EH, Niesing R, Heijboer RP, Ranstam J, et al. Kinematics before and after reconstruction of the anterior syndesmosis of the ankle. *Acta Orthopaedica.* 2005; 76: 713-720.
- Kukreti S, Faraj A, Miles JNV. Does position of syndesmotic screw affect functional and radiological outcome in ankle fractures?. *Injury.* 2005; 36: 1121-1124.
- Beumer A, Campo MM, Niesing R, Day J, Kleinrensink G, Swierstra BA. Screw fixation of the syndesmosis: a cadaver model comparing stainless steel and titanium screws and three and four cortical fixation. *Injury.* 2005; 36: 60-64.
- Thompson MC, Gesink DS. Biomechanical Comparison of Syndesmosis Fixation with 3.5- and 4.5-millimeter Stainless Steel Screws. *Foot & Ankle International.* 2000; 21: 736-741.
- Hansen M, Le L, Wertheimer S, Meyer E, Haut R. Syndesmosis fixation: analysis of shear stress via axial load on 3.5-mm and 4.5-mm quadricortical syndesmotic screws. *The Journal of foot and ankle surgery : official publication of the American College of Foot and Ankle Surgeons.* 2006; 45: 65-69.
- Xenos JS, Hopkinson WJ, Mulligan ME, Olson EJ, Popovic NA. The tibiofibular syndesmosis. Evaluation of the ligamentous structures, methods of fixation, and radiographic assessment. *The Journal of bone and joint surgery. American volume.* 1995; 77: 847-856.
- Gardner MJ, Demetrakopoulos D, Briggs SM, Helfet DL, Lorich DG. Malreduction of the Tibiofibular Syndesmosis in Ankle Fractures. *Foot & Ankle International.* 2006; 27: 788-792.
- Schwarz N, Köfer E. Postoperative Computed Tomography–Based Control of Syndesmotic Screws. *European Journal of Trauma.* 2005; 31: 266-270.
- PRISMA.
- Wuest TK. Injuries to the Distal Lower Extremity Syndesmosis. *Journal of the American Academy of Orthopaedic Surgeons.* 1997; 5: 172-181.
- Schepers T, Lieshout EMV, Vries MRD, Elst MVD. Complications of Syndesmotic Screw Removal. *Foot & Ankle International.* 2011; 32: 1040-1044.
- Tucker A, Street J, Kealey D, McDonald S, Stevenson M. Functional outcomes following syndesmotic fixation: A comparison of screws retained in situ versus routine removal - Is it really necessary?. *Injury.* 2013; 44: 1880-1884.
- Manjoo A, Sanders DW, Tieszer C, MacLeod MD. Functional and Radiographic Results of Patients with Syndesmotic Screw Fixation: Implications for Screw Removal. *Journal of Orthopaedic Trauma.* 2010; 24: 2-6.